

---

# Facial Soft-Tissue Fillers conference: Assessing the State of the Science

C. William Hanke, MD, Rod J. Rohrich, MD,  
Mariano Busso, MD, Alastair Carruthers, MA, BM, BCh, Jean Carruthers, MD, Steven Fagien, MD,  
Rebecca Fitzgerald, MD, Richard Glogau, MD, Phyllis E. Greenberger, MSW, Z. Paul Lorenc, MD,  
Ellen S. Marmur, MD, Gary D. Monheit, MD, Andrea Pusic, MD, MHS, Mark G. Rubin, MD,  
Berthold Rzany, MD, ScM, Anthony Sclafani, MD, Susan Taylor, MD, Susan Weinkle, MD,  
Michael F. McGuire, MD, David M. Pariser, MD, Laurie A. Casas, MD, Karen J. Collishaw, Roger A. Dailey, MD,  
Stephen C. Duffy, Elizabeth Jan Edgar, MS, Barbara L. Greenan, Kelly Haenlein, MHA,  
Ronald A. Henrichs, CAE, Keith M. Hume, MA, Flora Lum, MD, David R. Nielsen, MD,  
Lisle Poulsen, Lori Shoaf, JD, William Seward, MA, Wendy Smith Begolka, MS,  
Robert G. Stanton, Katherine J. Svedman, CAE, J. Regan Thomas, MD, Jonathan M. Sykes, MD,  
Carol Wargo, MA, and Robert A. Weiss, MD  
*Dallas, Texas, and Carmel, Indiana*

**Summary:** The American Academy of Dermatology and the American Society of Plastic Surgeons, with the support of other sister societies, conducted the Facial Soft-Tissue Fillers: Assessing the State of the Science conference in December of 2009. The American Academy of Dermatology and the American Society of Plastic Surgeons established a panel of leading experts in the field of soft-tissue fillers—from researchers to clinicians—and other stakeholders for the conference to examine and discuss issues of patient safety, efficacy, and effectiveness in relation to the approved and off-label use of soft-tissue fillers, and other factors, including the training and level of experience of individuals administering fillers. This report represents the systematic literature review that examines comprehensively the available evidence and gaps in the evidence related to soft-tissue fillers, to inform and support the work of the state-of-the-science conference panel. This evidence-based medicine review will serve as the foundation for future evidence-based medicine reports in this growing field. (*J Am Acad Dermatol* 2011;64:S66-85.)

In November of 2008, the U.S. Food and Drug Administration's General and Plastic Surgery Panel held a meeting to receive an "update on safety information collected on dermal fillers in the commercial setting, discuss current premarket and postmarket approved study designs, and make recommendations on general issues concerning the

study of various dermal fillers."<sup>1</sup> They are cited in brackets at the end of the article for programmatic reasons only. A complete summary of this meeting is provided.<sup>1</sup>

In response to the rapidly growing use of soft-tissue fillers and the findings of the U.S. Food and Drug Administration panel, the following

---

From the Department of Plastic Surgery, University of Texas Medical Center, and the Department of Dermatology, Saint Vincent Carmel Medical Center, Laser and Skin Surgery Center of Indiana.

Prepared for the American Academy of Dermatology and the American Society of Plastic Surgeons and by The Lewin Group.

Disclosures: Rod J. Rohrich, M.D., declares he is the recipient of research grant funds received by the University of Texas Southwestern Medical Center from Medicis, Contura, Mentor (dermal fillers or botulinum toxin type A studies), and Baxter (fibrin sealant study). C. William Hanke, M.D., declares financial interest as a shareholder in Medicis and Allergan. In addition, he declares having been the recipient of research support from Medicis, Allergan, Merz, Dermik, and Galderma. For additional disclosure information, please see the Disclosure Appendix in this issue.

This supplement in its entirety is jointly published by the *Journal of the American Academy of Dermatology and Plastic and Reconstructive Surgery*.

Citation of the articles in the *JAAD* follows this format: Hanke CW, Rohrich RJ, Busso M, Carruthers A, Carruthers J, Fagien S, et al. Facial Soft-Tissue Fillers: Assessing the State of the Science

---

conference—Proceedings report. *J Am Acad Dermatol* 2011;64 (Suppl):S53-65.

Citation of the articles in *PRS* follows this format: Rohrich RJ, Hanke CW. Facial Soft-Tissue Fillers: Assessing the State-of-the-Science Conference—Proceedings Report. *Plast Reconstr Surg* 2011;127 (Suppl 2):9S-21S.

Received for publication May 25, 2010; accepted November 5, 2010.

Correspondence to: Rod J. Rohrich, M.D., Department of Plastic Surgery, University of Texas Southwestern Medical Center, 1801 Harry Hines Boulevard, Dallas, Texas 75390-9132, E-mail: [rjreditor\\_prs@plasticsurgery.org](mailto:rjreditor_prs@plasticsurgery.org) or C. William Hanke, M.D., Department of Dermatology, Saint Vincent Carmel Medical Center, Laser & Skin Surgery Center of Indiana, 13400 North Meridian Street, Suite 290, Carmel, Ind. 46032 E-mail: [cwmhanke@thelassi.com](mailto:cwmhanke@thelassi.com).

0190-9622/\$36.00

© 2011 by the American Academy of Dermatology, Inc and Copyright © 2011 by the American Society of Plastic Surgeons. doi:10.1016/j.jaad.2011.02.009

**Table I.** PubMed literature search strategy

Concept	Search string		Hits
General terms for dermal fillers	"dermal filler*" [tiab] OR "soft tissue filler*" [tiab] OR "soft-tissue filler*" [tiab] OR "injectable filler*" [tiab] OR "wrinkle filler*" [tiab] OR "skin filler*" [tiab] OR "facial filler*" [tiab] OR "collagen* filler*" OR ("cosmetic techniques" [MH] OR "rejuvenation" [MH]) AND ("collagen" [MH] OR "hyaluronic acid" [MH] OR "lactic acid" [MH] OR "durapatite" [MH] OR "polymethyl methacrylate" [MH] OR "silicone oils" [MH])	OR	AND 621
Collagen fillers	"cosmoderm" OR "cosmoplast" OR "cymetra" OR "fascian" OR "zyderm" OR "zyplast" OR "glutaraldehyde-cross-linked collagen" OR "evolence"		
Hyaluronic acid fillers	"juvederm" OR "perlane" OR "restylane" OR hylan-B gel [Substance Name] OR "hylaform" OR "puragen" OR "captique"		
Poly-L-lactic acid fillers	"sculptra" OR "new-fill" [Substance Name]		
Calcium hydroxylapatite fillers	"radiesse"		
Polymethyl methacrylate fillers	"artefill"		
Limits	(humans[MH] AND English[lang] NOT (editorial[pt] OR letter[pt] OR comment[pt]) NOT (review[pt] NOT (review[pt] AND (systematic[tiab] OR comprehensive[tiab] OR method*[tiab] OR medline*[tiab] OR pubmed*[tiab])))		

The asterisk (\*) is a "truncation symbol" or "wildcard," which means that any characters that come after it are retrieved, including those with no other characters. The quotation marks (" ") mean that the search looked for the words as a phrase. The [tiab] means the search looked for the indicated term in the title or abstract. A search term with the [MH] after the term does not have the asterisk because it is a set MeSH thesaurus term and will not have any variations.

groups convened the Facial Soft-Tissue Fillers: Assessing the State of the Science conference on December 6 through 7, 2009, in Washington, D.C.:

- American Academy of Dermatology (sponsor society)
- American Academy of Facial Plastic and Reconstructive Surgery (supporting society)
- American Academy of Ophthalmology (supporting society)
- American Academy of Otolaryngology—Head and Neck Surgery (supporting society)
- American Society for Aesthetic Plastic Surgeons (supporting society)
- American Society for Dermatologic Surgery (supporting society)
- American Society of Plastic Surgeons (sponsor society)

Please see the companion article that summarizes the conference proceedings. The purpose of this systematic literature review is to examine comprehensively and assess the available evidence and gaps in the evidence related to soft-tissue fillers to inform and support the work of the state-of-the-science conference panel.

## METHODOLOGY

### Search strategy

A comprehensive search strategy was developed to search PubMed, which includes access to MEDLINE, and citations for selected articles in life science journals not included in MEDLINE. The search strategy was designed to ensure broad capture of all relevant articles. Search strings using MeSH (Medical Subject Headings, PubMed's controlled vocabulary for indexing studies) terms and key text terms were combined to produce the resulting search strategy. Varied constructs of search terms were captured with the use of truncation (represented by an asterisk). Additional parameters were also applied to the search strategy, including limiting retrieval to articles with abstracts in English, and focused on humans. Using the date limit function within PubMed, we limited our search to studies published since January 1, 1994. We also used a limit function in PubMed to exclude letters, editorials, and commentaries. Table I lists the search terms and parameters we applied. This search yielded a total of 621 abstracts.

We conducted a title and abstract review of these studies, applying inclusion/exclusion criteria

**Table II.** Inclusion/exclusion criteria for abstract/title review

Included study types
Meta-analysis
Systematic review
Clinical trial
Randomized controlled trial
Controlled clinical trial
Uncontrolled clinical trial
Epidemiologic study
Cohort study
Case-control study
Cross-sectional study
Follow-up study
Evaluation study
Case report/series
Excluded study types*
Nonsystematic reviews
Guidelines
Included treatment types
Soft-tissue fillers, including the following:
Collagen
Hyaluronic acid
Poly-L-lactic acid
Calcium hydroxylapatite
Polymethylmethacrylate
Silicone oil fillers
Polyacrylamide gels
Excluded treatment types
Botulinum toxin
Polymers and collagen-related implants
Dermal stimulators

\*Particularly informative reviews and guidelines were retained to inform the background section.

developed in collaboration with the Steering Committee and based on study type and treatment type. These inclusion/exclusion criteria are presented in Table II. The review of title and abstracts yielded a total of 213 potentially relevant studies. Full-text articles for these studies were ordered and carefully reviewed, and a precise classification of each of the articles was performed. After the full-text review, a total of 198 unique, relevant studies were identified for inclusion in this review.

Although case reports and small case series studies are not typically included in an evidence review, we reviewed these study types for this report based on the assumption that there is little information on adverse events associated with use of soft-tissue fillers in general. Case reports and case series, though methodologically limited, are important sources of adverse event data, which are of high priority for evaluating soft-tissue fillers. Table III summarizes the distribution of the articles identified by study design and soft-tissue filler type.

**Table III.** Full-text studies by type of study and type of soft-tissue filler

Type of study	Collagen	HA	PLLA	CaHA	PMMA	Other	Total*
SR	0	1	1	0	0	2	4
RCT	13	25	2	3	2	1	33
CCT	2	0	0	0	0	0	2
UCT	1	13	4	15	0	8	41
Cohort	1	4	7	2	1	4	18
Cross-sectional	0	1	0	1	0	1	3
Case series	17	39	19	11	10	20	97
Total	34	83	33	32	13	36	198

HA, Hyaluronic acid; PLLA, poly-L-lactic acid; CaHA, calcium hydroxylapatite; PMMA, polymethylmethacrylate; SR, systematic review; RCT, randomized controlled trial; CCT, controlled clinical trial; UCT, uncontrolled clinical trial.

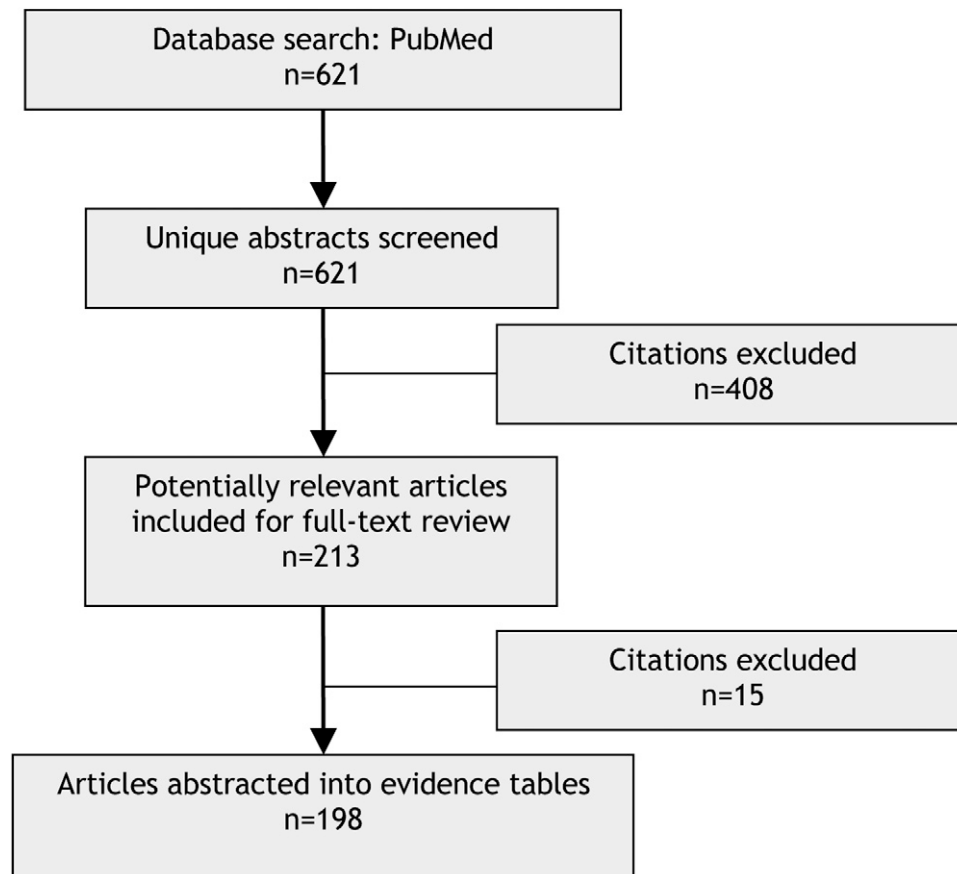
\*Citations pertaining to more than one soft-tissue filler type within a study are counted for soft-tissue filler, but only once for the "Totals" column.

### Data abstraction and grading

To capture information from the included studies, data abstraction forms were developed in a Microsoft Access (Microsoft Corp., Redmond, Wash.) database. Trained abstractors reviewed full-text versions of each in-scope study and recorded key study data using the forms, including basic information about the study (e.g., year of publication), patient population, intervention, outcomes measured, results, and adverse events. Drawing from the data abstracted in the forms, the Access database was used to create evidence tables by soft-tissue filler type. Studies addressing more than one soft-tissue filler type are counted for each type, as relevant. Evidence tables for all included studies can be found in Appendix A (available at <http://www.eblue.org>). Figure 1 outlines the phases of the literature review process and the number of studies excluded at each stage.

In addition to abstraction of relevant data from each study, studies were assessed for their quality. Assessing the quality of individual studies helps to determine and characterize the overall strength of a body of evidence for a given research question or topic. To provide a quality grade or rating to each study, we adapted quality assessment methods used by the Agency for Healthcare Research and Quality Effective Health Care Program, which essentially involves three stages: (1) classify the study design; (2) apply predefined criteria for quality and critical appraisal; and (3) arrive at a summary judgment of the study's quality.<sup>2</sup>

After classifying the study designs and abstracting relevant data from the 198 included studies, we applied 11 predetermined criteria, which we adapted from the Agency for Healthcare Research and



**Fig 1.** Literature review flow diagram.

Quality *Methods Reference Guide*, to form a judgment about the validity of each study's results. [Table IV](#) presents these criteria.

Although some of these criteria are straightforward, others require consideration of the specific characteristics of each soft-tissue filler being examined in a study. For example, the selection, measurement, and clinical relevance of the outcomes and the appropriateness of the timing of follow-up in a given study were evaluated with respect to the characteristics and expected duration of the soft-tissue filler(s) being studied.

Similar to the process used by the Effective Health Care Program, we assigned a summary grading of "good," "fair," or "poor," to rate the overall quality of a study, where the rating of "good" was given to a study meeting all of the above criteria. Using this method, by default, only formal randomized controlled trials could receive a grade of "good." However, randomized controlled trials could also be downgraded to "fair" or "poor" if they did not meet all of the criteria. The highest rating attainable by observational (nonexperimental retrospective or prospective) studies was "fair." Case series/single case reports were all rated "poor."

## **SUMMARY OF THE EVIDENCE**

### **Short- and long-term safety, efficacy, and effectiveness**

All 198 studies (including 97 case series/reports) that we identified in our search investigated and/or reported on the safety (e.g., occurrence of adverse events), efficacy, or effectiveness of soft-tissue fillers, including 33 studies that were randomized controlled trials. The findings from these studies are organized below by soft-tissue filler and, within each section, are presented by the site of injection. Hyaluronic acid fillers were most often investigated, and nasolabial folds were the most commonly injected areas.

#### **Hyaluronic acid fillers**

Our search returned 83 studies evaluating the efficacy and/or safety of hyaluronic acid fillers, including 25 randomized controlled trials, 13 uncontrolled clinical trials, four cohort studies, one cross-sectional study, and one systematic review. In addition, we identified 39 case series/reports that discussed adverse events in patients treated with hyaluronic acid fillers. The various hyaluronic acid fillers that were investigated in the literature, and the

**Table IV.** Evidence grading criteria

RCT (i.e., comparative study design with least risk of bias)
Clear description of the following:
Population
Setting of care
Interventions
Comparison groups
Outcomes
Duration/timing of follow-up
Statistical/analytical methods
No obvious reporting errors
Low dropout rate
Clear reporting of dropouts

RCT, Randomized controlled trial.

number of randomized controlled trials and other study designs (excluding case reports and case series) we identified per hyaluronic acid filler, are listed in Table V. Restylane appeared most often in the relevant studies that were captured. Follow-up periods ranged from 3 to 12 months, with fewer than half of the studies (43 percent) conducting follow-up past 6 months.

Of the 25 randomized controlled trials that examined the hyaluronic acid fillers, 20 assessed the use of a hyaluronic acid filler injected exclusively into the nasolabial fold area. The remaining clinical trials and other study designs examined injection at other sites, including lips, glabellar lines, marionette lines, arm, hand, cheek, chin, and/or unspecified sites. The following sections describe relevant studies by the site of injection.

**Nasolabial folds.** The majority of the studies focused on hyaluronic acid treatment in the nasolabial folds were randomized controlled trials (n = 20) and compared the use of a hyaluronic acid filler with another filler. Of these, hyaluronic acid was compared with collagen (seven studies) and calcium hydroxylapatite (two studies), whereas 11 studies compared two hyaluronic acid fillers. Of the 11 studies comparing two hyaluronic acid fillers, comparisons were conducted in a variety of ways: one hyaluronic acid filler versus another hyaluronic acid filler (seven studies), one concentration of a hyaluronic acid filler versus a different concentration of the same filler (one study), the same hyaluronic acid filler with and without the incorporation of lidocaine (two studies), and the same hyaluronic acid filler while the time point at which subjects received retreatment was varied (one study). In addition to these randomized controlled trials, three uncontrolled clinical trials examined hyaluronic acid use for nasolabial fold exclusively.

In general, among the seven randomized controlled trials comparing hyaluronic acid with

**Table V.** Distribution of reported commercial hyaluronic acid fillers by study design

HA filler	RCTs	Other study designs
Restylane	15	12
Juvéderm	12	1
Hylaform	5	0
Perlane	4	2
Captique	2	0
Puragen	2	0
Teosyal	0	1

HA, Hyaluronic acid; RCTs, randomized controlled trials.

collagen, hyaluronic acid was equal or superior to collagen in correcting nasolabial folds, and the adverse events tended to occur early, were minor, and resolved soon after injection. Two of these randomized controlled trials compared the hyaluronic acid filler Juvéderm (Allergan, Inc., Irvine, Calif.) to the bovine collagen filler Zyplast (Inamed Corp., Santa Barbara, Calif.). In one of these studies, a double-masked randomized controlled trial conducted in the United States (n = 439), subjects were randomized to receive one of three smooth-gel Juvéderm fillers (Juvéderm 30, Juvéderm Ultra, and Juvéderm Ultra Plus) intradermally to the nasolabial fold on one side of the face. Each subject then received cross-linked Zyplast in the nasolabial fold on the other side of the face. In comparison to Zyplast, the study found that the three Juvéderm soft-tissue fillers provided a longer lasting correction, measured by the mean level of improvement in nasolabial fold severity using the five-point Wrinkle Assessment Scale. At 24 weeks, the mean level of improvement (i.e., a reduction in points using the Wrinkle Assessment Scale) from baseline was greater than or equal to one point with the Juvéderm fillers and less than or equal to a half point with the Zyplast comparison. The trial also found that all fillers were similarly well tolerated by patients.<sup>3</sup>

Similarly, in a double-blind, within-subject, randomized controlled trial (n = 87) comparing Juvéderm Ultra Plus treatment with Zyplast, the mean correction after treatment (using the static, validated Wrinkle Assessment Scale) was comparable for both products. However, over the 24-week follow-up period, scores for Zyplast nearly returned to baseline, whereas the Juvéderm Ultra Plus scores marking improvement remained. Subjects were allowed to receive a repeated treatment with the hyaluronic acid filler at the 24-week follow-up visit. The study found that 88 percent of the severe nasolabial folds treated still had clinically significant correction at 1 year after retreatment, which required a significantly lower injection volume (0.6 ml

compared with 1.7 ml). Occurrence of treatment-site adverse reactions was similar for both soft-tissue fillers investigated in this study. The majority of the individual reactions reported lasted no more than 7 days, were mild or moderate in severity, and required no further intervention. Examples included erythema, induration, pain, edema, nodules, bruising, pruritus, and discoloration.<sup>4</sup>

Another two randomized controlled trials compared the hyaluronic acid filler Restylane (Q-Med Esthetics, Uppsala, Sweden) with a collagen filler. One of these randomized controlled trials, a double-blind, within-subject, randomized controlled trial (n = 138) conducted in 2003 compared Restylane with Zyplast, with outcomes assessed at 2, 4, and 6 months after injection into contralateral nasolabial folds. The study concluded that Restylane provided more durable aesthetic improvement than collagen, as indicated by Wrinkle Severity Rating Scale (p < 0.0001) and Global Aesthetic Improvement Scale (p < 0.0001) evaluation. The study noted that the frequency, intensity, and duration of local injection-site reactions were similar for the two filler types. Furthermore, the study found that mild or moderate delayed-onset reactions (defined by the study as reaction occurring 14 days or more after treatment) occurred in 12 patients and with equal frequency at hyaluronic acid- and collagen-treated sites. Of these reactions, redness was the most common, and all were mild or moderate in intensity and resolved within 2 to 3 months without treatment.<sup>5</sup>

A multicenter, within-subject, randomized controlled trial (n = 149) conducted in 2007 compared treatment with Restylane and porcine collagen-derived Dermicol-P35 (Evolence; ColBar LifeScience Ltd., Herzliya, Israel). Based on a 6-month follow-up evaluation and Modified Fitzpatrick Wrinkle Scale assessments, 97.3 percent of subjects injected with Evolence saw a half-point improvement in their Modified Fitzpatrick Wrinkle Scale assessment, compared with 98 percent of subjects injected with Restylane. The study concluded that the effectiveness of Evolence is maintained for at least 6 months and is equivalent to hyaluronic acid for the correction of nasolabial folds. The majority of injection-site reactions were of 4 days' duration or less, with almost all resolving within 1 week. Erythema was the most commonly reported reaction.<sup>6</sup>

The two studies comparing hyaluronic acid and calcium hydroxylapatite, also known as Radiesse (BioForm Medical, Inc., San Mateo, Calif.), were multicenter, blinded, split-face, randomized controlled trials conducted in Europe by the same investigators, and determined that calcium hydroxylapatite was superior to hyaluronic acid fillers in the

treatment of nasolabial folds. One of these studies (n = 205) compared three hyaluronic acid fillers [Juvéderm 24, Juvéderm 24HV, and Perlane (Q-Med Esthetics)] with calcium hydroxylapatite, with outcomes assessed at 4, 8, and 12 months. Investigator analysis using the Global Aesthetic Improvement Scale found that calcium hydroxylapatite showed the largest number of nasolabial folds rated "improved" or better. This was statistically significant compared with all hyaluronic acid fillers and all time points except one (at 12 months compared with Juvéderm 24HV, p ≤ 0.05), and led the authors to conclude that the calcium hydroxylapatite was more effective and longer lasting than each hyaluronic acid filler in maintaining nasolabial fold augmentation. With respect to safety, no serious adverse events requiring intervention were required at any time points for any of the injected materials.<sup>7</sup> The other study (n = 60) by the same investigators compared Restylane and calcium hydroxylapatite with outcomes assessed at 6, 9, and 12 months. Calcium hydroxylapatite was found to be significantly more effective than hyaluronic acid, showing greater improvement and longer lasting effects, as evidenced by blinded evaluator Wrinkle Severity Rating Scale ratings that showed a mean improvement at 12 months of 0.41 for calcium hydroxylapatite and 0.14 for hyaluronic acid (p = 0.007). Both products were well tolerated, and no serious adverse events were reported with either treatment. Only four adverse events (two hematomas, one nodule, and one extrusion) were reported in 118 folds injected two times each during the course of treatment and were resolved without complications.<sup>8</sup>

The majority of randomized controlled trials that examined the use of hyaluronic acid fillers for nasolabial folds (n = 11 studies) compared two different hyaluronic acid fillers. For example, a double-blind, randomized controlled trial (n = 150) conducted in Canada in 2005 compared treatment with Perlane and Hylaform (Inamed), with each patient receiving contralateral injections of each filler into the mid or deep dermis nasolabial folds. The study found that Perlane provides a superior improvement compared with Hylaform, as indicated by Wrinkle Severity Rating Scale and Global Aesthetic Improvement Scale assessments at 6 months showing greater and longer lasting improvement. Using the Wrinkle Severity Rating Scale, 75 percent of patients receiving Perlane treatment had a greater than one grade improvement at 6 months, and evaluators rated 64 percent of patients' corrections superior to those achieved with Hylaform. For patients treated with Hylaform, 38 percent had a greater than one grade improvement in Wrinkle

Severity Rating Scale score, and evaluators rated 8 percent as superior. Adverse events occurred more frequently with use of Perlane than with Hylaform (41.3 percent compared with 21.3 percent) but were limited to common reactions such as swelling, pain, and redness, and the study concluded that this was an acceptable tolerability profile.<sup>9</sup>

A more recent randomized controlled trial, conducted in 2009 (n = 84), compared the newer hyaluronic acid filler Puragen (Mentor Corp., Santa Barbara, Calif.) and Captique (Inamed), and carried out follow-up evaluations at 2, 4, and 6 months. Using the Wrinkle Severity Rating Scale, Puragen was assessed to be superior to Captique at all follow-up time points ( $p < 0.05$ ). At 6 months after baseline, Puragen was superior to Captique in 60.4 percent of cases, and Captique proved superior to Puragen in 5.8 percent of cases ( $p < 0.05$ ). In terms of the Global Aesthetic Improvement Scale evaluation, Puragen was also rated significantly higher compared with Captique at all follow-up time points ( $p < 0.05$ ). At 6 months after baseline, Puragen was superior to Captique in 75 percent of patients, and Captique was superior to Puragen in 5.8 percent ( $p < 0.05$ ). Efficacy assessments by patients gave results equivalent to those of the investigator. During the follow-up period, adverse reactions were observed exclusively at the injection site in 14.7 percent of Puragen patients and 11.8 percent of Captique patients. Furthermore, delayed-onset complications (defined in the study as arising 14 days after the last treatment) had a similar incidence between the two products and subsided spontaneously within 2 months after treatment. The study concluded that both products are equally effective and safe in eliminating nasolabial folds, although treatment with Puragen obtained more long-lasting and stable results in subjects.<sup>10</sup>

Among the three uncontrolled clinical trials assessing the use of hyaluronic acid fillers for nasolabial folds, we identified a study (n = 18) conducted in Canada that focused on the use of Perlane to treat nasolabial folds in human immunodeficiency virus-positive men with facial lipoatrophy. Facial assessment was conducted at 1 and 12 months using photographic evaluation on a seven-point Likert scale. During the study, patients did not regress to their preinjection levels of lipoatrophy. At the 12-month interval, there was still a slight significant difference in facial assessment from the preinjection scores ( $p = 0.0466$ ). Furthermore, no significant difference in Likert scale grade was shown between the 1- and 12-month photographs ( $p = 0.3693$ ), indicating that the patients did not regress to their preinjection levels of lipoatrophy. The investigators

concluded that Perlane is a feasible option for correction of facial lipoatrophy, and the procedure was well tolerated without any long-term adverse events observed.<sup>11</sup>

**Other sites.** From our review, a total of 17 studies investigated hyaluronic acid filler injection at specific sites other than or in combination with nasolabial folds, including three randomized controlled trials, 12 uncontrolled clinical trials, and two cohort studies. Restylane was used as a hyaluronic acid filler for treatment in all of the studies described below by respective injection site.

For example, a prospective, blinded, randomized controlled trial (n = 283) conducted in 2008 in the United States compared the use of two hyaluronic acid fillers, Restylane and Perlane, for midface volume correction of nasolabial folds and marionette lines. Injection occurred at a total of 1021 sites across the patient population, and touch-up injections were discouraged to parallel clinical practice. Patients were followed for 12 weeks for adverse events only. A total of 336 local injection-related events were reported at 12 weeks, including bruising, tenderness, edema, and pain. Furthermore, the incidence of local adverse events was higher at 72 hours after injection compared with 2 weeks. The preliminary logistic regression demonstrated that injection technique variables strongly influenced the rate of local adverse events, including injection type, fanlike injection technique, injection volume, and correction time. It was also determined that other variables, such as the product injected, injection site, and injection depth were not found to be correlated with the rate of local adverse events. The authors concluded that local adverse events following injection with the hyaluronic acid gel fillers used were related to investigator technique and not intrinsic differences between the hyaluronic acid filler properties, which suggested that moderating the rate of injection of hyaluronic acid fillers may lessen the onset of local adverse events.<sup>12</sup>

Two much smaller randomized controlled trials compared Restylane to another hyaluronic acid filler but at different sites of injection and with different results. One randomized controlled trial (n = 10) conducted in Japan compared Restylane and Puragen in the treatment of glabellar lines. Evaluator-blinded assessments at 12 months determined that Puragen was considered superior in 70 percent of patients and Restylane was considered superior in 10 percent of patients, although no difference was seen in the remaining 20 percent. Adverse events were not reported, and the study concluded that both Restylane and Puragen are effective in producing an optimal cosmetic result,

whereas Puragen provides a more durable aesthetic improvement in the treatment of glabellar lines.<sup>13</sup>

Restylane was compared with the collagen filler Cosmoplast (Inamed) for the treatment of female patients experiencing dermal thinning of the dorsal hands in a double-blind, within-subject, randomized controlled trial (n = 10) conducted in 2008 in Canada. Follow-up assessment was conducted at 6 months by two blinded physicians using a scale of 1 to 5 to rate the general clearance of rhytides, veins, bony prominence, and dermal and subcutaneous atrophy. In addition, patients assessed tolerability and satisfaction on scales ranging from 1 to 5, and the resulting scores indicated that Restylane was superior to collagen regarding duration and administration. Reported adverse events included pain, tingling, and bruising, and one patient experienced nodule formation at the collagen injection site, which resolved itself by the 6-month follow-up.<sup>14</sup>

Restylane was also studied in an uncontrolled clinical trial (n = 154), conducted in 2005 in Canada, to treat the lips of women with prominent downturned mouth corners. Evaluation was conducted by the treating investigator at 3, 4.5, and 6 months, using a set of standardized criteria indicating the amount of improvement obtained by the patient (i.e., none, slight, moderate, or superb). Evaluation at 4.5 months showed that 60 percent of subjects had a moderate or slight improvement and that, at 6 months, 50 percent retained a slight improvement, whereas the remaining 50 percent returned to baseline. Adverse events such as pain, redness, swelling, lumping, superficial aggregate of material, and canker sore were reported following injection but were expected and transient. Three subjects reported postinjection herpes labialis that was treated for 7 days. The investigators concluded that hyaluronic acid injection to improve age-related changes in the lateral lip corners was effective, safe, and well tolerated in this small prospective study. It was also noted that the persistence of correction at 3, 4.5, and in some cases up to 6 months was longer than they had experienced with other temporary biodegradable soft-tissue fillers.<sup>15</sup>

In another, smaller uncontrolled clinical trial (n = 60), patients seeking chin and/or cheek augmentation were treated with Restylane SubQ. Injections were performed in 98 cheeks and 16 chins, with 12 patients receiving touch-up injections at 20 sites (cheek, n = 13; chin, n = 7). Follow-up was carried out at 1, 3, 6, 9, and 12 months using Global Aesthetic Improvement Scale assessment performed by patients and investigators. Patients reported an aesthetic improvement (i.e., somewhat, moderately,

or very much improved) at the treatment site(s) in 91 percent of cases at 6 months and 58 percent of cases at 12 months. Investigators considered treatment to be effective in 96 percent of cases at 6 months and 52 percent of cases at 12 months. Reported adverse events occurred in 58 percent of patients and were treatment-related at the injection site, including swelling, tenderness, redness, bruising, pain, and pruritus. The majority of adverse events (70 percent) occurred on the day of treatment or on the following day. Skin induration was frequently a delayed-onset adverse event and persisted for 4 months on average. The study concluded that Restylane is well tolerated and provides relatively long-lasting aesthetic correction of the cheeks and chin.<sup>16</sup>

Among the cohort studies that examined hyaluronic acid filler use in other injection sites, a more recent prospective, open noncomparative study (n = 16) investigated treatment of mild to moderate brachial ptosis in women. Subjects were treated with Restylane Vital in the arm with three sessions at 30-day intervals. Statistically significant increases at 90 days were measured for skin hydration, thickness, and gross elasticity, indicating that hyaluronic acid treatment can improve the biophysical properties and appearance of the skin. No unexpected or serious adverse events were reported, and all expected treatment-related adverse events including discomfort at the injection site, bruising, and hematoma were of mild intensity.<sup>17</sup>

### Collagen fillers

Our search returned 34 studies evaluating the efficacy and/or safety of collagen fillers, including 13 randomized controlled trials, two controlled clinical trials, one uncontrolled clinical trial, one cohort study, and 17 case series/reports. Among the 17 studies (excluding case series/reports), nine randomized controlled trials assessed the use of collagen injected exclusively into the nasolabial fold area, and the one cohort study assessed its use in the nasolabial fold and other facial wrinkles, including radial upper lip lines and marionette lines. The remaining seven studies examined the use of collagen in other sites, including the postauricular area (three studies), lip (two studies), arm (one study), and hand (one study). Studies are described by the site of injection below.

**Nasolabial fold and other wrinkles.** All 10 studies (nine randomized controlled trials) on collagen treatments in the nasolabial fold and other facial wrinkles compared the use of a collagen filler with another filler. The majority of these studies compared collagen with another type of filler, including



hyaluronic acid fillers (six studies), polymethylmethacrylate (two studies), and calcium hydroxylapatite (one study), whereas one study compared two different collagen fillers.

The majority of studies comparing collagen with hyaluronic acid fillers determined that hyaluronic acid fillers were superior to collagen in correcting wrinkles. For example, two randomized controlled trials described previously demonstrated that Juvéderm produced better results than Zyplast as measured by the nasolabial fold severity score.<sup>3</sup> One of these randomized controlled trials (n = 138) concluded that Restylane demonstrated significant superiority compared with collagen at 2, 4, and 6 months after treatment, as indicated by assessments using the Wrinkle Severity Rating Scale (p < 0.0001) and the Global Aesthetic Improvement Scale (p < 0.0001). The study noted that the frequency, intensity, and duration of local injection-site reactions were similar for the two types of fillers. In addition, the study found that mild or moderate delayed-onset reactions (defined by the study as reactions occurring 14 days or more after treatment) occurred in 12 patients with equal frequency at hyaluronic acid- and collagen-treated sites. Of these reactions, redness was the most common, and all were mild or moderate in intensity and resolved within 2 to 3 months without treatment.<sup>5</sup>

The three studies that compared a collagen filler to polymethylmethacrylate were related studies that investigated polymethylmethacrylate (Artefill; Artes Medical, Inc., San Diego, Calif.), using Zyderm II (Inamed) or Zyplast as a control, to compare the cosmetic correction of nasolabial folds as a result of using each filler and to explore the safety of polymethylmethacrylate.<sup>18-20</sup> These studies are described later in the section on polymethylmethacrylate.

Of the remaining studies that examined collagen treatment of nasolabial folds and other wrinkles, one randomized controlled trial (n = 117) enrolled subjects with moderate to deep nasolabial folds who were randomized to receive calcium hydroxylapatite on the nasolabial fold on one side of the face and human collagen (Cosmoplast) on the other side. The study found that 79 percent of subjects had superior improvement at the calcium hydroxylapatite-injected site through 6 months (p < 0.0001). The study reported that adverse event rates were comparable for both treatments; however, there was some increase in bruising and edema at the calcium hydroxylapatite-injected site. Adverse event duration was similar for both treatments and resolved within 14 to 21 days.<sup>21</sup>

The remaining randomized controlled trial (n = 12) compared the efficacy and safety of

Evolve30, a porcine-derived collagen gel based on Glymatrix (ColBar LifeScience) cross-linking technology, with Zyplast, a bovine cross-linked collagen. Assessed using the Modified Fitzpatrick Wrinkle Scale, the two fillers initially improved wrinkle severity of the nasolabial fold to a similar extent; however, after an average follow-up of 18 months, Evolve30 demonstrated superior results in nine subjects (p = 0.022). No treatment-related adverse events were reported, although transient erythema was observed in both treated sides.<sup>22</sup>

**Lip.** We identified two studies that investigated the use of collagen fillers in the lip, including one randomized controlled trial and one cohort study. The randomized controlled trial (n = 44) randomly assigned patients with age-related changes in the size and contour of the upper lip to Zyplast or an injectable acellular dermal graft (Cymetra; LifeCell Corp., Branchburg, N.J.). Using a number of measurements, it was concluded that Cymetra-treated patients experienced a greater increase in upper lip bulk, vermilion, and lower lip projection. All patients in the study tolerated treatment well, without any significant local or systemic complications.<sup>23</sup> A retrospective cohort study examined the safety and efficacy of Dermicol-P35 30G (Evolve) in subjects who received the injection to restore the contour of the upper and/or lower lip. Scores measuring investigator assessment, investigator satisfaction, and patient satisfaction indicated that Dermicol-P35 30G produced favorable lip enhancement results. At the 10-month follow-up, 95 percent of patients experienced no swelling, 100 percent experienced no bruising, 100 percent experienced no pain associated with treatment, and 85 percent experience no lumpiness. When present, lumpiness was assessed to be very slight or well defined, as opposed to the more serious assessments of moderate or severe.<sup>24</sup>

**Other sites.** Three studies by Sclafani et al. examined the use of collagen in the postauricular area, including one randomized controlled trial and two controlled clinical trials. The randomized controlled trial (n = 10) evaluated the clinical persistence and histologic appearance of intradermal Zyplast with a subdermally implanted acellular dermal graft (AlloDerm; LifeCell). Digital photographs of the implant sites were taken at 1-, 3-, 6-, 9-, and 12-month follow-up visits for assessing the volume of the sites. The study found that Zyplast was progressively absorbed and lost complete clinical effect by 6 months. In contrast, the apparent volume at the site of the AlloDerm sheets decreased during the first 6 months and then stabilized over the next 6 months.<sup>25</sup> One of the controlled clinical trials (n = 5) compared

Zyplast to an autologous collagen dispersion (autologous Please provide name and city/state location of manufacturer of Autologen, per Journal style for use of brand names.), whereas the other (n = 20) compared Zyplast to a homologous collagen dispersion (Dermalogen; Collagen Matrix Technologies, Inc., Beverly, Mass.). Both studies concluded that the respective collagen dispersion was a viable alternative to Zyplast based on clinical observations and histologic findings.<sup>26,27</sup>

An uncontrolled clinical trial (n = 530), conducted in the United States, also focused on the use of Evolence. In this study, the potential of Evolence to elicit allergic reactions was examined. Enrolled subjects received an intradermal injection of Evolence in the left forearm and a second injection in the right forearm after 2 weeks. Injection sites were assessed clinically at 30 minutes and 72 hours after each injection and at 30 days after the second injection. Serum anticollagen antibody analyses were also performed before treatment and at the end of the study. After treatment, no significant erythematous reactions of positive hypersensitivity were observed in subjects. In addition, most subjects did not display antibodies against porcine type 1 collagen, and those who did showed no change in antibody levels during the study, indicating that the injection of the filler did not result in an immune response by the body. The investigators concluded that the Evolence implant appears to have a low potential for hypersensitivity, and as a result, intradermal skin testing before its use seems to be unnecessary.

As described previously, the injection of the hyaluronic acid filler Restylane was compared with the collagen filler Cosmoplast for the treatment of female patients experiencing dermal thinning of the dorsal hands in a small randomized controlled trial (n = 10) conducted in Canada. Follow-up assessment was conducted at 6 months by two blinded physicians using a scale of 1 to 5 to rate the general clearance of rhytides, veins, bony prominence, and dermal and subcutaneous atrophy. In addition, patients assessed tolerability and satisfaction on scales ranging from 1 to 5, and the resulting scores indicated that hyaluronic acid was superior to collagen regarding duration and administration. Reported adverse events included pain, tingling, and bruising, and one patient experienced a nodule formation at the collagen injection site, which resolved itself by the 6-month follow-up.<sup>14</sup>

### Calcium hydroxylapatite

Our search identified 32 studies on the use of calcium hydroxylapatite (Radiesse), including three randomized controlled trials, 15 uncontrolled clinical

trials, two cohort studies, one cross-sectional study, and 11 case series/reports. The most frequently studied site across these studies was the nasolabial folds, followed by the cheeks.

**Nasolabial folds and other facial wrinkles.** The three randomized controlled trials that examined the use of calcium hydroxylapatite were all conducted in patients with moderate to severe nasolabial folds. The largest randomized controlled trial (n = 205) treated patients with either calcium hydroxylapatite or one of three hyaluronic acid fillers (Juvederm 24, Juvederm 24HV, or Perlane) for the correction of nasolabial folds. The study evaluated efficacy outcomes using Global Aesthetic Improvement Scale and Wrinkle Severity Rating Scale scores and patient satisfaction using a survey. At 8 months, Global Aesthetic Improvement Scale scores indicated that significantly more calcium hydroxylapatite-treated nasolabial folds were improved compared with the hyaluronic acid-treated nasolabial folds. Mean change in Wrinkle Severity Rating Scale scores from baseline, however, showed no statistically significant difference between the products. Calcium hydroxylapatite was rated the highest on all four yes/no survey questions on patient satisfaction. No serious adverse events were reported at any time during the study.<sup>7</sup> Another randomized controlled trial (n = 60) compared the use of calcium hydroxylapatite with Restylane and found that at 6-, 9-, and 12-month follow-up, calcium hydroxylapatite was significantly more effective than hyaluronic acid in correcting nasolabial folds based on blinded Global Aesthetic Improvement Scale and Wrinkle Severity Rating Scale ratings. Both products were considered safe and well tolerated.<sup>8</sup> The third randomized controlled trial (n = 117) compared calcium hydroxylapatite with human-based collagen (Cosmoplast) for 6 months. An evaluation of subject photographs by blinded experts indicated that calcium hydroxylapatite achieved superior improvement compared with collagen (p < 0.0001). Adverse event rates for both treatments were comparable, with some increase in bruising and edema at calcium hydroxylapatite-treated sites.<sup>21</sup>

In addition to the three randomized controlled trials, 10 other studies assessed the use of calcium hydroxylapatite for the correction of nasolabial folds, including eight uncontrolled clinical trials, one cohort study, and one cross-sectional study. Overall, these studies indicated that calcium hydroxylapatite was effective and well tolerated in patients for treating nasolabial folds. For example, the cohort study (n = 1000), which followed patients for 52 months, found that calcium hydroxylapatite

performed well and resulted in a favorable safety profile, high patient satisfaction, and good durability.<sup>28</sup> A recently published uncontrolled clinical trial (n = 100) assessed 6-month safety results of calcium hydroxylapatite for the treatment of nasolabial folds in Fitzpatrick skin types IV to VI. Results from this study indicated that study subjects with dark skin injected subdermally with calcium hydroxylapatite did not show signs of keloid formation, hypertrophic scarring, hyperpigmentation or hypopigmentation, or other clinically significant adverse events.<sup>29</sup>

Although most of the calcium hydroxylapatite studies examined patient outcomes, one clinical trial (n = 58) used radiography and computed tomographic scans to assess whether calcium hydroxylapatite poses radiographic safety concerns. The study determined that calcium hydroxylapatite is usually visible and does not obscure underlying structures on computed tomographic scans. In addition, the study found no evidence that calcium hydroxylapatite migrates or that osteogenesis results from the calcium hydroxylapatite being placed in the deep dermis and subcutaneous plane.<sup>30</sup>

**Cheeks.** We identified five uncontrolled clinical trials that examined the effect of calcium hydroxylapatite in the cheek area, all of which reported improved cosmetic outcomes and minimal adverse events. One of these studies (n = 100) was conducted in patients with human immunodeficiency virus–associated lipoatrophy. The 18-month open-label clinical trial enrolled 94 men and six women who received calcium hydroxylapatite injections into the submalar region. All patients were rated as improved or better on the Global Aesthetic Improvement Scale at every time point through 12 months; 91 percent were rated as improved or better at 18 months. In addition, skin thickness measurements were statistically improved at 12 months compared with baseline. Adverse events resulting from the treatment were mild (e.g., ecchymosis, edema, erythema, pain, pruritus) and of short duration.<sup>31</sup>

The other four clinical trials were performed in healthy patients seeking a fuller appearance to the cheeks. For example, one study (n = 19) treated women with signs of midface volume loss by injecting calcium hydroxylapatite into the subdermal and subcutaneous planes of the malar area. At 6 months, physician-assessed Global Aesthetic Improvement Scale ratings indicated that 15 of the remaining 16 subjects were improved, much improved, or very much improved. Patient-assessed Global Aesthetic Improvement Scale ratings were similar, with 14 patients reporting their appearance was improved, much improved, or very much

improved. Adverse events were reported in two patients; one reported mild edema and hematoma, and another reported mild ecchymosis and edema.<sup>32</sup>

### **Poly-L-lactic acid**

A total of 33 studies examined outcomes following poly-L-lactic acid soft-tissue filler (Sculptra; Sanofi-Aventis, Bridgewater, N.J.) treatment, including one systematic review, two randomized controlled trials, four uncontrolled clinical trials, seven cohort studies, and 19 case series/reports. Of the 14 studies (excluding case series/reports), seven studies evaluated the filler's use in cheeks only; two studies evaluated its use in cheeks and other sites (e.g., temples, infraorbital groove, perioral region, periorbital region); and the remaining five studies focused on injection sites including facial scars, nasolabial fold, neck and chest, and hand.

**Cheeks.** One systematic review, two randomized controlled trials, two uncontrolled clinical trials, and two cohort studies assessed the use of poly-L-lactic acid in cheeks as the only injection site. Two additional cohort studies reported data on multiple injection sites that included cheeks. The majority of these studies were conducted exclusively in patients with human immunodeficiency virus (five studies), whereas two studies included both human immunodeficiency virus–positive and human immunodeficiency virus–negative patients. The remaining study evaluated poly-L-lactic acid for cosmetic use in cheeks and other sites.

The systematic review, published in 2006, identified six clinical trials that assessed the intradermal injection of poly-L-lactic acid for the treatment of human immunodeficiency virus–associated lipoatrophy. Based on results from the clinical trials, the review found that patients who received poly-L-lactic acid had improved cutaneous thickness. In addition, adverse events were mild and tolerable in most patients. However, the review noted that all six trials were conducted primarily in white men and that further research is needed in nonwhite populations.<sup>33</sup>

The other studies that included patients with human immunodeficiency virus similarly support the use of poly-L-lactic acid in cheeks. For example, a randomized controlled trial (n = 30) that randomized subjects to immediate or delayed poly-L-lactic acid treatments found that both treatment groups sustained significant improvements in facial assessment using visual analogue scale scores at 18 months compared with baseline (immediate,  $p < 0.05$ ; delayed,  $p < 0.001$ ). The randomized controlled trial also determined that patients' Hospital Anxiety and Depression Scale scores improved for both groups

following treatment ( $p < 0.05$ ). This change was statistically significant ( $p < 0.05$ ) for Depression scores in the delayed group. The randomized controlled trial reported one case of injection-site induration and nine cases of injection-site nodules, none of which was described as serious or severe.<sup>34</sup>

One retrospective study conducted in the United Kingdom ( $n = 221$ ) evaluated the use of poly-L-lactic acid for cosmetic purposes. The majority of subjects in this study were women who received facial injections in a variety of specific sites, including cheeks, chin, perioral region, and periorbital region. The study observed that subjects treated with poly-L-lactic acid reported cosmetic improvements that were sustained for up to 24 months. The most frequently reported adverse events were related to injection and resolved spontaneously within several days with no further treatment; however, the study found that treatment to the perioral and periorbital regions was associated with an increased risk of papules or nodules.<sup>35</sup>

**Other sites.** Two studies examined the use of poly-L-lactic acid in the nasolabial fold. One of these studies, published in 2008, was a clinical trial conducted in Brazil that assessed poly-L-lactic acid treatment in the nasolabial folds of 10 healthy women for aesthetic reasons. The study concluded that poly-L-lactic acid was able to correct nasolabial folds successfully, with results lasting up to 18 months for most subjects and up to 36 months for four subjects. Minor complications (e.g., edema, small hematomas) lasting 2 to 10 days after injection were observed in several subjects.<sup>36</sup> The other study was a prospective cohort study from Spain ( $n = 138$ ) that was limited to human immunodeficiency virus–infected subjects presenting with antiretroviral-associated facial lipoatrophy. Following subjects for 96 weeks, the study compared the effects of poly-L-lactic acid treatment to polyacrylamide gel and autologous fat treatments for correcting sunken nasolabial folds. No serious adverse events were detected with any of the treatments. All treatments were determined to be effective based on clinical inspection and facial photographs of patients for up to 48 weeks.<sup>37</sup>

One clinical trial conducted in the United States ( $n = 20$ ) treated patients with poly-L-lactic acid for facial scars resulting from moderate to severe acne or varicella. Results from the trial indicate that poly-L-lactic acid was effective in significantly reducing scar size. Adverse events were limited and not related to treatment.<sup>38</sup>

A retrospective cohort study conducted in the United States ( $n = 26$ ) examined data from three clinical practices using poly-L-lactic acid to rejuvenate the aging hand. The study reported that patients

were very satisfied with the results of the treatment and experienced only minor and short-term injection-related adverse events.<sup>39</sup>

As previously described, a retrospective study conducted in the United Kingdom ( $n = 221$ ) found that nodules occurred in subjects who were treated with poly-L-lactic acid in the perioral and periorbital regions. As such, the study recommended that these areas be avoided as sites for poly-L-lactic acid treatment.<sup>35</sup>

### **Polymethylmethacrylate**

Our search returned two randomized controlled trials and one cohort study on polymethylmethacrylate soft-tissue fillers (Artefill). In addition, we identified 10 case series/reports pertaining to polymethylmethacrylate.

The two studies that compared polymethylmethacrylate to a collagen filler were related studies. A 2004 randomized controlled trial ( $n = 251$ ) investigated polymethylmethacrylate (Artefill), using Zyderm II or Zyplast as a control, to compare the cosmetic correction and explore the safety of polymethylmethacrylate at 1, 3, 6, and 12 months as an injectable implant. Nasolabial fold correction was assessed by masked observers (using photographs) and investigator ratings using the facial fold assessment scale. Although there were no statistically significant differences in cosmetic correction between the two fillers after 1 month, polymethylmethacrylate exhibited significant improvement by the 3-month evaluation (masked observers,  $p < 0.001$  for both groups). Polymethylmethacrylate correction continued until the final follow-up at 12 months ( $p < 0.001$  for both groups). Although adverse events were uncommon in both groups, redness, swelling, and lumpiness were noted more in the collagen group. There were a total of 27 adverse events in the Artefill group compared with 38 in the collagen-treated group ( $p =$  not significant). It was concluded that the study demonstrated the safety and effectiveness of Artefill relative to the collagen control for the treatment of nasolabial folds.<sup>18</sup>

In 2006, the authors published a follow-up study on a subgroup of patients ( $n = 69$ ) who received polymethylmethacrylate, recalled 4 to 5 years later. Investigator Facial Fold Assessment Scale ratings at 4 or 5 years were improved from baseline by 1.67 points ( $p < 0.001$ ). With respect to adverse events experienced, five patients reported six late adverse events, of 272 wrinkles injected (2.2 percent), that occurred from 2 to 5 years after the initial injection. Four were cases of mild lumpiness, and two were severe, including a nodular, minimally inflammatory to non-inflammatory reaction in both nasolabial folds.<sup>19</sup>

In 2007, the same investigators published a 5-year follow-up study of the polymethylmethacrylate filler-treated cohort that participated in the original randomized controlled trial to evaluate the long-term safety and efficacy of the product. Facial fold assessment ratings were performed by blinded observers at 5 years compared with baseline, and the polymethylmethacrylate filler maintained significant nasolabial fold correction at 5 years compared with baseline ( $p < 0.001$ ). As such, polymethylmethacrylate is the only U.S. Food and Drug Administration-approved filler with a documented durability over a 5-year period. Of the 145 subjects that were evaluated for safety, 20 treatment-related adverse events were observed among 15 subjects; the most commonly observed was lumpiness, and it was deemed mild in 80 percent of cases. The polymethylmethacrylate filler may offer additional safety benefits because of the fact that few repeated treatments are needed.<sup>20</sup>

#### **Level of experience/training and supervision of staff administering filler**

None of the studies from our review directly evaluated the level of experience or training of staff administering the filler. In most cases, studies did not indicate who provided the injections. Among the studies that did specify the staff, most reported that a physician performed the injection.

A 2007 case series described three adverse reactions experienced by patients receiving injections at a clinic administered by a practitioner with no medical training or supervision. Records indicated that the injections contained silicone oil, but the study indicated that this could not be verified subsequent to patients' adverse reactions. In one case, a woman experienced headache and vomiting only 30 minutes after injection. On arrival at an emergency department, she was found to be experiencing acute renal failure. Two other cases required emergency department visits and hospital admissions with interventions such as hemodialysis for up to 5 weeks. An investigation of the facility treating these patients found multiple breaches of standard infection-control practice, and promotional materials on the Internet indicated a family medicine practice. The practitioner in question was trained as a radiology technician and had administered the soft-tissue filler injections without medical supervision. These findings emphasize the risks involved with soft-tissue filler injections administered by practitioners with no medical training, and the importance of public health officials' awareness of adverse events associated with such injections.<sup>40</sup>

In a 2006 study from Brazil, complications after polymethylmethacrylate injection are presented.

A variety of practitioners were responsible for administering the injections, including certified plastic surgeons ( $n = 16$ ), dermatologists ( $n = 9$ ), urologists ( $n = 2$ ), and one nonphysician (i.e., a nurse). Despite this discrepancy in level of experience and training, the study does not explicitly address or associate the onset of adverse events with this. It is concluded that, despite being rare, complications caused by polymethylmethacrylate filler injection are often difficult to treat and that safety guidelines should be observed when using the filler for augmentation.<sup>41</sup>

As described previously, a prospective, blinded, randomized controlled trial ( $n = 283$ ) conducted in 2008 in the United States compared the use of two hyaluronic acid fillers, Restylane and Perlane, for midface volume correction of nasolabial folds and marionette lines. Injection was performed at a total of 1021 sites across the patient population, and touch-up injections were discouraged, to parallel clinical practice. Patients were followed for 12 weeks for adverse events only. A total of 336 local injection-related events were reported at 12 weeks, including bruising, tenderness, edema, and pain. Furthermore, the incidence of local adverse events was higher at 72 hours after injection compared with 2 weeks. The preliminary logistic regression demonstrated that injection technique variables strongly influenced the rate of local adverse events, including injection type, fanlike injection technique, injection volume, and correction time. It was also determined that other variables, such as the product injected, injection site, and injection depth were not found to be correlated with the rate of local adverse events. The authors concluded that local adverse events following injection with the hyaluronic acid gel fillers used were related to investigator technique and not intrinsic differences between the hyaluronic acid filler properties, which suggested that moderating the rate of injection of hyaluronic acid fillers may lessen the onset of local adverse events.<sup>12</sup>

#### **Adverse event reporting**

**Registries and databases.** Registries and databases have been used to collect adverse event data associated with injectable soft-tissue filler devices. Although data from these sources cannot be used to draw conclusions between the use of soft-tissue fillers and adverse events, they do provide important data that have the potential to identify possible associations.

The U.S. Food and Drug Administration maintains the Manufacturer and User Facility Device Experience database, which represents voluntary reports of adverse events involving medical devices,

such as soft-tissue fillers. A recent U.S. Food and Drug Administration analysis of soft-tissue filler devices stated that 930 cases of adverse events were reported from January 1, 2003, through September 20, 2008. The most frequently reported injection site was the nasolabial fold, accounting for 35.6 percent of the reports in which the site of injection was specified. However, the majority of reported adverse events occurred in sites other than the nasolabial fold (e.g., lips, periorbital region, perioral region).<sup>1,42</sup>

The analysis found that many of the reported adverse events were mild, such as minor swelling and erythema, and were expected reactions, which are specified in the product labeling. However, several adverse events were unexpected and serious in nature, such as facial, lip, and eye palsy; disfigurement; and retina vascular occlusion. A few rare but potentially fatal events were reported, such as severe allergic reactions and anaphylactic shock. In addition, some of the mild adverse events that occurred shortly after treatment had delayed onset and/or developed into more serious problems. The U.S. Food and Drug Administration also noted that a number of reports indicated that the injection was performed by untrained personnel or in nonclinical settings, which may have contributed to the occurrence of the adverse event.<sup>42</sup>

Although the U.S. Food and Drug Administration's analysis provides some insight into adverse events associated with soft-tissue fillers, the U.S. Food and Drug Administration noted the limitations of the data analysis. For example, a number of reports did not specify the site of injection (n = 394), and many reports indicated that a patient received injections at multiple sites but did not specify which site was involved with the adverse event reported.<sup>42</sup>

The largest adverse event registry identified by our review comprised a database maintained by Q-Med Esthetics, a medical device company that manufactures nonanimal stabilized hyaluronic acid fillers (Restylane, Perlane, and Restylane Fine Lines). The database includes adverse event data from 1999 and 2000 that were collected from physicians in Europe, Canada, Australia, South American, and Asia. A retrospective review of these data found that approximately 144,000 patients were treated with hyaluronic acid in 1999. During that year, 104 cases of hypersensitivity, 68 cases of injection-site inflammation, and 30 cases of other adverse events were reported. No systemic symptoms or anaphylaxes were reported; however, there were rare reports of localized granulomatous reactions, bacterial infection, and acneiform and cystic lesions. In 2000, an estimated 262,000 patients were treated, and 52 cases of hypersensitivity, 49 cases of injection-site

inflammation, and 43 cases of other adverse events were reported. Two cases of injection-site necrosis were reported in the glabellar area a few days after injection. Rare reports of granulomatous reactions, bacterial infection, and acneiform and cystic lesions were also reported in 2000. The study concluded that hypersensitivity was the greatest risk associated with hyaluronic acid fillers; however, the study indicated that the introduction of a more purified hyaluronic acid material during 1999 appeared to decrease the incidence of hypersensitivity.<sup>43</sup>

Our review identified two studies reporting data from the Berlin-based Injectable Filler Safety registry, a partially population-based registry collecting data regarding adverse reactions to injectable fillers. One of these studies discussed the occurrence of adverse events following poly-L-lactic acid treatment. The study contacted 583 physicians in private practices and clinics and achieved a 57.3 percent response rate. Based on the responses by the responding physicians, the study identified 22 patients with adverse reactions to poly-L-lactic acid. The most frequent adverse event report was nodule formation, which occurred in all 22 patients, followed by pigmentation (n = 8) and inflammation (n = 5). The mean latency between first treatment with poly-L-lactic acid and the first appearance of adverse reaction was  $6.00 \pm 5.84$  months. Of the 22 patients with nodule formation, 13 were described as severe. The study noted that the frequency of reported adverse reactions to poly-L-lactic acid decreased after 2004, during which the recommended dilution of poly-L-lactic acid was changed from 3 ml to 5 ml. Even with increased dilution of poly-L-lactic acid, the study concluded that adverse events still occur and advised that poly-L-lactic acid continue to be monitored for safety.<sup>44</sup>

The other study on the Berlin Injectable Filler Safety registry characterized adverse reactions to DermaLive (Dermatech, Paris, France), a fixed combination of hydroxyethylmethacrylate and ethylmethacrylate with hyaluronic acid. The study identified 30 patients who were treated with this filler. The most frequently treated sites were the nasolabial folds (65 percent), followed by glabella and lips. Of the 95 treated sites, 87 reported the occurrence of an adverse reaction. The most frequently observed adverse events were the formation of nodules (n = 85), discoloration (n = 39), erythema or inflammation (n = 32), and swelling (n = 24). Most nodular reactions were rated as severe. The mean time after the last treatment to appearance of an adverse reaction was  $23.1 \pm 22.8$  months, a considerably longer latency period than that observed for poly-L-lactic acid in the study described above. Based on the frequency and

**Table VI.** Distribution of case series/reports by soft-tissue filler

Soft-tissue filler	No. of studies
Collagen	17
Hyaluronic acid	39
Poly-L-lactic acid	19
Calcium hydroxylapatite	11
Polymethylmethacrylate	10
Other	20

severity of the adverse reactions to DermaLive, the authors of this study recommended against the use of this filler.<sup>45</sup>

### Case series/reports

In addition to the three studies on adverse event registries, our review identified 96 case series/reports presenting a variety of adverse events. Detailed information on adverse events reported in these case series/reports and other studies can be found in the evidence tables in Appendix B (available at <http://www.eblue.org>). Table VI shows the breakdown of these studies by soft-tissue filler type. Of the 96 case studies we identified, the majority involved use of a hyaluronic acid filler.

Table VII below presents the total number of case reports in our review that reported on adverse events. Among the various types of adverse events reported, swelling, inflammatory reactions, and erythema were most often reported.

### OUTCOMES IN SUBJECTS WITH FITZPATRICK SKIN TYPES IV THROUGH VI

Among the studies we identified and reviewed, three specifically analyzed the effects of a soft-tissue filler in patients with Fitzpatrick skin types IV through VI. Since 2003, the U.S. Food and Drug Administration has required postapproval studies of soft-tissue fillers in the population with Fitzpatrick skin types IV through VI, a group that was underrepresented in premarket clinical studies of soft-tissue fillers. Our search identified a recently published study, which presented results from two randomized controlled trials that followed subjects with Fitzpatrick skin phototypes of IV, V, or VI for 24 weeks after soft-tissue filler injection into the nasolabial fold. In one of these randomized controlled trials (n = 160), subjects were randomized to one of three high-concentration hyaluronic acid fillers in one nasolabial fold and collagen in the other. In the second randomized controlled trial (n = 119), subjects were randomized to receive one of three low-concentration hyaluronic acid fillers in both

**Table VII.** Distribution of case series/reports by adverse event reported

Adverse event	No. of studies
Allergic reaction	5
Swelling	24
Inflammatory reaction	20
Erythema	18
Infection	4
Vascular event	2
Pain	7
Blister/cyst	8
Nonspecific mass	15
Beading	13
Numbness	0
Migration	1
Biofilm	0
Other adverse event	14

nasolabial folds. The majority of subjects in both randomized controlled trials maintained improvement in nasolabial fold severity scores through 24 weeks. For subjects treated with the high-concentration fillers, there were no occurrences of hypersensitivity or hypertrophic scarring and no increased incidence of hyperpigmentation or hypopigmentation. For subjects treated with the low-concentration fillers, there were three cases of mild hyperpigmentation and no instances of keloid formation, hypertrophic scarring, hypopigmentation, or hypersensitivity. Overall, these findings suggest that all of the fillers were effective and well tolerated in individuals with skin of color.<sup>46</sup>

The second study we identified relevant to subjects with Fitzpatrick skin types IV through VI also reported that a soft-tissue filler was efficacious and safe in this population. This open-label, nonrandomized trial evaluated 100 subjects with Fitzpatrick skin types IV through VI who received subdermal injections of calcium hydroxylapatite for correcting moderate to severe nasolabial folds. For up to 6 months after treatment, there were no signs of keloid formation, hypertrophic scarring, hyperpigmentation or hypopigmentation, or other clinically significant adverse events.<sup>29</sup> Similarly, a case series comparing hyaluronic acid treatment in 40 patients with Fitzpatrick skin types I through III with 20 patients with Fitzpatrick skin types IV through VI concluded that patients with Fitzpatrick skin types IV through VI achieved improved aesthetic outcomes that were similar to patients with other skin types. No transient or permanent adverse events were reported among patients with Fitzpatrick skin types IV through VI.<sup>47</sup>

In addition to the three studies described above, five studies included individuals with Fitzpatrick skin

types IV through VI in their study sample. Although the five studies do not conduct subgroup analyses in patients with different skin types, their findings may be potentially relevant to individuals with Fitzpatrick skin types IV through VI, depending on the extent to which these individuals are represented in the study population. We identified one randomized controlled trial ( $n = 439$ ) in particular that included a relatively high percentage of subjects with Fitzpatrick skin types IV through VI. This randomized controlled trial ( $n = 439$ ) compared the effectiveness and safety of hyaluronic acid with collagen for treating nasolabial folds in subjects of all Fitzpatrick skin types (type I, 4 percent; type II, 24 percent; type III, 35 percent; type IV, 20 percent; type V, 13 percent; and type VI, 3 percent). Results from this randomized controlled trial were published in two studies from our review. One of these studies analyzed outcomes for all 439 subjects and reported that hyaluronic acid soft-tissue fillers offer safer and longer-lasting clinical correction than collagen. The study did not present the results by skin type; however, it mentioned that the pattern and incidence of treatment-site reactions were generally similar between white and nonwhite subjects.<sup>3</sup> The second study examined a set of 87 patients (36 percent with Fitzpatrick skin types IV through VI) classified as having severe nasolabial folds and similarly concluded that hyaluronic acid is a safe and effective soft-tissue filler that provides correction for 1 year or more.<sup>4</sup>

## **PREDICTIVE ABILITY AND ACCURACY OF EVALUATION METHODS**

In addition to conducting a review of the safety, efficacy, and effectiveness of soft-tissue fillers, we also searched for studies focused on the predictive ability and accuracy of evaluation methods used for both approved and off-label use of soft-tissue fillers. Our search identified no directly relevant studies. However, studies identified in our search often described the specific methods and tools used to assess various outcomes of interest. The following section provides an overview of the types of outcomes that were measured in these studies and the methods and tools used to assess these outcomes. None of the methods or tools we came across was used to predict treatment outcomes resulting from the use of soft-tissue fillers.

### **Efficacy/effectiveness outcomes**

Across the literature on soft-tissue fillers, effectiveness was often determined by the level of aesthetic improvement. Although aesthetic improvement may be subjective and difficult to quantify, a variety of

evaluation tools have been developed that aim to improve the validity and reliability of assessments. These tools include ratings of appearance, patient satisfaction, and treatment success, which were used in studies evaluating on-label or off-label uses of soft-tissue fillers. For studies on facial augmentation for human immunodeficiency virus–associated lipotrophy, evaluation tools often included methods to determine skin thickness. Evaluation tools that were less frequently used included patient questionnaires on quality of life and psychological state and three-dimensional imaging.

Although many studies assessed patient satisfaction, very few used validated scales. This finding was confirmed by a systematic review on patient-reported outcome measures for facial cosmetic surgery and nonsurgical facial rejuvenation. The review found that valid, reliable, responsible instruments to measure these outcomes are lacking. Based on an assessment of the available literature, the review concluded that there is a need to develop patient-reported outcome measures designed to measure satisfaction with facial appearance following aesthetic procedures.<sup>48</sup>

### **Ratings of appearance**

Despite the large variation across the evidence with regard to soft-tissue filler type, injection technique, injection site, study population, and on-label versus off-label uses, the majority of studies evaluating aesthetic appearance included the use of a validated scale, such as the Global Aesthetic Improvement Scale, the Wrinkle Severity Rating Scale, the Facial Fold Assessment scale, the Lemperle Rating Scale, the Nasal Fold Severity scale, and the Modified Fitzpatrick Wrinkle Scale. The evaluation process incorporating these validated scales varied across the studies we reviewed. Studies differed with regard to the evaluator (e.g., investigator, physician, expert panel, patient), masked versus unmasked assessment, and live versus photographic assessment.

Studies that did not use a validated scale to assess aesthetic outcomes tended to examine off-label uses of a soft-tissue filler. For example, one uncontrolled clinical trial on hyaluronic acid treatment for correcting downturned mouth corners used a four-point scale that included “no difference,” “slight improvement,” “moderate improvement,” and “superb improvement.”<sup>15</sup> One randomized controlled trial ( $n = 44$ ) that treated patients’ lips with bovine collagen (Zyplast) or an injectable acellular dermal graft (Cymetra) assessed lip aesthetics by photographing patients and using a ruler to measure changes in the nasolabial angle, percentage of the total lip accounted for by the exposed red lip in the midline



and on the lateral view, the visible red upper and lower lip surface areas, and the anterior projection of the upper and lower lips.<sup>23</sup>

### Ratings of treatment success

Several studies used scales to rate treatment success; however, all of these scales appeared to be nonvalidated. Furthermore, these studies provided very little detail on how the scales were developed or what the criteria were for each score within the scale. For example, the investigators for one randomized controlled trial (n = 119) used a five-point ordinal scale to rate the success of polymethylmethacrylate treatment. The only description for this scale was a list of the scores, which included “completely successful,” “very successful,” “moderately successful,” “somewhat successful,” and “not at all successful.”<sup>20</sup>

### Measurements of skin thickness

Particularly in studies focusing on human immunodeficiency virus–associated lipoatrophy, skin thickness was a frequently assessed outcome measure. None of the methods for determining skin thickness was validated in these studies. The most frequently used method for measuring skin thickness involved skin calipers. For example, in an open-label trial in which patients received serial injections of poly-L-lactic acid, patients were evaluated for increase in total cutaneous thickness by skin calipers. The study found that patients had a mean increase in skin thickness of 65.1 percent after treatment compared with baseline values.<sup>49</sup>

### Safety outcomes

There was great variation in the level of adverse event reporting across the studies we reviewed. Most interventional and epidemiologic studies (i.e., non–case series/reports) simply reported the incidence and severity of local and systematic adverse events. In general, these studies observed few adverse events, which were transient and mild in nature and the majority of which were associated with the injection process, such as ecchymosis and erythema.

Several studies reported safety data beyond adverse event incidence and descriptions of severity. For example, one open-label trial (n = 25) measured the level of cutaneous inflammation after hyaluronic acid injection using an erythema meter and infrared thermometer. These measurements indicated that hyaluronic acid caused some initial inflammation at 10 to 20 minutes after injection; however, the inflammation decreased substantially by 3 hours.<sup>50</sup>

Another clinical trial (n = 58) used radiography and computed tomography to assess whether calcium hydroxylapatite poses radiographic safety

concerns. Blinded radiologists determined that calcium hydroxylapatite is usually visible and does not obscure underlying structures on computed tomographic scans. In addition, there is no evidence that calcium hydroxylapatite migrates or that osteogenesis results from the calcium hydroxylapatite being placed in the deep dermis and subcutaneous plane.<sup>30</sup>

We identified five studies that characterized the immunologic safety profile of a soft-tissue filler.<sup>5-27,51,52</sup> For example, in a study assessing Restylane and Perlane for nasolabial fold correction, Hamilton et al. used skin and serology testing to evaluate humoral immune responses with potential for immediate (type I) or immune complex–mediated (type II and III) hypersensitivity. The study also gathered histopathologic data using biopsy specimens collected from skin test sites to examine subjects for possible cell-mediated inflammation that is associated with delayed (type IV) hypersensitivity. Based on these evaluations, the study determined that non–animal-stabilized hyaluronic acid does not elicit clinical/laboratory evidence for cellular or humoral immune responses in 98 percent of individuals, supporting the conclusion that Restylane and Perlane are not commonly immunogenic or allergenic.<sup>51</sup> The other four studies assessed the use of collagen as a soft-tissue filler, including one study that conducted serum anticollagen antibody tests and three studies that conducted histologic tests. All four studies found that the examined collagen filler had low potential for immunologic reactions.<sup>25-27,52</sup>

### IMPLICATIONS FOR FUTURE RESEARCH

To inform and support the work of the state-of-the-science conference panel on soft-tissue fillers, this report summarizes and assesses the available literature related to soft-tissue fillers. Our search in PubMed returned a total of 198 relevant in-scope studies, including four systematic reviews, 33 randomized controlled trials, two controlled clinical trials, 41 uncontrolled clinical trials, 18 cohort studies, three cross-sectional studies, and 97 case series or reports. The studies included in this review varied greatly with regard to study populations, treatment technique (e.g., volume of filler, number of injections, injection site), and outcomes measured. Although we classified four studies as systematic reviews, only one of these studies documented the methods they used, whereas the other three studies simply mentioned that a literature search was performed. Among the available literature, hyaluronic acid fillers were the most frequently discussed filler type (n = 83 studies), followed by collagen (n = 34 studies), poly-L-lactic acid (n = 33 studies), calcium hydroxylapatite (n = 32), and polymethylmethacrylate (n = 13 studies) fillers. A number

**Table VIII.** Full-text studies reviewed by type of study and quality of evidence grade

Type of study	Good	Fair	Poor
SR	0	0	4
RCT	22	9	2
CCT	0	1	1
UCT	0	0	41
Cohort	0	1	17
Cross-sectional	0	0	3
Case series/case report	0	0	97
Total	22	11	165

SR, Systematic review; RCT, randomized controlled trial; CCT, controlled clinical trial; UCT, uncontrolled clinical trial.

of studies (n = 36) also addressed other filler types such as silicone oil or polyacrylamide gel.

The quality of the studies we captured ranged from several well-designed randomized controlled trials meeting a “good” quality rating to many case reports of single patients, which received a “poor” quality rating. Twenty-two of the 33 reviewed randomized controlled trials received a “good” quality rating, whereas only two randomized controlled trials were graded as “poor.” Thus, the majority of soft-tissue filler randomized controlled trials, although not overwhelming in number, were high-quality studies. The remaining studies, without formal randomization and/or comparison groups, based on the grading system we used, could not receive a grade higher than “fair,” and only two of the studies that were not randomized controlled trials received a “fair” rating. The 97 case series, with inherent methodologic limitations, were unilaterally marked as “poor.” Table VIII presents the grades given across the studies we reviewed. Although the grading was largely based on study design, it should be noted that many of the studies reviewed satisfied a number of other criteria that were included in our evaluation. Evidence tables in Appendix A include the quality grades that were assigned to each study.

Overall, the evidence indicates that soft-tissue fillers are effective and well tolerated for correcting nasolabial folds, other moderate to severe wrinkles and folds, and volume loss in cheeks. These findings were observed among patients seeking aesthetic facial rejuvenation and patients with human immunodeficiency virus–associated facial lipoatrophy. In general, the adverse events in studies focusing on these treatment sites were mild and transient, such as erythema and ecchymosis, and typically resolved within several days without treatment; however, several studies reported the formation of nodules in several patients. The reported longevity of soft-

tissue filler effects varied to some extent across studies; however, duration of results generally depended on the composition of the filler. The effects of biological products such as collagen and hyaluronic acid typically lasted for less than 1 year after treatment. Semipermanent fillers, including poly-L-lactic acid and calcium hydroxylapatite, were observed to persist for 1 to 2 years in patients. Nonabsorbable fillers such as polymethylmethacrylate, silicone oil, and polyacrylamide gel achieved the longest lasting aesthetic results, persisting for over 2 years in some studies.

The small number of quality studies examining other treatment sites (e.g., lips, perioral region, periorbital region) limits the ability to draw firm conclusions regarding the use of soft-tissue fillers in these areas. Although nearly all patients indicated high levels of satisfaction in studies on other treatment sites, these studies tended to have methodologic shortcomings, including small sample sizes and the use of unvalidated evaluation tools. Adverse events observed were generally minor in other treatment sites; however, data from one study indicated an increased risk of nodules associated with the use of poly-L-lactic acid treatment in the perioral and periorbital regions.

None of the studies from our review evaluated the impact of different staff administering soft-tissue filler treatment or the validity of assessment tools. Our review identified very few studies of patients with Fitzpatrick skin types IV through VI. The three studies that specifically assessed outcomes in these patients consistently reported favorable efficacy and safety outcomes following treatment with a soft-tissue filler. Based on our review of the literature, several gaps in the current evidence base were observed, including the following key issues.

#### **Need for long-term safety and efficacy data**

Although the body of evidence we identified demonstrated that soft-tissue fillers are efficacious, effective, and in general fairly safe, the vast majority of studies we examined had limited follow-up periods. Only one study followed patients for 5 years.

#### **Need for studies addressing the impact of staff administering treatment**

Soft-tissue fillers are being administered by a variety of practitioners, ranging from trained plastic surgeons and cosmetic dermatologists to nonclinicians. Although the training and experience of individuals administering fillers is a growing concern, our review of the literature found no studies that addressed this issue.

### Development and validation of evaluation tools for assessing effectiveness

Again, our review of the evidence found no directly relevant studies that assessed tools to evaluate the use of soft-tissue fillers. For example, although patient satisfaction following injection of a soft-tissue filler is often examined, similar to our findings, a systematic review of patient-reported outcome measures also found valid, reliable instruments to measure these outcomes to be lacking. To the extent that efforts are made to meet the growing use and demand for soft-tissue fillers through research and development of new and longer lasting fillers, these types of issues should be explored and addressed to ensure the continued safety, efficacy, and effectiveness of these devices.

The American Academy of Dermatology and the American Society of Plastic Surgeons contracted with The Lewin Group, a health and human services consulting firm located in the Washington, D.C., metropolitan area, to provide analytical support to the conference, including a systematic literature review to inform the work of an expert panel that was to be established for the conference. The Lewin Group was also contracted to facilitate the expert panel discussion during the conference and summarize the findings of the conference in the present report.

### REFERENCES

1. U.S. Department of Health and Human Services, U.S. Food and Drug Administration. Panel Meeting Summary: November 18-19, 2008 Meeting of the General and Plastic Surgery Devices Panel. Available at: <http://www.fda.gov/cdrh/panel/summary/gpsd-111808.html>. Accessed March 22, 2009.
2. Agency for Healthcare Research and Quality. Methods Reference Guide for Effectiveness and Comparative Effectiveness Reviews, Version 1.0 (draft posted October of 2007). Available at: [http://effectivehealthcare.ahrq.gov/repFiles/2007\\_10DraftMethodsGuide.pdf](http://effectivehealthcare.ahrq.gov/repFiles/2007_10DraftMethodsGuide.pdf). Accessed 2009.
3. Baumann LS, Shamban AT, Lupo MP. Comparison of smooth-gel hyaluronic acid dermal fillers with cross-linked bovine collagen: A multicenter, double-masked, randomized, within-subject study. *Dermatol Surg* 2007;33(Suppl 2):S128-35.
4. Lupo MP, Smith SR, Thomas JA, Murphy DK, Beddingfield FC III. Effectiveness of Juvéderm Ultra Plus dermal filler in the treatment of severe nasolabial folds. *Plast Reconstr Surg* 2008;121:289-97.
5. Narins RS, Brandt F, Leyden J, Lorenc ZP, Rubin M, Smith S. A randomized, double-blind, multicenter comparison of the efficacy and tolerability of Restylane versus Zyplast for the correction of nasolabial folds. *Dermatol Surg* 2003;29:588-95.
6. Narins RS, Brandt FS, Lorenc ZP. A randomized, multicenter study of the safety and efficacy of Dermicol-P35 and non-animal-stabilized hyaluronic acid gel for the correction of nasolabial folds. *Dermatol Surg* 2007;33(Suppl 2):S213-21.
7. Moers-Carpi M, Vogt S, Santos BM, Planas J, Vallve SR, Howell DJ. A multicenter, randomized trial comparing calcium hydroxylapatite to two hyaluronic acids for treatment of nasolabial folds. *Dermatol Surg* 2007;33(Suppl 2):S144-51.
8. Moers-Carpi MM, Tufet JO. Calcium hydroxylapatite versus nonanimal stabilized hyaluronic acid for the correction of nasolabial folds: A 12-month, multicenter, prospective, randomized, controlled, split-face trial. *Dermatol Surg* 2008;34:210-5.
9. Carruthers A, Carey W, De Lorenzi C, Remington K, Schachter D, Sapra S. Randomized, double-blind comparison of the efficacy of two hyaluronic acid derivatives, restylane perlane and hylaform, in the treatment of nasolabial folds. *Dermatol Surg* 2005;31:1591-8.
10. Onesti M, Toscani M, Curinga G, Chiummariello S, Scuderi N. Assessment of a new hyaluronic acid filler: Double-blind, randomized, comparative study between Puragen and Cap-tique in the treatment of nasolabial folds. *In Vivo* 2009;23:479-86.
11. Denton AB, Tsaparas Y. Injectable hyaluronic acid for the correction of HIV-associated facial lipatrophy. *Otolaryngol Head Neck Surg* 2007;136:563-7.
12. Glogau RG, Kane MA. Effect of injection techniques on the rate of local adverse events in patients implanted with nonanimal hyaluronic acid gel dermal fillers. *Dermatol Surg* 2008;34(Suppl 1):S105-9.
13. Kono T, Kinney BM, Groff WF, Chan HH, Ercocen AR, Nozaki M. Randomized, evaluator-blind, split-face comparison study of single cross-linked versus double cross-linked hyaluronic acid in the treatment of glabellar lines. *Dermatol Surg* 2008;34(Suppl 1):S25-30.
14. Man J, Rao J, Goldman M. A double-blind, comparative study of nonanimal-stabilized hyaluronic acid versus human collagen for tissue augmentation of the dorsal hands. *Dermatol Surg* 2008;34:1026-31.
15. Carruthers J, Klein AW, Carruthers A, Glogau RG, Canfield D. Safety and efficacy of nonanimal stabilized hyaluronic acid for improvement of mouth corners. *Dermatol Surg* 2005;31:276-80.
16. DeLorenzi C, Weinberg M, Solish N, Swift A. The long-term efficacy and safety of a subcutaneously injected large-particle stabilized hyaluronic acid-based gel of nonanimal origin in esthetic facial contouring. *Dermatol Surg* 2009;35(Suppl 1):313-21.
17. Distanto F, Pagani V, Bonfigli A. Stabilized hyaluronic acid of non-animal origin for rejuvenating the skin of the upper arm. *Dermatol Surg* 2009;35(Suppl 1):389-93; discussion 394.
18. Cohen SR, Holmes RE. Artecoll: A long-lasting injectable wrinkle filler material. Report of a controlled, randomized, multicenter clinical trial of 251 subjects. *Plast Reconstr Surg* 2004;114:964-76; discussion 977-9.
19. Cohen SR, Berner CF, Busso M. ArteFill: A long-lasting injectable wrinkle filler material. Summary of the U.S. Food and Drug Administration trials and a progress report on 4- to 5-year outcomes. *Plast Reconstr Surg* 2006;118(3 Suppl):645-76S.
20. Cohen SR, Berner CF, Busso M. Five-year safety and efficacy of a novel polymethylmethacrylate aesthetic soft tissue filler for the correction of nasolabial folds. *Dermatol Surg* 2007;33(Suppl 2):S222-30.
21. Smith S, Busso M, McClaren M, Bass LS. A randomized, bilateral, prospective comparison of calcium hydroxylapatite microspheres versus human-based collagen for the correction of nasolabial folds. *Dermatol Surg* 2007;33(Suppl 2):S112-21.
22. Monstrey SJ, Pitaru S, Hamdi M. A two-stage phase I trial of Evolence30 collagen for soft-tissue contour correction. *Plast Reconstr Surg* 2007;120:303-11.
23. Sclafani AP, Romo T III, Jacono AA. Rejuvenation of the aging lip with an injectable acellular dermal graft (Cymetra). *Arch Facial Plast Surg* 2002;4:252-7.
24. De Bouille BK, Swinberghe S, Engman M, Shoshani D. Lip augmentation and contour correction with a ribose cross-

- linked collagen dermal filler. *J Drugs Dermatol* 2009;8(3 Suppl):1-8.
25. Sclafani AP, Romo T III, Jacono AA, McCormick SA, Cocker R, Parker A. Evaluation of acellular dermal graft (AlloDerm) sheet for soft tissue augmentation: A 1-year follow-up of clinical observations and histological findings. *Arch Facial Plast Surg* 2001;3:101-3.
  26. Sclafani AP, Romo T III, Parker A, McCormick SA, Cocker R, Jacono A. Autologous collagen dispersion (autologen) as a dermal filler: Clinical observations and histologic findings. *Arch Facial Plast Surg* 2000;2:48-52.
  27. Sclafani AP, Romo T III, Parker A, McCormick SA, Cocker R, Jacono A. Homologous collagen dispersion (dermalogen) as a dermal filler: Persistence and histology compared with bovine collagen. *Ann Plast Surg* 2002;49:181-8.
  28. Tzikas TL. A 52-month summary of results using calcium hydroxylapatite for facial soft tissue augmentation. *Dermatol Surg* 2008;34(Suppl 1):S9-15.
  29. Marmur ES, Taylor SC, Grimes PE, Boyd CM, Porter JP, Yoo JY. Six-month safety results of calcium hydroxylapatite for treatment of nasolabial folds in Fitzpatrick skin types IV to VI. *Dermatol Surg* 2009;35(Suppl 2):1641-5.
  30. Carruthers A, Liebeskind M, Carruthers J, Forster BB. Radiographic and computed tomographic studies of calcium hydroxylapatite for treatment of HIV-associated facial lipoatrophy and correction of nasolabial folds. *Dermatol Surg* 2008;34(Suppl 1):S78-84.
  31. Silvers SL, Eviatar JA, Echavez MI, Pappas AL. Prospective, open-label, 18-month trial of calcium hydroxylapatite (Radiesse) for facial soft-tissue augmentation in patients with human immunodeficiency virus-associated lipoatrophy: One-year durability. *Plast Reconstr Surg* 2006;118(3 Suppl):345-45S.
  32. Beer K, Yohn M, Cohen JL. Evaluation of injectable CaHA for the treatment of mid-face volume loss. *J Drugs Dermatol* 2008;7:359-66.
  33. El-Beyrouy C, Huang V, Darnold CJ, Clay PG. Poly-L-lactic acid for facial lipoatrophy in HIV. *Ann Pharmacother* 2006;40:1602-6.
  34. Moyle GJ, Brown S, Lysakova L, Barton SE. Long-term safety and efficacy of poly-L-lactic acid in the treatment of HIV-related facial lipoatrophy. *HIV Med* 2006;7:181-5.
  35. Lowe NJ, Maxwell CA, Lowe P, Shah A, Patnaik R. Injectable poly-L-lactic acid: 3 years of aesthetic experience. *Dermatol Surg* 2009;35(Suppl 1):344-9.
  36. Salles AG, Lotierzo PH, Gimenez R, Camargo CP, Ferreira MC. Evaluation of the poly-L-lactic acid implant for treatment of the nasolabial fold: 3-year follow-up evaluation. *Aesthetic Plast Surg* 2008;32:753-6.
  37. Negrodo E, Higuera C, Adell X. Reconstructive treatment for antiretroviral-associated facial lipoatrophy: A prospective study comparing autologous fat and synthetic substances. *AIDS Patient Care STDS* 2006;20:829-37.
  38. Beer KA. single-center, open-label study on the use of injectable poly-L-lactic acid for the treatment of moderate to severe scarring from acne or varicella. *Dermatol Surg* 2007;33(Suppl 2):S159-67.
  39. Sadick NS, Anderson D, Werschler WP. Addressing volume loss in hand rejuvenation: A report of clinical experience. *J Cosmet Laser Ther* 2008;10:237-41.
  40. Centers for Disease Control and Prevention. Acute renal failure associated with cosmetic soft-tissue filler injections: North Carolina, 2007. *MMWR Morb Mortal Wkly Rep* 2008;57:453-6.
  41. Salles AG, Lotierzo PH, Gemperli R. Complications after polymethylmethacrylate injections: Report of 32 cases. *Plast Reconstr Surg* 2008;121:1811-20.
  42. Mirsaidi N. Post-Market Evaluation of Adverse Events Reported to FDA on Dermal Fillers. Washington, DC: U.S. Food and Drug Administration; 2009.
  43. Friedman PM, Mafong EA, Kauvar AN, Geronemus RG. Safety data of injectable nonanimal stabilized hyaluronic acid gel for soft tissue augmentation. *Dermatol Surg* 2002;28:491-4.
  44. Rossner F, Rossner M, Hartmann V, Erdmann R, Wiest LG, Rzyan B. Decrease of reported adverse events to injectable poly(lactic acid) after recommending an increased dilution: 8-year results from the Injectable Filler Safety study. *J Cosmet Dermatol* 2009;8:14-8.
  45. Rossner M, Rossner F, Bachmann F, Wiest L, Rzyan B. Risk of severe adverse reactions to an injectable filler based on a fixed combination of hydroxyethylmethacrylate and ethylmethacrylate with hyaluronic acid. *Dermatol Surg* 2009;35(Suppl 1):367-74.
  46. Grimes PE, Thomas JA, Murphy DK. Safety and effectiveness of hyaluronic acid fillers in skin of color. *J Cosmet Dermatol* 2009;8:162-8.
  47. Odunze M, Cohn A, Few JW. Restylane and people of color. *Plast Reconstr Surg* 2007;120:2011-6.
  48. Kosowski TR, McCarthy C, Reavey PL. A systematic review of patient-reported outcome measures after facial cosmetic surgery and/or nonsurgical facial rejuvenation. *Plast Reconstr Surg* 2009;123:1819-27.
  49. Mest DR, Humble G. Safety and efficacy of poly-L-lactic acid injections in persons with HIV-associated lipoatrophy: The US experience. *Dermatol Surg* 2006;32:1336-45.
  50. Judodihardjo H, Dykes P. Objective and subjective measurements of cutaneous inflammation after a novel hyaluronic acid injection. *Dermatol Surg* 2008;34(Suppl 1):S110-4.
  51. Hamilton RG, Strobos J, Adkinson NF Jr. Immunogenicity studies of cosmetically administered nonanimal-stabilized hyaluronic acid particles. *Dermatol Surg* 2007;33(Suppl 2):S176-85.
  52. Shoshani D, Markovitz E, Cohen Y, Heremans A, Goldlust A. Skin test hypersensitivity study of a cross-linked, porcine collagen implant for aesthetic surgery. *Dermatol Surg* 2007;33(Suppl 2):S152-8.

Appendix A. ASPS/AAD evidence tables with outcome measures and conclusions, listing studies by dermal filler type and study type

Study	Design	Country/population type	Sample size	Follow-up	Treatment	Injection description	Conclusions	Grade
<b>Hyaluronic Acid Fillers</b>								
<b>Systematic Review: No. of studies, 1</b>								
Price et al., 2007 PMID:17466613	Systematic review	UK	N/A	N/A	HA	N/A	Dermal filler of choice for most surgeons. In 2004, approximately 45,000 treatments were administered by ASPS member surgeons. Increased ten-fold by the following year.	Poor
<b>Randomized Controlled Trial: No. of studies, 25</b>								
Baumann et al., 2007 PMID:18086050	Multicenter, double-masked, randomized, within-subject study	USA/Subjects at least 30 yr and with fully visible bilateral NLFs that were approximately symmetrical (both moderate or both severe)	439 (423)	24 wk	HA: Juvéderm 30 (J30), Juvéderm Ultra (24HV), Juvéderm Ultra Plus (30HV); median, 1.6 ml (0.8–5.6 ml)	Subjects were randomly assigned to receive one of the three smooth-gel HA fillers, intradermally to the NLF on one side of the face. In all subjects, the NLF on the other side of the face was treated with Zyplast.	All the HA dermal fillers resulted in a mean improvement (i.e., a reduction) from baseline in NLF severity score, clinically significant at each time point. Further, the HA dermal fillers provided longer-lasting clinical correction than bovine collagen.	Good
	Patients served as their own control				Zyplast (cross-linked bovine collagen)	Vast majority of subjects had only one treatment visit.	The new smooth gel HA dermal fillers were highly effective in correcting NLFs for 6 mo or longer after treatment. The majority of subjects achieved optimal correction with only a single injection of the HA dermal filler, and the fillers were also similarly well tolerated. An overwhelming majority of subjects expressed a preference for the smooth gel HA dermal fillers over bovine collagen.	

Appendix A. Cont'd

Study	Design	Country/population type	Sample size	Follow-up	Treatment	Injection description	Conclusions	Grade
Beer, 2007 PMID:17661935	Double-blind RCT Patients served as their own control	US/Women	15 (15)	2 wk, 3, 4, 5, and 6 mo	Restylane (HA gel), 0.7–2.1 ml Hylaform Plus (hyalun B plus), 0.7–2.2 ml	A physician or nurse administered a randomly assigned treatment to one side of each patient's nasolabial fold and the other treatment to the nasolabial fold on the opposite side.	The results of this study confirm the efficacy of both HA gel and hyalun B plus gel in correcting nasolabial folds. Both improvement and duration of treatment effect were greater with HA gel than with the hyalun B plus, as shown by posttreatment WSPRS and GAIS assessments.	Good
Randomized Controlled Trial (RCT); No. of studies, 25								
Carruthers et al., 2005 PMID:16416643	Double-blind RCT	Canada/Patients seeking cosmetic correction of moderate to severe nasolabial folds	150 (140)	3, 4, 5, 6 mo	Restylane Perlane, 1.3 ml (avg) ( <i>n</i> = 150) Hylaform, 1.6 ml (avg) ( <i>n</i> = 150)	Contralateral injection of each filler into the mid- or deep dermis nasolabial	Restylane Perlane provides a more durable aesthetic improvement than Hylaform and offers acceptable tolerability	Good
Carruthers J et al., 2003 PMID:12859378	Prospective, parallel group study	Canada/Adult female subjects with moderate to severe glabellar rhytides	38	32 wk	NASHA (Restylane) ( <i>n</i> = 19) BTX-A (Botox) + NASHA (1 wk later) ( <i>n</i> = 19)	1 cm above the supraorbital notch (on both sides)		Good
Dessy et al., 2008 PMID:18833043	Randomized prospective study	Italy/Patients with clear signs of premature facial aging	100	1, 3, 6, 12 mo	Wipeline (HA concentration 1.6%) Wipeline (HA concentration 2.0%)	Site: fold and wrinkles in the face Three sessions with 4-wk intervals between them	The efficacy of this product, Wipeline, has been clinically supported. This revitalizing filler succeeded in increasing skin elasticity and tone by dermal hydration. The procedure is simple and minimally invasive. This is a good option to restore vitality and turgidity of skin presenting signs of aging.	Poor

Glogau et al., 2008 PMID:18547173	Prospective, blinded, randomized controlled study	USA/General population	283	12 wk	Restylane (NASHA-small) (n = 142) Perlane (NASHA-large)	Midface volume correction of the NLFs and oral commissures (marionette lines) 1,021 total injection sites Touch-up injections were discouraged to parallel clinical practice, where correction is usually completed in a single session	Local adverse events following injection with the NASHA gel fillers used in this study were related to investigator technique and not to differences in the intrinsic properties of the NASHA agents, suggesting that moderating the rate of injection of NASHA fillers may lessen the onset of local adverse events. Preliminary logistic regression analysis suggested that adverse events were correlated with the following variables: injection type, fanlike injection technique, injection volume (greater mean volume), and correction time	Good
Goldman et al., 2007 PMID:17451575	Randomized, evaluator blinded, clinical trial	USA/Patients with prominent nasolabial folds	36 (33)	56 d	Restylane, alone and in combination with laser/RF/IPL	Nasolabial folds (treated with HA gel implantation on one side of the face and HA gel followed by one of the nonablative laser/RF/IPL therapies on the contralateral side of the face)	Despite the low number of viable samples, clinical and extrapolated histologic data support the use of laser/RF/IPL treatments directly over HA gel dermal implants without affecting patient safety or implant efficacy.	Fair

Randomized  
Controlled Trial  
(RCT): No. of  
studies, 25

Appendix A. Cont'd

Study	Design	Country/population type	Sample size	Follow-up	Treatment	Injection description	Conclusions	Grade
Grimes et al, 2009 PMID:19735512	Study 1: double-blind, randomized clinical trial Study 2: open-label, randomized clinical trial	USA/Patients with Fitzpatrick skin types IV, V, or VI	Study 1: 160 Study 2: 119	24 wk	Study 1: Juvederm Ultra, Ultra Plus, and 30 and Zyplast collagen Study 2: Hylaform, Hylaform Plus, and Captique	Nasolabial folds	The HA fillers were effective and well tolerated in skin of color, with no occurrences of hypertrophic or keloidal scarring or hypersensitivity, and no increased incidence of hyperpigmentation or hypopigmentation compared with Caucasian skin. The fillers provided smooth, natural looking, and long-lasting wrinkle correction and a good safety profile in persons with darker skin types	Fair
Hamilton et al, 2007 PMID:18086056	Histopathologic study of samples from two prospective, masked RCTs	USA/Patients undergoing dermal augmentation of NLFs	433	0, 6, 24 wk	Restylane Perlane	Both NLFs	NASHA administration does not elicit clinical or laboratory evidence for cellular or humoral immune responses in 98% of individuals, supporting the conclusion that Restylane and/or Perlane are not commonly immunogenic	Fair
Kono et al, 2008 PMID:18547178	Randomized, evaluator-blind study Patients served as their own control	Japan	10 (10)	3, 6, 9, 12 mo	Restylane, single cross- linked HA (SCHA) (n = 10) Puragen, double cross- linked HA (DCHA) (n = 10)	One side of each patient's glabellar lines was treated with SCHA and the other side was treated with DCHA	Both SCHA and DCHA are equally effective in producing an optimal cosmetic result. DCHA provides a more durable aesthetic improvement when compared with SCHA in the treatment of glabellar lines.	Poor



Levy et al., PMID:19207322	Prospective, double-blind RCT	France/Subjects with moderate to severe bilateral NLFs	60	None	Juvéderm Ultra 3, with and without preincorporated lidocaine; 0.62 ml	For each subject, the NLF on one side was randomly assigned to treatment with HA+lidocaine, and the opposite to treatment with HA gel alone.	The smooth cohesive HA gel with preincorporated lidocaine resulted in better comfort during NLF injection and a better injection experience than an HA gel without preincorporated lidocaine.	Good
Lindqvist et al., 2005 PMID:15622265	RCT	Norway and Sweden/ Patients with prominent NLFs	68 (43)	2, 4, 6, 9, 12 mo	Perlane (n =68) (one nasolabial fold)	Intradermal injection to the nasolabial folds	Perlane has acceptable long-term safety and offers a longer-lasting aesthetic improvement than Zyplast.	Good

**Randomized Controlled Trial (RCT): No. of studies, 25**

Lupo et al., 2008 PMID:18176233	Multicenter, double-blind, randomized, within-subject, controlled study	USA/Subjected presenting with severe NLF rated as 3 or above	87 (82)	4, 8, 12, 16, 20, 24, 48 wk	Juvéderm Ultra Plus (HA) 1.7 ml for initial treatment, 0.6 ml for repeated treatment Zyplast (bovine collagen)	Subjects randomized to treatment with Juvéderm Ultra Plus in one NLF and Zyplast in the opposite NLF. 70 (81%) of subjects returned for complimentary repeated treatment with Juvéderm Ultra Plus, performed between 24 and 36 wk	The most significant finding from the study is the extended duration of correction for Juvéderm Ultra Plus, particularly for severe folds. Given that Juvéderm outlasts the temporary dermal fillers, perhaps it should be compared to semipermeable fillers Radiesse and Sculptra.	Good
Man et al., 2008 PMID:18430173	Double-blind, comparative study Patients served as	Canada/Female patients who demonstrated dermal thinning of the dorsal hands	10 (10)	1 wk, 1, 3, 6 mo	Restylane (HA), 1.4 ml (n =10) Cosmoplast (Collagen), 2.0 ml (n =10)	Patients were randomized to received two vials to either their right or left hand. Two vials of collagen was administered into the contralateral hand.	Hyaluronic acid proved to be superior in administration and duration to collagen.	Good

Appendix A. Cont'd

Study	Design	Country/population type	Sample size	Follow-up	Treatment	Injection description	Conclusions	Grade
Moers-Carpi et al, 2007 PMID:18086052	Multicenter, blinded, randomized trial	Europe/Enrolled patients had moderate or severe NLFs	205 (192)	4, 8, 12 mo	Radiesse (CaHA), 2.21 ml total volume (n = 70) Juvéderm 24 (HA-1A), 4.78 ml total volume (n = 33) Juvéderm 24HV (HA-1B), 2.94 ml total volume (n = 33) Perlane (HA-2), 2.89 ml total volume (n = 65)	Patients treated with either CaHA gel or HA for the correction of both NLFs. Nearly all patients (n = 189) received a touch-up treatment at 4 mo.	Both CaHA gel and the HA products display adequate and comparable safety profiles. In this controlled study, CaHA gel ranked highest in patient satisfaction and likelihood to return. The material was more effective and longer lasting than each HA in maintaining NLF augmentation. The authors believe CaHA gel offers advantages in durability, patient satisfaction, and cost, for safe correction of NLFs.	Good
Moers-Carpi et al, 2008 PMID:18093199	Multicenter, prospective, randomized, controlled, split-face trial Patients served as their own control.	Germany & Spain/ Moderate to severe NLFs (3 or 4 on WSRS)	60 (58)	6, 9, 12 mo	Radiesse Restylane Volume required for correction in CaHA treated fold was 30% less than the volume of NASHA	Patients received two injections 3 mo apart. At the initial visit, patient was treated with CaHA to correct one NLF and NASHA to correct the other NLF. At the 3 mo visit, patients received a touch-up treatment in both folds.	CaHA was found to be significantly more effective than NASHA. At all time points, CaHA demonstrated longer lasting results and greater improvement than NASHA.	Good
Randomized Controlled Trial (RCT): Narins et al., 2003 PMID:12786700	Double-blind RCT	US/correction of nasolabial folds	138 (138)	2, 4, 6 mo	Restylane (n = 138) Zyplast (n = 138)	Injection of each material to contralateral nasolabial folds	Restylane provides more durable aesthetic improvement than collagen and is well tolerated	Good

Author/PMID	Study Design	Subjects	Number	Duration	Intervention	Outcomes	Conclusion
Narins et al., 2007 PMID:18086061	Randomized, multicenter within-subject (split face) noninferiority study	USA/Subjects with approximately symmetrical NLFs classified as Grade 2 or greater on MFWS	164 (149)	6 mo	Dermicol-P35 (n = 149) Restylane (NASHA) (n = 149)	NLFs Dermicol-P35: mean 1.48 ml; 72 received touch-up injections (0.59 ml) Restylane: mean 1.16 ml; 73 received touch-up injections (0.45 ml)	The effectiveness of Dermicol-P35 is maintained for at least 6 mo and is equivalent to NASHA for the correction of NLFs. Good
Narins et al., 2008 PMID:18547177	Multicenter, randomized, evaluator-blinded study Patients served as their own control	USA/Patients with moderate to severe NLFs	75 (63)	18 mo interim of a 30 mo study	Restylane Patients were then randomized to retreatment at 4.5 mo and retreatment of the other NLF at 9 mo.	All patients received an injection in both NLFs at the first visit, with touch-up injections as needed at the 2 wk follow-up visit.	Improvements seen after initial NASHA filler treatment persisted for up to 18 mo with one retreatment. The response was equivalent for retreatment at 4.5 and 9 mo. Fair
Narins et al., 2008 PMID:18547179	Randomized, within-subject (split-face), evaluator-blinded trial	USA/Clinical evidence of bilateral aging defects in the nasolabial area with wrinkles rated as 2 or greater	149	6, 9, 12 mo	Dermicol-P35 (n = 149) Restylane (HA) (n = 149)	Each NLF received one filler, one touch-up injection could be given after 2 weeks to obtain an optimal cosmetic result (OCR)	The data presented indicate that the correction of NLFs achieved with Dermicol-P35 injection is maintained for up to year. Fair
Onesti et al., 2009 PMID:19454518	Double-blind RCT Patient served as	Italy/25 to 80 yr with marked nasolabial folds	84 (68)	14 d, 2, 4, 6 mo	Puragen (n = 84) Captique (n = 84)	Depth of injection and the volume to be injected were at the operator's discretion. Each patient received Puragen in one NLF and Captique in the contralateral fold, in a	Both products used. Puragen and Captique are equally effective and safe in eliminating nasolabial folds. The biochemical and structural characteristics of Puragen enabled more long-lasting and stable results to be Fair
Pinsky et al., 2008 PMID:19083502	Double-blind, split-face RCT Patients served as their own control	USA/Subjects with fully visible NLFs	292 (280)	6, 9 mo	Juvéderm Ultra/Juvéderm Ultra Plus (n = 292) Zyplast bovine collagen (n = 292)	1.5 ml for initial treatment, 0.7 ml for repeat treatment	Juvéderm Ultra and Ultra Plus provide long-lasting clinical improvement for more than 9 months on 1 year after treatment, respectively. Therefore, individuals treated with these dermal fillers will require repeat treatments less frequently. Fair

Appendix A. Cont'd

Study	Design	Country/population type	Sample size	Follow-up	Treatment	Injection description	Conclusions	Grade
Rao et al., 2005 PMID:16416642	Randomized Controlled Trial (RCT) RCT	No. of studies, 25 USA/patients undergoing correction of nasolabial folds	8 (8)	12 wk	Restylane 0.7 ml (n =8)	Contralateral injection of each filler into the mid- or deep dermis nasolabial	Both fillers are effective for tissue augmentation of the nasolabial folds. Restylane demonstrated higher patient satisfaction.	Fair
Vartanian et al., 2005 PMID:16027343	Prospective, sequential Each patient served as his or her own control	USA/General population	12 (8)	120 d	Hylaform 1.0 ml (n =8) 1. Hyaluronidase and saline (n =12) 2. Three different doses of hyaluronidase	Hyaluronidase injected in cutaneous areas previously injected with HA (Restylane).	Intradermal hyaluronidase injections can be used to reduce dermal augmentation from previously injected Restylane. A small dose of hyaluronidase (5 to 10 U) may be injected initially. The dermal filler formulated with lidocaine is effective in reducing procedural pain during correction of facial wrinkles and folds while maintaining a similar safety and effectiveness profile to the filler without	Good
Weinkle et al., 2009 PMID:19735519	RCT	US/Patients undergoing injections to the nasolabial folds	72 (72)	2 wks	Juvéderm (JUV) 1.6 ml (max) (n =72) Juvéderm + lidocaine (JUV+L) 1.6 ml (max) (n =72)	Injection of JUV and JUV+L to contralateral nasolabial folds	The predominant localization of injected HA filler is within the subcutis. A relatively thick NLF dermal thickness (<1.50 mm) likely precludes accurate injection of filler into dermal collagen. The results suggest that dermal localization of HA filler products is not required for an excellent cosmetic	Fair
Arlette et al., 2008 PMID:18547183	Prospective, non-randomized, partially blinded	Canada/Subjects undergoing Mohs micrographic surgery for basal cell carcinoma of the NLF area	16	Not reported	Juvéderm	NLF	The predominant localization of injected HA filler is within the subcutis. A relatively thick NLF dermal thickness (<1.50 mm) likely precludes accurate injection of filler into dermal collagen. The results suggest that dermal localization of HA filler products is not required for an excellent cosmetic	Poor

Bugge et al., 2007 PMID:17944679	Uncontrolled clinical trial	Norway/ HIV-infected patients older than 18 yr of age with severe nasogenian atrophy	20 (19)	52 wk	Restylane SubQ 1.5-2.0 mL in each cheek 13 patients also received a touch-up treatment of Restylane SubQ 1.0 mL at wk 4	Patients received an injection in each cheek in the nasogenian area. All injections were performed by the same plastic surgeon at an outpatient clinic.	Restylane SubQ is a useful and welltolerated dermal filler for treating HIV positive patients with facial lipoatrophy.	Poor	
Uncontrolled Clinical Trial Number of studies: 13									
Carruthers et al. 2005 PMID:15841626	Clinical Trial	Canada/non-pregnant, non-breastfeeding women aged 25-60 yrs with prominent downturned mouth corners	15 (14)	1 week 3, 4, 5, and 6 mo	Restylane 0.44 ml (avg upper lip) and 1.49 ml (avg lower lip)	Serial puncture using a "push ahead" technique across the lateral part of the upper and lower lip plus intradermal extension from each lateral commissure	Restylane is safe and effective as a soft tissue-augmenting agent	Poor	
DeLorenzi et al., Subcutaneous and/or 2006 PMID:16442040	Clinical Trial	Canada/patients seeking chin and/or cheek augmentation with no aesthetic facial surgery in the past 12 months	57	1, 3, 6, 9, 12 mo	Restylane 10.0 mL (maximum) Average injection of 2.2 mL (cheek) and 2.1 mL (chin)	Subcutaneous and/ or suprapariosteal injections	Restylane is well tolerated and maintains aesthetic correction of the cheeks and PM: 16442040 chin for at least 3 mo after treatment	Poor	
DeLorenzi et al. 2009 PM:19207320	Prospective, openlabel study	Canada/General population	57	1, 3, 6, 9, 12 mo	Restylane SubQ. Mean volumes injected into each cheek was 2.1 mL, and into each chin 2.2 mL.	98 cheeks, and 16 chins. Thirteen patients received touch-up injections at 20 sites.	The findings of this study indicate that large-particle stabilized hyaluronic acidbased gel provides relatively long-lasting esthetic correction of the cheeks and chin. Overall, this product appears to be well tolerated, and this study raised no major safety concerns.	Poor	

Appendix A. Cont'd

Study	Design	Country/population type	Sample size	Follow-up	Treatment	Injection description	Conclusions	Grade
Denton et al., 2007 PMID:17418252	Prospective, observational clinical study	Canada/HIV-positive males with facial lipoatrophy, mean age=47.2yrs	18 (14)	12 mo	Perlane, 2.1 ml per side of the face	Nasolabial folds, submalar region	The authors' state that their findings indicate that Perlane is a feasible option for correction of facial lipoatrophy. The procedure was well tolerated without any long-term sequelae observed. Patients achieved a significant improvement in appearance lasting from up to 1 year.	Poor
Duranti et al., 1998 PMID:9865196	Clinical Trial	Italy/patients undergoing augmentation therapy for wrinkles	158 (158)	1, 2, 4, 8 mo	Restylane 1.4 ml (avg)	Injection to the middermis of the glabella, nasolabial folds, oral commissure, and/or lips	Hyaluronic acid gel is well tolerated and effective for soft tissue augmentation of the face	Poor
Han et al., 2006 PMID:16508353	Clinical Trial	Korea/ patients undergoing augmentation rhinoplasty	11 (6)	12 mo	Cultured human fibroblasts suspended in Restylane 0.6-1.0 ml	Injection into the subcutaneous layer of the nasal dorsum	Restylane with suspended cultured human fibroblasts has the potential to be used as a long-lasting injectable soft- tissue	Poor
Judodihardjo et al. 2008 PMID:18547174	Open uncontrolled clinical trial	UK/General population	25 (22)	24 hr, 4 wk, 12 wk	Teosyal (hyaluronic acid) ~0.83 ml per nasolabial fold	Single injection into each nasolabial fold	The measurements obtained by the erythema meter and the infrared thermometer correlated well with subjective clinical scores. The erythema meter and infrared thermometer are effective tools to objectively measure mild inflammation post hyaluronic acid injection.	Poor
<u>Uncontrolled Clinical Trial</u> Kerscher et al., 2008 PMID:18384619	Number of studies: 13 Single-center, prospective, uncontrolled clinical trial	Germany/Skin types I-IV, sagging/slackening facial skin, actinic elastosis, loss of skin elasticity, >30 y	20 (19)	4, 8, 12, 24 wk	Restylane, 1.0 ml	Eligible patients received bilateral injections of HA in the lower part of the cheeks in three sessions (start, 4, 8 wk)	The study suggests that micropuncture injections of NASHA are well tolerated and can improve dermal elasticity and reduce skin surface roughness.	Poor

Lowe et al. 2006 PMID:16875468	Clinical Trial	US and UK/ patients requesting augmentation of the upper cheek or chin contour	72 (72)	64 wk	Restylane SubQ 3.9 mL	Serial puncture technique, approximately 50 0.02 ml injections per session Percutaneous injection. Slowly injected with palpation. 5-8 injection tunnels created with deposition.	Restylane SubQ is a useful injectable agent to augment and lift upper cheeks and recontour chins.	Poor
Olenius 1998 PMID:9502839	Clinical Trial	Sweden/ patients undergoing soft tissue augmentation for facial wrinkles	113 (100)	1, 2, 12, 26 wk	Restylane	Nasolabial folds, glabellar lines, mouth angle wrinkles, generic facial lines	Restylane fulfilled the expectations of giving safe and effective tissue augmentation	Poor
Reuther et al., 2009 PMID:19730872	Single-centered, prospective, open-label clinical trial	Germany/healthy women aged 30 yr or older with loss of skin elasticity	19	16 wk	Restylane Vital (NASHA), 1.0ml at each of 3 treatment sessions	bilateral injections in lower part of the facial cheeks	Treatment of facial skin with NASHA has an impact on the intrinsic viscoelastic properties of the skin. The present results from this study indicate that NASHA can improve the skin's viscoelastic behavior both by tightening the skin and by improving the recoil capacities, making it very interesting as a rejuvenation approach. Further in vivo studies, ideally involving a control group, in addition to evidence at the molecular level, are required to confirm these results and elucidate a possible mechanism of action.	Poor

Appendix A. Cont'd

Study	Design	Country/population type	Sample size	Follow-up	Treatment	Injection description	Conclusions	Grade
Cohort Study Distante et al, 2009 PMID:19207331	Number of studies: 4 Prospective, open, single-center, noncomparative study	Italy/Healthy women with mild to moderate brachial ptosis	16	90 d	Restylane Vital, 1 ml per session per arm	Arm  Three sessions at intervals of 30 d (T0, T30, T60). Follow-up occurred at T90.	Treatment with NASHA can improve the biophysical properties and appearance of the skin.	Poor
McCracken et al, 2006 PMID:16714927	Retrospective cohort	US/patients at 9 American Society of Ophthalmic Plastic and Reconstructive Surgery practices	286 (286)	N/A	Restylane  Nasolabial folds 0.8ml (n=234)  Melolabial folds 0.5ml (n=54)  Vermillion border 0.5ml (n=198)  Lip volume enhancement 0.6ml (n=144)	Various facial locations: Techniques, volume, end points, and anesthesia vary for different facial areas between practices but overall satisfaction is high.	Poor	
Raspaldo 2008 PMID:18788032	Retrospective record analysis	France/Patients presenting with hollow sub-palpebral grooves, malar descent, flat cheekbones, hollow temporal areas, scar depression or chin retrusion.	102	6-18 mo	Glabella folds 0.3ml (n=18) Juvéderm Voluma, volume injected based on baseline volume loss score	Midface region: submalar/subpalpebral area (central midface) and malar area (lateral midface)	Voluma provides aesthetic improvements according to investigator and patient assessment for up to 18 mo post-treatment.	Poor
Wahl 2008 PMID:19146607	Cohort study	16 European countries/Patients injected with a resorbable dermal filler in the previous 18 mo	3566	Not reported	Hyaluronic acid filler incorporating lidocaine HAL), Mean 1.1 ml	NLF region	The new hyaluronic acid filler incorporating lidocaine provides a more comfortable injection experience and improved aesthetic result for most patients compared with other dermal fillers used previously.	Poor



Cross-sectional Study	Number of studies: 1	France/patients receiving non-animal stabilized hyaluronic acid (NASHA) injections	4320	N/A	Restylane Perlane	Various	NASHA is a useful product with limited adverse reactions reported over an extended period of time. Only one adverse reaction lasted longer than one year.	Poor
Andre 2004 PMID:15196154	Retrospective cross sectional							
Case Series/Report	Number of studies: 39	USA/62 yr old female	1	10 mo since treatment; 6 mos following removal of nodule	Restylane	Mandible region	The finding of a foreign body giant cell reaction in facial lesions should prompt further questions about the use of injectable fillers in the area as history of their use may not be offered initially.	Poor
Al-Shraim et al. 2007 PM:17761744	Case report							
Anwar et al. 2007 PM:17549561	Retrospective case report	UK/41yr old white woman	1	36 mo	DermaLive (60% hyaluronic acid)	Injections for nasolabial wrinkles	The authors believe this to be the third case report of facial granulomas after DermaLive injections.	Poor
Arron et al., PMID:17760694	Case report	Treatment occurred in Hungary/59yo Caucasian woman	1	1yr	Matridur and Matrigel (non-animal-stabilized Hyaluronic acid)	Melolabial folds, glabella, lips, and perioral rhytids	The variety of reported adverse reactions to NASHAs suggests divergent etiologies. A better understanding of the components of various hyaluronic acid filler products may help to clarify these issues.	Poor
Bardazzi et al., 2007 PMID:17365268	Retrospective case report	Italy/54 year old woman	1	2 yr, 2 mo	Restylane	Melolabial folds	Considering the possible side effects with introducing a foreign substance into the skin, it is crucial that both the patient and the physician recognize the risk of these products, and the patient should be informed about the possible adverse reactions from using an	Poor

Appendix A. Cont'd

Study	Design	Country/population type	Sample size	Follow-up	Treatment	Injection description	Conclusions	Grade
Bosniak et al., 2004 PMID:15545531	Retrospective case series	Brazil/patients undergoing lip augmentation and facial rhytid ablation	1446	24 hr; 1 & 2 wk; 3, 6, 9 mo	Restalyne 1.4 cm <sup>3</sup> (max)  Glabellar area (n = 185)  Nasolabial folds (n = 1020)  Oral commissure (n = 352)  Lips (n = 685)	Injected superficial to the middle dermal layer with the needle inserted bevel up. For linear depressions, serial punctures were combined with a linear threading technique. For broader depressions, fanning or cross-hatching techniques were used, supplemented with serial punctures. Injections to the glabellar area, nasolabial folds, oral commissure, and lips	The duration of the NASHA filling effect combined with the lack of substantial complications or skin pretesting makes NASHA an effective alternative to other temporary injectable fillers.	Poor
de Lacerda et al. 2007 PMID:18086060	Case report	Brazil/2 females, aged 24 and 52yo		Case 1 - 1 yr Case 2 - 4mos	Case 1 - Evolence (porcine collagen), 2ml Case 2 - Voluma (Hyaluronic acid), 2ml	Case 1 - nose, nasolabial folds, and lips Case 2 - nose, nasolabial folds, and lips	Filler rhinoplasty represents an excellent alternative for patients who do not wish to undergo surgery. It is a minimally invasive and cost-effective office procedure.	Poor
Descamps et al. 2008 PMID:18446029	Case reports	France/patients with chronic hepatitis C treated with alpha- interferon	2	Case 1 - 5 yr post treatment Case 2 - 2 years post- treatment	Case 1 - unknown permanent dermafiller Case 2 - hyaluronic acid	Case 1 - mesolabial and nasolabial folds Case 2 - peribuccal and lion's wrinkles	The authors state that patients with sarcoidosis and patients infected with HCV should be aware of the risk of foreign body granulomas and be excluded from any filler injections. The authors also feel that a blood test for HCV should be undertaken before injection a derma filler.	Poor

Douse-Dean et al. 2008 PMID:18380210	Case report	USA/females between 43-50 yr old	3	2wks-1yr	Case 1 - hyaluronic acid Case 2 - hyaluronic acid Case 3 - hyaluronic acid	Case 1 - melolabial fold rhytides Case 2 - marionette lines Case 3 - vermillion border	Bluish grey effect known as Tyndall effect and can usually be avoided if the dermal filler is injected at the correct	Poor
Fernandez- Acenero et al., 2003 PMID:14725668	Retrospective case report	Spain/48 yr old woman	1	2 mo	Restylane	Injection of Restylane in upper lip	Another case of granulomatous foreign body reaction against HA; this risk should be explained to the patient before treatment.	Poor
Fezza 2008 PMID:18317150	Case series	USA/ Caucasian, fair- skin patients with lower eyelid cicatricial ectropion	15 (n =7) female, (n =8 male)	1 yr	Restylane, 1cc	Eyelid	Hyaluronic acid filler injections can successfully treat cicatricial ectropion by creating an anterior tissue expander effect and may allow patients to avoid surgery. The filler can provide correction for longer than 1 year and can be fully reversible with the injection of hyaluronidase. The treatment is quick and in this anecdotal series was noted to be safe and effective.	Poor
Friedman et al., 2002 PMID:12081677	Retrospective case series	Europe, Canada, Australia, South America, Asia/ adverse events to nonanimal stabilized hyaluronic acid	406,000	NA	Restylane, Perlane, Restylane Fine Lines	Not reported	Hypersensitivity is the major adverse event but appears to be declining perhaps in response to a higher level of purity in the product	Poor
Case Series/Report Furmanczyk et al. 2009 PMID:19207330	Number of studies: 39 Case Report	US and Thailand/58yo male	1 (1)	4 and 8 week intervals	Dermalive	Not Reported	The authors indicate the suggested treatment for Dermalive granulomas is intralesional steroid injections, as was seen with the patient presented in this report.	Poor

Appendix A. Cont'd

Study	Design	Country/population type	Sample size	Follow-up	Treatment	Injection description	Conclusions	Grade
Ghislanzoni et al. 2006 PMID:16536824	Retrospective case report	Italy/41 yr old woman	1	5 wk-3 mo	Restalyne (hyaluronic acid)	27-gauge needle longitudinal injection to the melolabial, glabellar, and periorbital wrinkles.	The cause of late inflammation or granuloma formation in some patients after injection of HA is not yet known, but whatever it may be, HA Restylane cannot be considered innocuous and patients should be informed of these possible complications.	Poor
Godin et al 2006 PM:16549735	Prospective Case Series	US/patients undergoing facial augmentation	101 (61)	110 mo	Radiesse n= 72 Radiesse and Restylane n=29	Injection to the nasolabial folds, upper and lower lip vermilion borders, "lipstick lines" and perioral lines	Combination group tended to have greater intermediate and overall satisfaction scores than the Radiesse alone group.	Poor
Goldberg et al., 2006 PMID:16985414	Retrospective case series	USA/155 patients; (n =41 males and n=114 females with avg age of 53yr)	155 (121)	6-12 mo	Restylane, mean injections were: 0.96ml at 1st injection 0.87ml at 2nd injection 0.78ml at 3rd injection	Orbital rim, zygomatic and septal confluence hollows in the tissue plane deep to the orbicularis oculi muscle	The anatomy of the periorbital area is tricky, but with practice, patience, and finesse in laying down the layers of gel, satisfactorily smooth contours can be created. Complications including bruising, irregular or lumpy contour, bluish or dark color, and fluid accumulation can occur. The authors' found that in most cases, these were not sufficiently severe to limit patient acceptance. Although the authors' recognize the limitation that 22 patients in the study had no follow-up, the anecdotal data suggest that the majority of patients are satisfied with the improvement.	Poor

Hirsch et al., 2007 PMID:17373195	Retrospective case report	US/43 yr old woman	1	2 wk	Juvéderm	Multiple deep dermal injections along the nasolabial folds using a linear threading technique	This case provides incentive to eliminate unsupervised injections of filling agents by unqualified paramedical personnel with limited training. The authors also speculate that hyaluronidase may have been effective at treating this patient by decreasing the volume of the hyaluronic acid.	Poor
<u>Case Series/Report</u> Jacomo 2008 PMID:18209119	Number of studies: 39 Case series	USA/consecutive patients preseting to a facial plastic and reconstructive surgery practice for injectable lip augmentation	66 patients receiving 137 treatments	9 mos	Restylane	Vermilion, subvermilion, peristomal, philtral column, and oral commissure  Authors indicate new classification of lip anatomical zones for directing injection	Using new classification of lip anatomical zones to direct the injection of a non-animal-source stabilized hyaluronic acid has increased the author's ability to better control lip shape and size in lip augmentation. This technique was met with high patient satisfaction and no adverse effects. Persistence of injected nonanimal- sources stabilized hyaluronic acid was similar to that seen in other studies.	Poor
Jham et al., PMID:19138600	Case reports and comprehensive literature review	Various/General population	56		Various	Upper/lower lip, NLF, cheek		Poor
Jordan 2005 PMID:16234715	Number of studies: 39							Poor
<u>Case Series/Report</u> Kanchwala et al. 2005 PM:15985788	Retrospective Case Series	US/patients undergoing facial augmentation	976	3, 6, 9, 12	Autologous fat n=697 Hylaform n=52 Restylane n=86 Radiesse n=141	Nasolabial folds, lips, glabella	Successful fat transplantation appears to be the preferred method for the treatment of volume loss to the face.	Poor

Appendix A. Cont'd

Study	Design	Country/population type	Sample size	Follow-up	Treatment	Injection description	Conclusions	Grade
Kane 2005 PMID:16151656	Retrospective Case Series	USA/24 women aged 35-56	24	10 d	0.1-0.45 ml Restylane (n =23) 0.1-0.45 ml Hylaform (n =1)	30/32-gauge injection of Restylane in the lower eyelid	The author states that correction of tear trough deformity with Restylane is a compromise solution that does not fix the root cause of the problem, but it can improve its appearance without	Poor
Lennox et al., 2007 PMID:17966181	Case report	USA/ 46 yr old female presented for evaluation of cosmetic issues following mastectomy and silicone implant reconstruction	1	4 wk	Juvéderm Ultra, 0.4ml into each nipple in each of 2 treatment sessions	nipples	Despite the advent of numerous techniques used to restore the nipple areola complex, nipple projection has remained unsatisfactory. In this case, the immediate results of using hyaluronic acid filler was exceptionally gratifying to the patient. It would be worthwhile for a large scale clinical trial to evaluate the impact of hyalurons in postmastectomy patients to determine change in self-appearance and self-esteem.	Poor
Lowe et al. 2007 PM:17852625	Case report	US/ 32-yr-old female with mildly atrophic upper lip and melomental folds	1 (1)	1 hr following treatment	Restylane 1.5 cc	Filler was injected in the upper lip and melomental area after 1% Xylocaine nerve block was given for anaesthesia	The 3D photography imagery has potential for analyzing the change of volume both for different parts of the face, including the lips in this instance.	Poor
Malhotra 2007 PMID:1807111	Retrospective case series	USA/patients from 18-36 yr old	5	6-9 mo	Restylane Sub-Q (hyaluronic acid), 2ml each at 2 treatments	Intraconal and extraconal posterior orbit	The authors state that this small case series suggests the safety and tolerability of Sub-Q into the intraconal and extraconal orbital cavity.	Poor

Nyte 2007 PMID:17580805	Case report	USA/50 yr old male presented with long history of nasal obstruction	1	2 d	Restylane, 0.15ml	Caudal-medial surface of the upper lateral cartilage of the nasal valve  Upper lateral cartilage of the nasal valve	The authors states that spreader graft injection appears to be a viable, nonsurgical option for relieving nasal obstruction secondary to internal nasal valve collapse.	Poor
<u>Case Series/Report</u> Oduze et al., 2007 PMID:18090767	Number of studies: 39 Retrospective case series	USA/patients with average age of 56yrs	60 (n=45 Fitzpatrick I-III, (n =20 Fitzpatrick IV-VI)	6-9 mo	Restylane	Injections to the dermal-epidermal junction of the nasolabial folds, forehead, glabella, marionette lines, and scars using serial threading; serial puncture used at tear trough, cheek, and oral commissure	This study demonstrates the idea that with proper and meticulous injection techniques, patients with Fitzpatrick skin types IV-VI can experience the same benefits of Restylane therapy as their lighter-complected counterparts.	Poor
Parada et al., 2005 PMID:16276149	Histologic preparations from 11 biopsies collected over a two year period.	Brazil	11	Not reported	Restalyne (hyaluronic acid), Metacril (polymethylmethacrylate), Aquamid (polyacrylamide), New-Fill (polylactic acid), Artecoll (polymethylmethacrylate suspended in a collagen solution).	Biopsies fixed in 10% formalin.	The authors postulate that increasing numbers of "bizarre foreign body-type granulomatous reactions in the oral facial regions of middle-aged women" are due to injections with one or more of these fillers.	Poor
Patel et al. 2006 PM:16651928	Retrospective case report	US/65 yr old woman	1	1 yr	0.7 ml syringe Restylane	30-gauge injections in the nasolabial folds, lips, and perioral rhytides	Patient developed a hypersensitivity reaction even though she had a negative test before treatment. The reaction may have been from the repeated use, so the authors question the usefulness of skin testing.	Poor
Peter et al., PMID:16764658	Retrospective case report	Germany/48 yr old man	1	18 mo	Restylane	Glabellar area and the cheeks	Even small amounts of embolic material can cause damage to the retina. This case should be a warning that widely performed and simple procedures can have serious complications.	Poor

Appendix A. Cont'd

Study	Design	Country/population type	Sample size	Follow-up	Treatment	Injection description	Conclusions	Grade
Requena et al., 2001 PMID:11391099	Retrospective case series	Spain/52 yr old man, 42 yr old woman, 2 38 yr old women	4	6-14 mo	Artecoll (n = 1) Dermalive (n = 1) Silicone (n = 2)	Artecoll: nasolabial and forehead folds Dermalive: forehead and periocular ridges Silicone: nasolabial folds, cheeks	Artecoll and Dermalive are able to stimulate a clinically evident granulomatous reaction in rare cases, even though they are composed of mostly inert materials. Silicone, contrary to popular opinion, is beneficial and safe when it is used properly in small amounts for cutaneous soft tissue	Poor
Case Series/Report Rosner et al., 2009 PMID:19207327	Number of studies: 39 Retrospective case series using Berlin registry data on adverse reactions to injectable fillers	Germany/Patients treated with a methacrylate based filler who developed a reaction in the same area	34	N/A	Dermalive (hydroxyethylmethacrylate and ethylmethacrylate in a fixed combination with hyaluronic acid)	Fillers injected in 95 areas among the 34 patients. Common areas: NLFs (46.3%) Corners of the mouth (17.9%) Glabella (17.9%) Upper lip (12.6%)	Dermalive is a long-lasting injectable filler with a biodegradable part (HA) and a nonbiodegradable part (methacrylate). Although these ingredients are widely accepted as compatible substances, the study was able to show a large number of patients developing adverse	Poor
Schweiger et al., 2008 PMID:18318726	Case report	USA/ 21 yr old female born with cleft lip, had received 12 reconstructive procedures by craniofacial surgeons; complained of lip asymmetry	1	Approximately 4 mo	Restylane, 0.7ml	upper lip	The authors believe this is the first reported case using hyaluronic acid to treat lip asymmetry in a patient with cleft lip, with successful results. The authors conclude that injectable soft tissue fillers, especially hyaluronic acid, may provide a minimally invasive method for cosmetic enhancement in patients with cleft lip who desires further aesthetic improvement after surgical	Poor



Sidwell et al., 2004 PMID:15550141	Retrospective case report	UK/40 yr old white female	1	8, 12 mo	Dermalive (synthetic hyaluronic acid and acrylic hyrdogel)	Injections of Dermalive to the nasolabial folds	The authors point out that hyaluronic acid are considered medical devices, not drugs, and as such are scrutinized less by the FDA (Dermalive is not yet approved). They advocate more comprehensive human testing prior to approval of new skin fillers.	Poor
Soparkar et al., 2005 PMID:15778672	Retrospective case report	US/62 yr old woman	1	7 d, 17 d, 5 mo	2 0.7 ml syringes Restylane	Nasolabial folds	The authors are confused as to the cause—the two syringes were from the same lot, and one was problematic while the other was not.	Poor
Taban et al., 2009 PM:19617780	Case Series/Reports	US/Infants with congenital eyelid malpositions	5 (5)	Mean follow up 11.8 mo	Restylane 0.5 mL per eyelid	Hyaluronic acid gel was injected in small amounts across the length of the upper or lower eyelid	Hyaluronic acid gel shows promise as a novel, quick, safe, effective, predictable, non-surgical means to manage a variety of eyelid malpositions.	Poor
Vargas-Machuca et al., 2006 PMID:16625084	Retrospective case report	Spain/50 yr old woman	1	1 yr 2 mo	Dermalive	Perioral skin	Patients often do not know the filler injected and it is difficult to obtain such information from practitioners; this makes histopathologic study	Poor
Case Series/Report Wolfram et al., 2006 PMID:17135735	Number of studies: 39 Retrospective case series	Austria/2.58 yr old women, 1.53 yr old woman	3	3 mo - 2 yr	Newfill, Restylane, Dermalive	Zygomatic arch, eyelids, forehead, nasolabial folds, cheeks	Given the increasing use of fillers, it might be worth considering removing them from the list of medical items and including them in a category with more stringent investigation.	Poor

Appendix A. Cont'd

Study	Design	Country/population type	Sample size	Follow-up	Treatment	Injection description	Conclusions	Grade
<b>Collagen Fillers</b>								
<b>Randomized Controlled Trial (RCT): No. of studies, 13</b>								
Baumann et al. 2007 PM:18086050	Multicenter, double-masked, randomized, within-subject study	USA/Subjects at least 30 yr and with fully visible bilateral NLFs that were approximately symmetrical (both moderate or both severe).	439 (423)	24 wk	HA: Juvéderm 30 (J30), Juvéderm Ultra (24HV), Juvéderm Ultra Plus (30HV) median 1.6 ml (0.8-5.6 ml)  Zyplast (cross-linked bovine collagen)	Subjects were randomly assigned to receive one of the three smooth-gel HA fillers, intradermally to the NLF on one side of the face. In all subjects, the NLF on the other side of the face was treated with Zyplast.	All the HA dermal fillers resulted in a mean improvement (i.e., a reduction) from baseline in NLF severity score, clinically significant at each time point. Further, the HA dermal fillers provided longer-lasting clinical correction that bovine collagen.	Good
Cohen et al. 2004 PM:15468406	RCT	US/patients at least 18 years of age presenting for glabellar, nasolabial folds, radial upper lip lines, marionette lines correction	251 (251) (111 at 12	1, 3, 6, 12 mo	Artecoll n=128 Zyderm II or Zyplast n=123	Vast majority of subjects had only one treatment visit.	The new smooth-gel HA dermal fillers were highly effective in correcting NLFs for 6 mo or longer after treatment. The majority of subjects achieved optimal correction with only a single injection of the HA dermal filler, and the fillers were also similarly well tolerated. An overwhelming majority of subjects expressed a preference for the smooth-gel HA dermal fillers over bovine collagen.	Good
						Tunneling technique: labella, nasolabial folds, radial upper lip lines, marionette lines	Study demonstrated the relative safety and effectiveness of Artecoll relative to that of collagen	

Cohen et al. 2006 PM:16936546	RCT (double-blind)	US/patients with wrinkles of the glabella, nasolabial folds, radial upper lip lines, and corners of the mouth; treated with PMMA filler in pivotal RCT (Cohen 2004)	251 (233) (69.4 to 5 year)	1, 3, 6, 12 mo 4-5 years	ArteFill (amount not specified) n=128 Collagen (amount not specified) n=123	Injection at the glabella, nasolabial folds, radial upper lip lines, or corners of the mouth	Study demonstrated the overall safety and effectiveness of ArteFill relative to a collagen control. Effectiveness was demonstrated for all areas treated.	Good
<b>Randomized Controlled Trial (RCT):</b> Number of studies, 13								
Grimes et al. 2009 PM:19735512	Study 1: double-blind, randomized clinical trial Study 2: open-label, randomized clinical trial	USA/patients with Fitzpatrick skin types IV, V, or VI	Study 1: 160 Study 2: 119	24 wk	Study 1: Juvéderm Ultra, Ultra Plus, and 30 and Zyplast collagen Study 2: Hylaform, Hylaform Plus, and Captique	Nasolabial folds	The HA fillers were effective and well tolerated in skin of color, with no occurrences of hypertrophic or keloidal scarring or hypersensitivity, and no increased incidence of hyperpigmentation or hypopigmentation compared to Caucasian skin. The fillers provided smooth, natural-looking, and long-lasting wrinkle correction and a good safety profile in persons with	Fair
Lindqvist et al. 2005 PM:15622265	RCT	Norway and Sweden/ Patients with prominent nasolabial folds	68 (43)	2, 4, 6, 9, 12 mo	Perlane n=68 (one nasolabial fold) Zyplast n=68 (contralateral)	Intradermal injection to the nasolabial folds	Perlane has acceptable long-term safety and offers a longer-lasting aesthetic improvement than Zyplast	Good
Lupo et al. 2008 PM:18176233	Multicenter, double-blind, randomized, within-subject, controlled study	USA/Subjected presenting with severe NLF rated as 3 or above	87 (82)	4, 8, 12, 16, 20, 24, 48 wk	Juvéderm Ultra Plus (HA) 1.7 ml for initial treatment, 0.6 ml for repeated treatment	Subjects randomized to treatment with Juvéderm Ultra Plus in one NLF and Zyplast in the opposite NLF. 70 (81%) of subjects returned for complimentary repeated treatment with Juvéderm Ultra Plus, performed between 24 and 36 wk	The most significant finding from the study is the extended duration of correction for Juvéderm Ultra Plus, particularly for severe folds. Given that Juvéderm outlasts the temporary dermal fillers, perhaps it should be compared to semipermeable fillers Radiess and Sculptra.	Good

Appendix A. Cont'd

Study	Design	Country/population type	Sample size	Follow-up	Treatment	Injection description	Conclusions	Grade
Man et al.2008 PM:18430173	Double-blind, comparative study Patients served as	Canada/Female patients who demonstrated dermal thinning of the dorsal hands	10 (10)	1 wk, 1, 3, 6 mo	Restylane (HA), 1.4 ml n=10 Cosmoplast (Collagen), 2.0 ml n=10	Patients were randomized to received two vials to either their right or left hand. Two vials of collagen was administered into the contralateral hand.	Hyaluronic acid proved to be superior in administration and duration to collagen.	Good
Monstrey et al.2007 PM:17572579	blinded, randomized clinical trial	Belgium and Israel/ patients with clinical evidence of bilateral aging defects in the nasolabial area	12	18 mo	Evolvece, 1.72ml Zyplast, 1.72ml	nasolabial folds	The results of this clinical study suggest that Evolvece could provide a substantially improved alternative to the existing treatment available. The results of this study must be confirmed in future clinical studies.	Good
<b>Randomized Controlled Trial (RCT): Number of Studies: 13</b>								
Narins et al.2003 PM:12786700	Double-blind RCT	US/correction of nasolabial folds	138 (138)	2, 4, 6 mo	Restylane (n= 138) Zyplast (n= 138)	Injection of each material to contralateral nasolabial folds	Restylane provides more durable aesthetic improvement than collagen and is well tolerated	Good
Narins et al.2008 PM:18547179	Randomized, within subject (split-face), evaluator-blinded trial	USA/Clinical evidence of bilateral aging defects in the nasolabial area with wrinkles rated as 2 or greater	149	6, 9, 12 mo	Dermicol-P35 (n= 149) Restylane (HA) (n=149)	Each NLF received one filler, one touch-up injection could be given after 2 weeks to obtain an optimal cosmetic result (OCR)	The data presented indicate that the correction of NLFs achieved with Dermicol-P35 injection is maintained for up to year.	Fair
Sciafani et al.2001 PM:11368660	RCT	US/patients not allergic to bovine collagen	10 (10)	1, 3, 6, 9, 12 mo	AlloDerm 5.0 mm (n=10)  Zyplast 0.5 ml (n=10)	AlloDerm placed surgically in a subdermal plane in one postauricular crease  Zyplast injected in a subdermal plane in the opposite postauricular crease	AlloDerm are stable as soft tissue fillers and are superior to Zyplast with regards to reabsorption	Good

Sciafani et al. 2002 PM:12437432	RCT	US/patients with age-related changes in the size and contour of the lip	44 (44)	3, 6, 9, 12 mo	Cymetra (n= 19) Zyplast (n= 25)	Injection to the upper lip between the orbicularis oris muscle and the overlying mucocutaneous junction of the upper lip	Cymetra increases the upper lip bulk, vermillion, and lower lip projection	Good
Smith et al. 2007 PM:18086048	Randomized, evaluator-blinded, bilateral, prospective comparison	USA/Potential subjects were required to have symmetric, moderate-to-deep NLFs	117 (113)	1, 3, 6 mo	Radiesse (Collagen) Cosmoplast (CaHA)	Each side was treated until, in the judgment of the investigator, an optimal result was achieved. At 2 wk following treatment, subjects could receive touch-up injections at the discretion of the physician. Occurred at 2 wk intervals, maximum of two additional treatment sessions.	The CaHA-based product gives significantly longer lasting correction of NLFs compared to human collagen. Fewer injections and less total material are required. The adverse event profiles of the two fillers are similar.	Good
<p><b>Collagen Fillers</b></p> <p><b>Controlled Clinical Trial Number of studies: 2</b></p>								
Sciafani et al. 2000 PM:10925424	Controlled Clinical Trial	US/ patients undergoing facial aesthetic surgery with skin excision	5 (3)	2, 4, 12 wk	Autologen 0.5 ml n=5 Zyplast 0.5 ml n=5	Two injections of each material contralaterally to the postauricular area	Autologous collagen dispersion may be a viable alternative to bovine collagen	Poor
Sciafani et al. 2002 PM:12187346	Controlled clinical trial	US/healthy adults	20 (17)	4 and 12 wk	Dermalogen 0.1 ml n = 20 Zyplast 0.1 ml n = 20	Injection behind the contralateral ear	Dermalogen is safe, easily administered, and well tolerated similarly to Zyplast	Fair

Qualifying subjects received CaHA product on one side, and the HC product on the other.

Appendix A. Cont'd

Study	Design	Country/population type	Sample size	Follow-up	Treatment	Injection description	Conclusions	Grade
<b>Uncontrolled Clinical Trial Number of studies: 2</b>								
Shoshani et al. 2007 PM:18086053	Single-center open-label, uncontrolled study to examine the potential of Evolence implant to elicit allergic reactions	USA/General population	530	30 min, 72 hr, 30 d	Evolence, 0.1 ml	Enrolled subjects received an intradermal injection in the left forearm, and a second injection in the right forearm after 2 wk	Due to a low potential for hypersensitivity, Evolence intradermal skin testing does not appear to be necessary, as it is comparable to that of other dermal fillers that can be used safely and effectively without a	Poor
<b>Cohort Study Number of studies: 1</b>								
Bouille et al. 2009 PM:19288692	Open, multicenter, retrospective data collection study	Belgium, Sweden/ Patients who had undergone Dermicol-P35 30G lip injections	Safety: 57 Efficacy: 51	4-10 mo	Dermicol-P35 30G	Data collected from patients to enhance or restore the contour of the upper and/or lower lip in either the vermilion border, the body of the lip, or both.	These retrospective study results support Dermicol-P35 30G as a safe and effective treatment.	Poor
<b>Case Series/Report Number of studies: 17</b>								
Braun et al. 2008 PM:1856159	Prospective case series	USA/female patients presented to clinic for lip enhancement or augmentation	20	1 yr	Evolence, 1.0 ml	Body of lip, massage technique used immediately after injection	With regards to Evolence, it is the author's experience that it should not be injected into the lips, as Evolence has far too high an incidence of undesirable nodule formation. Colbar Lifescience should update and clarify the product information for Evolence for the benefit of physicians and patients.	Poor
de Lacerda et al. 2007 PM:18086060	Case report	Brazil/2 females, aged 45 and 52yo	2	Case 1 - 1 yr Case 2 - 4mos	Case 1 - Evolence (porcine collagen), 2ml Case 2 - Voluma (Hyaluronic acid), 2ml	Case 1 - nose, nasolabial folds, and lips Case 2 - nose, nasolabial folds, and lips	Filler rhinoplasty represents an excellent alternative for patients who do not wish to undergo surgery. It is a minimally invasive and cost-effective office procedure.	Poor

Fischer et al. 2007 PM:17438184	Retrospective case report	Germany/48 yr old woman	1	10 yr	Artecoll	Injections in the upper and lower lips, nasolabial grooves, and glabella	This report shows the potential long-term risks; the risk of severe interaction with interferon or other immunostimulatory medications should be included in the consent form for injectable aesthetic microimplants.	Poor
Hopkins et al. 2009 PM:19260892	Case series	UK/41 females and 17 males, mean age=36yrs;	58	minimum follow up was 6 mo, with n=40 undergoing further review at 12mos and n=31 at 24mos	Permacol (acellular cross-linked porcine dermal collagen)	Nasal region during rhinoplasty	The authors await long-term follow-up, but state that their 5yr experience with Permacol has been extremely promising. The authors state that Permacol is an ideal implant material, allowing excellent natural results complementing the use of autologous	Poor
Inoue et al. PM:18317097	Case report	Japan/50 yr old female with no prior cosmetic surgery	1	43 d	Restylane and Sheba (collagen)	Nasal tip (Restylane) and upper lip and nasolabial fold and upper vermillion (collagen)	The authors state that although the accidental intra-arterial injection of dermal fillers is apparently rare, the potential risk of vascular embolization should be noted, especially when injection into the subcutis of the glabellar region, the nasal ala, and the nasolabial folds.	Poor
Jham et al. PM:19138600	Case reports and comprehensive literature review	Various/General population	56		Various	Upper/lower lip, NLF, cheek		Poor
Kim et al. 2004 PM:15056148	Case Study	Korea/Woman with Artecoll treatment for neck wrinkles	1	4 yr	Artecoll	Not reported	Foreign granuloma due to Artecoll injection treated with three injections of triamcinolone. Artecoll should not be used as an implant material in thin and constantly movable skin.	Poor

Appendix A. Cont'd

Study	Design	Country/population type	Sample size	Follow-up	Treatment	Injection description	Conclusions	Grade
Landau 2008 PM:18380205	Case Series	Israel/female patients with an average age of 52.3yo	15	6 mo	Evolence Breeze (porcine collagen-derived dermal filler), 1.4ml	lip and nasolabial folds	In all patients, a natural look was achieved and filler material could not be palpated. In all cases, the cosmetic effect was maintained up to the last visit at 6 mo after injection.	Poor
Lombardi et al.2004 PM:14720198	Retrospective case series	France/Patients with Artecoll, Dermalive, New-Fill, or Liquid-Silicone induced granulomas	11	Not reported	Artecoll Dermalive New-Fill Liquid-Silicone	Not reported	New dermal fillers may result in new types of granulomas that will need to be identified for medico-legal reasons	Poor
Luu et al. 2007 PM:17321875	Retrospective case series	USA/patients who underwent laryngoplasty between 1997 and 2006	895	Not reported	Zyplast	Paraglottic compartment of the vocal folds	The authors' find that percutaneous collagen injection laryngoplasty is safe in patients taking warfarin. However, the decision to perform such injections in anticoagulated patients rests with the physician performing this procedure. Also, the authors' feel in their experience, prior skin hypersensitivity testing is unnecessary with bovine cross-linked collagen.	Poor
Moody et al.2000 PM:11050497	Retrospective case report	US/54 yr old white woman	1	2 mo	1 cc Dermalogen (human collagen)	30-gauge needle test injection in volar forearm	The literature suggests that while human collagen is quite safe, the possibility still exists for adverse reaction.	Poor
Moody et al.2001 PM:11553165	Retrospective case report	US/45 yr old woman	1	7 wk	Zyderm II (bovine collagen)	Mentolabial crease, chin, lips	Topical tacrolimus is a safe and potentially effective medicine for the treatment of bovine collagen hypersensitivity. The authors indicate further study is required.	Poor



Case Series/Report	Number of studies:	Retrospective case series	Number of studies:	1 mo	Botulinum toxin type A (Botox) n=1 Collagen n=1 Dimethylpolysiloxane (silicone) n=3	Injections into the lower and upper lip, nasogenian area, facial area, cheeks, chin, and buccal mucosa.	The authors feel that these fillers should not be considered innocuous. The reaction to silicone is the most virulent, but adverse reactions have been observed with practically all the products used. They say that more studies are necessary to study other possible bodily responses to silicone.	Poor
Poveda et al. 2006 PM:16388285	5	Spain/55-yr-old woman, 72 year old woman, 70 year old woman, 54 year old woman, 43 year old woman	1 mo					
Requena et al. 2001 PM:11391099	4	Spain/52 yr old man, 42 yr old woman, 2 38 yr old women	6-14 mo	Artecoll n=1 Dermalive n=1 Silicone n=2	Artecoll: nasolabial and forehead folds Dermalive: forehead and periorcular ridges Silicone: nasolabial folds, cheeks	Artecoll and Dermalive are able to stimulate a clinically evident granulomatous reaction in rare cases, even though they are composed of mostly inert materials. Silicone, contrary to popular opinion, is beneficial and safe when it is used properly in small amounts for cutaneous soft tissue	Poor	
Reytan et al. 2007 PM:17903163	1	Germany/26 yr old male with mandibular profnathia	9 wk	Evolence, 2.9ml over 2 sessions	philtrum area, vermilion border, and lip red	This case report illustrates a patient with mandibular prognathia and mild functional deficits who was able to have corrected fullness of the upper lip due to collagen filler. Injectable fillers could be used to augment oromaxillofacial surgery when the obtained aesthetic results are not as good as expected.	Poor	

Appendix A. Cont'd

Study	Design	Country/population type	Sample size	Follow-up	Treatment	Injection description	Conclusions	Grade
Reytan et al. 2008 PM:19112805	Prospective case report	Germany/61 yr old Caucasian HIV-positive male presented with facial lipoatrophy; patient also has history of Hep C	1	14 mo	Evolvec, 5ml in periorcular region and 6ml in cheek augmentation total over 4 treatments	cheek, periorcular region	The authors state that this case report shows that novel bovine collagen fillers offer another option for decreasing the visibility of facial lipoatrophy. Results persisted for 14mos, although further follow up will show that the patient requires repeated injections over time. Additional studies should be conducted to further investigate the use of these fillers in the treatment of HIV- associated facial lipoatrophy.	Poor
Case Series/Report Ricci et al. 2007 PM:18320835	Number of studies: 17 case series	Italy/males between 43 and 78 yr old with severe dysphagia due to partial	7	1yr	Zyplast (bovine collagen)	Laryngoplasty	The authors conclude that these results, even if referring to a small number of cases, show that injection laryngoplasty through fiber endoscopy can be considered a good solution for dysphagia after partial laryngectomy. Also the voice can improve with this procedure. The authors also state that it is worthwhile stressing that logopaedic rehabilitation is fundamental in order to strengthen the results of surgical treatment of dysphagia.	Poor

**CaHA Fillers**

**Randomized Controlled Trial (RCT): No. of studies, 3**

Study	Design	Location	Patients	Follow-up	Intervention	Control	Results	Conclusion
Moers-Carpi et al. 2007 PM:18086052	Multicenter, blinded, randomized trial	Europe	205 (192 patients had moderate or severe NLFs)	4, 8, 12 mo	Radiesse (CaHA), 2.21 ml total volume (n=70) Juvéderm 24 (HA-1A), 4.78 ml total volume (n=33) Juvéderm 24HV (HA-1B), 2.94 ml total volume (n=33) Perlane (HA-2), 2.89 ml total volume (n=65)	Patients treated with either CaHA gel or HA for the correction of both NLFs. Nearly all patients (n=189) received a touch-up treatment at 4 mo.	Both CaHA gel and the HA products display adequate and comparable safety profiles. In this controlled study, CaHA gel ranked highest in patient satisfaction and likelihood to return. The material was more effective and longer lasting than each HA in maintaining NLF augmentation. The authors believe CaHA gel offers advantages in durability, patient satisfaction, and cost, for safe correction of NLFs.	Good
Moers-Carpi et al. 2008 PM:18093199	Multicenter, prospective, randomized, controlled, split-face trial	Germany & Spain	60 (58 severe NLFs (3 or 4 on WSRS))	6, 9, 12 mo	Radiesse Restylane Volume required for correction in CaHA treated fold was 30% less than the volume of NASHA	Patients received two injections 3 mo apart. At the initial visit, patient was treated with CaHA to correct one NLF and NASHA to correct the other NLF. At the 3 mo visit, patients received a touch-up treatment in both folds.	CaHA was found to be significantly more effective than NASHA. At all time points, CaHA demonstrated longer lasting results and greater improvement than NASHA.	Good

Appendix A. Cont'd

Study	Design	Country/population type	Sample size	Follow-up	Treatment	Injection description	Conclusions	Grade
Smith et al. 2007 PM:18086048	Randomized, evaluator-blinded, bilateral, prospective comparison	USA/Potential subjects were required to have symmetric, moderate-to-deep NLFs	117 (113)	1, 3, 6 mo	Radiesse (Collagen)  Cosmoplast (CaHA)	Each side was treated until, in the judgment of the investigator, an optimal result was achieved. At 2 wk following treatment, subjects could receive touch-up injections at the discretion of the physician  Occurred at 2 wk intervals, maximum of two additional treatment sessions.	The CaHA-based product gives significantly longer lasting correction of NLFs compared to human collagen. Fewer injections and less total material are required. The adverse event profiles of the two fillers are similar.	Good
Uncontrolled Clinical Trial Becker 2008 PM:18520907	Number of studies: 15 Uncontrolled clinical trial	USA/General population	24 (18)	2-48 mo	Radiesse, 0.25 to 1.3 ml at initial injection	Various locations, numbers of injections  Cheek	In some patients, the duration of augmentation extended to 26 mo. On average, the length of correction was 9 mo, and touch-up procedures averaged 6 mo after the initial injection and requiring a smaller volume.	Poor
Beer et al. 2008 PM:18459517	Uncontrolled clinical trial	USA/Females with signs of mid-face volume loss	19 (16)	1, 3, 6 mo	Radiesse, volume at discretion of physician	Touch-up treatments were administered at 1 mo at discretion of physician	Based on this study and additional experience with CaHA injection, it is believed that the filler offers a safe, reasonable and reproducible alternative to invasive facial rejuvenation	Poor

Berlin et al. 2008 PM:18547184	Uncontrolled clinical trial	USA/Subjects with prominent nasolabial rhytids	5	6 mo	Radiesse, 0.1 to 0.2 ml	Right postauricular area	Soft tissues augmentation with CaHA fillers leads to the long-term deposition of new collagen surrounding filler microspheres. This may contribute to the overall improvement in the appearance of treated rhytids.	Poor
Carruthers et al. 2008 PM:18547186	Open-label, single-center uncontrolled clinical trial	USA/Patients with lipoatrophy or pronounced NLFs	58	None	Radiesse	Not reported	Earlier clinical trials established CaHA as a safe and effective soft tissue filler. This CaHA study shows no overt radiographic safety concerns. CaHA is unlikely to be confused with conventional and abnormal and adverse radiographic findings. This product is not always visible on X-ray. Although usually visible on CT scans, its appearance is distinct from the surrounding bony structures and does not interfere with normal analysis. The product also does not obscure underlying structures on CT scans.	Poor
Jacovella et al. 2006 PM:16936540	Clinical Trial	Argentina/ facial injections for cosmetic purposes	40 (40)	18 mo	Radiesse 0.5-2.0 ml (average of 0.75 ml)	Injections to the glabellar wrinkles, nasolabial folds, lips, nose, and/or infraorbital area	Radiesse is highly effective and long lasting with high patient satisfaction for volumetric augmentation.	Poor

Appendix A. Cont'd

Study	Design	Country/population type	Sample size	Follow-up	Treatment	Injection description	Conclusions	Grade
Uncontrolled Clinical Trial Jansen et al. 2006 PM:16936541	Clinical Trial	Number of studies: 15 US/facial injections for cosmetic purposes	609 (155; 6 mo) (112; 12- 24 mo)	6, 12-24 mo	Radiesse Nasolabial folds 0.62 ml each n=395 areas Upper lip 0.6 ml Lower lip 0.25 ml n=338 areas (combined lips) Radial lip line 0.25 ml per line n=163 areas Corner of mouth 0.28 ml n=125 areas Marionette lines 0.49 ml each side n=75 areas Glabella lines 0.22 ml n= 106 areas Chin/cheek lines 0.20 ml n=50 areas Acne scars 0.12 ml n=33 areas Scar deformities 0.2-0.4 ml n=21 areas Facial depression (HIV lipoatrophy) 5.25 ml n=14 areas Cheek augmentation 0.85 ml each side n=14 areas Nasal depressions 0.2 ml n=6 areas Tear troughs 0.35 ml n=8 areas Touch-ups average 0.3 ml	Injections to the nasolabial folds, marionette lines, oral commissure, cheeks, chin, lips, and/or radial lip lines	The implant is safe, long lasting, and highly effective	Poor
Uncontrolled Clinical Trial Marmur et al. 2009 PM:19708875	Uncontrolled clinical trial	Number of studies: 15 USA/female patients aged 60-80yo with soft tissue deficiency of the dorsa of the hands	5	24wks	Radiesse, 1.3ml per hand for n=4 patients and 2.6ml per hand for n=1 patient	dorsal side of hand	To the authors' knowledge, this is the first IRB approved study performed to demonstrate the clinical results of CaHA for soft tissue augmentation in the hands. Clinical improvement was still seen after 24wks after injection. Patient satisfaction was high after initial injection and remained so through the	Poor

Marmur et al. 2009 PM:19708876	Nonrandomized clinical trial	USA/patients aged 18 yr and older with Fitzpatrick skin types IV to VI	100	6 mo	Radiesse, 0.6-2.8ml	facial wrinkles and folds, including nasolabial folds	The authors state that the data show that people with dark skin, if injected subdermally with CaHA, do not show signs of keloid formation, hypertrophic scarring, or hyper-or hypopigmentation. Because of this safety feature, as well as other characteristics of the product already shown in clinical literature, CaHA is an attractive dermal filler in this population.	Poor
O'Hara et al. 2006 PM:16651970	Clinical Trial	US/patients undergoing zygomatic augmentation	8 (8)	1, 7 d 3, 6, 12 mo	Hydroxyapatite injections in 0.5-1.0cc increments from 2.0cc to 4.0 cc per side (average 2.5cc)	Transconjunctival injections into the subperiosteal malar pockets	Injection of hydroxyapatite granules through a transconjunctival approach into the subperiosteal malar pockets results in measurable augmentation with minimal complications and high patient satisfaction.	Poor
Roy et al. 2006 PM:16970693	Uncontrolled clinical trial	USA/patients requesting facial soft tissue augmentation, n=3 males and n=79 females	82	3-6 mo	Radiesse	The mean amount of material injected at the initial visit was 0.29ml in the melolabial fold (per side), 0.34ml in the upper lip, 0.37ml in the lower lip, and 0.12ml in the infra commissural fold	The authors primary experience with Radiesse is very positive, and they determine it is a safe, easy to use, predictable, and reliable implant for facial soft-tissue augmentation.	Poor
						The mean amount of material injected during touch-up injections was 0.15ml in the melolabial folds (per side), 0.13ml in the upper lip, and 0.12ml in the lower lip		

Appendix A. Cont'd

Study	Design	Country/population type	Sample size	Follow-up	Treatment	Injection description	Conclusions	Grade
Uncontrolled Clinical Trial Sadick et al. 2007 PM:18086049	Number of studies: 15 Two site, open-label study	USA/Subjects with facial soft tissue deficiency amenable to treatment	113	6 mo	Radiesse; 1.0 ml (n=102), 2.0 ml (n=12)	Most commonly treated site was the NLF (n=86). Other sites included perioral lines, acne scars, tear trough depressions, and prejowl sulcus. 75 (67%) had a single injection session; 38 (34%) had multiple sessions.	In the study, CaHA performed well and exhibited a favorable safety profile along with high patients satisfaction and good durability.	Poor
Silvers et al. 2006 PM:16936543	Clinical Trial	US/patients with facial lipoatrophy secondary to HIV	100 (100)	3, 6, 12, 18 mo	Radiesse 4.8 ml (avg)	Injections to the cheek area (submalar) performed by the investigators. Initial injections followed up with subsequent injections at 1, 6, and 18 mo	Radiesse is an appropriate and well-tolerated treatment for patients with facial lipoatrophy.	Poor
Uncontrolled Clinical Trial Sklar et al. 2004 PM:15099322	Number of studies: 15 Clinical Trial	US/patients with subcutaneous or deep tissue atrophy	64 (64)	6 mo	Radiance FN Nasolabial folds 0.91 ml (avg) 0.4-2.0 ml n=52 Tear trough 0.35 ml (avg) 0.3-0.7 ml n=15 Lips 0.67 ml (avg) 0.2-1.4 ml n=15 Infraoral 0.29 ml (avg) 0.1-0.5 ml n=11 Cheeks 0.60 ml (avg) 0.3- 1.2 ml n=4 Mental crease 0.15 ml (avg) 0.1-0.2 ml n=2 Above upper lip 0.20 ml (avg) 0.2 ml n=1 Buccal region 2.0 ml (avg) 2.9 ml n=1	Injections in a retrograde technique to Nasolabial folds, Tear trough, Lips, Infraoral, Cheeks, Mental crease, Above upper lip, Buccal region	Radiance FN can be used as a deep soft-tissue filler with immediate aesthetic effect and little down-time	Poor



Stupak et al. 2007 PM:17372068	Prospective, before- and-after, clinical trial	USA/patients with post-rhinoplasty contour irregularities or asymmetry	13	2.5 mo	Radiesse, mean dose was 0.19ml	Dorsum and bilateral walls of the nasal region	Calcium hydroxylapatite has been shown in this study to result in improvement in post-rhinoplasty nasal symmetry and in smoothing of the curves and lines that constitute the contour of the nose. Overall, patient satisfaction was high and few problems were encountered. Long-term studies of safety and efficacy are warranted.	Poor	
Uncontrolled Clinical Trial Number of studies: 15									
Tzikas 2004 PM:15262717	Clinical Trial	US/patients seeking soft tissue augmentation	90 (	6 mo	Radiance FN 0.2 ml (avg)	Injection subdermally between dermis and subcutaneous fat to the nasolabial folds, glabellar rhytids, marionette lines, prejowl depressions, acne scars, and surgical soft tissue defects. Injection to the lips in the plane superficial to the orbicularis muscle.	Radiance FN is effective and well-tolerated.	Poor	
Cohort Study Number of studies: 2									
Rokhsar et al. 2008 PM:18384613	Prospective	USA/Subjects with or without a prior history of surgical rhinoplasty	14	6 mo	Radiesse, mean 0.27 ml at initial visit	Nonsurgical nasal recontouring, 30% of patients requested additional touch- ups at 2 wk follow- up visit	All patients tolerated the procedure well, and only one-third requested a minor touch-up at 2 wk. At the 6 mo follow-up, cosmetic results and patient satisfaction were still maintained.	Poor	
Tzikas 2008 PM:18547188	Retrospective review	USA/Patients > 18 yr with a facial soft tissue deficiency amenable to treatment	1000	1 yr	Radiesse, mean volume 1.9 ml	Variety facial contouring applications, majority NLFs and marionette lines		Poor	

Appendix A. Cont'd

Study	Design	Country/population type	Sample size	Follow-up	Treatment	Injection description	Conclusions	Grade
Cross-sectional Study Alam et al. 2007 PM:17224371	Number of studies: 1 Prospective follow-up study	USA/patients presented for correction of depressions of the nasolabial folds	22 (18)	1-1.5yr	Radiesse, 1-2ml in each NLF	Nasolabial folds	When a consistent, defined injection technique is used, injectable calcium hydroxylapatite appears to be a well-tolerated soft-tissue augmentation material for correction of nasolabial fold depressions. A long duration of effect may make this material particularly desirable for some patients.	Poor
Case Series/Report Beer 2007 PM:17763619	Number of studies: 11 Case report	USA/59 yr old female	1	6 wk	Radiesse, 3.9ml	Nasolabial creases and marionette lines	In this case, a distant nodule is documented following injections of Radiesse. Although the product is safe and effective for cosmetic indications, one should be aware of the potential for this or any filler to migrate and be prepared to deal with the consequences.	Poor
Feeney et al. 2009 PM:19664480	Case Series	US/Patients with hyperattenuating hypermetabolic subcutaneous lesions and a history of facial injections	5 (5)	NA	Radiesse	<ol style="list-style-type: none"> <li>1. Injections to the left infrazygomatic region</li> <li>2. Injections to the infraorbital and infrazygomatic regions</li> <li>3. Injections to the infraorbital and infrazygomatic regions</li> <li>4. Injections to the infraorbital, nasolabial, parotid and perioral regions</li> <li>5. Injections to the infraorbital, infrazygomatic, and perioral</li> </ol>	<p>CaHa dermal filler is hyperattenuating on CT, hypermetabolic on FDG-PET imaging, of intermediate signal intensity on MRI, and is a potential cause of a false-positive imaging study.</p>	Poor

Godin et al. 2006 PM:16549735	Prospective Case Series	US/patients undergoing facial augmentation	101 (61)	10 mo	Radiesse n= 72 Radiesse and Restylane n=29	Injection to the nasolabial folds, upper and lower lip vermilion borders, "lipstick lines" and perioral lines	Combination group tended to have greater intermediate and overall satisfaction scores than the Radiesse alone group.	Poor
Kanchwala et al. 2005 PM:15985788	Retrospective Case Series	US/patients undergoing facial augmentation	976	3, 6, 9, 12	Autologous fat n=697 Hylaform n=52 Restylane n=86 Radiesse n=141	Nasolabial folds, lips, glabella	Successful fat transplantation appears to be the preferred method for the treatment of volume loss to the face.	Poor
Case Series/Report Kotlus et al. 2007	Number of studies: 11 Case report USA/66 yr old	male 1 6 mo Radiesse, two 1.3ml Left orbital region The authors state that		the present study Poor presented with treatments 3wks apart shows the continued maintenance 4mos	of PM:17667106 anophthalmic increased orbital volume at	6mos. enophthalmos caused Further studies	will clarify the long-term	by an accident durability of these effects.
Lee et al. 2008 PM:18806674	Case report	Korea/37 yr old female with 2mo history of fullness and ptosis of the left upper eyelid	1		Radiesse	eyelid and orbital region	Mass formation in the eyelids is a rare but potentially serious complication resulting from the use of CaHA facia filler to the nasal region, and the authors believe they have presented the first case report describing such an adverse reaction and the treatment for this problem. The authors believe that proper site selection, a meticulous injection technique, and avoidance of over- injection will help prevent this complication.	Poor

Appendix A. Cont'd

Study	Design	Country/population type	Sample size	Follow-up	Treatment	Injection description	Conclusions	Grade
Sankar et al. 2007 PM:17670876	Case report	USA/51 yr old female presented with chief complaint of a lump the mucosal aspect of her lower lip on the left side	1	Unknown	Radiesse	lip	The authors believe this case is unique in that the cosmetic filler injection resulted in a foreign body reaction not reported previously as a side effect of using the filler. As cosmetic procedures become more common, dentists should question patients about any cosmetic procedures they may have undergone and include them in the differential	Poor
Shumaker et al. 2009 PM:19207328	Case report	USA/57 yr old female presented with a several month history of enlarging plaque of the left superior nasolabial fold, after examination, patient had a pearly plaque that demonstrated basal cell carcinoma	1	presentation n was 8yrs following first treatment	Radiesse	Nasolabial fold		Poor
Sires et al. 2008 PM:18520838	Case report	USA/57 yr old immuno-competent woman who developed herpetic appearing skin lesions after injection of Radiesse in the glabella	1	6 mo	Radiesse, four 0.3ml treatments	Glabella, marionette lines, and nasolabial folds	The authors state that to their knowledge, this is the first description of the filler Radiesse inducing herpetic appearing skin lesions in the region of the glabellar injections. Neither culture nor antibody testing was performed to confirm the diagnosis but the clinical presentation, findings, and resolution with antivirals were classic for herpes	Poor

Case Series/Report	Number of studies:	Number of patients	Age	Duration	Intervention	Outcomes	Limitations
Vagefi et al. 2007 PM:18025356	Retrospective case series	4 USA/3 females and 1 male, mean age 36yrs, all with Postnucleation/ eviscer- ation socket syndrome (PESS)	Ranged from 45-71wks	1.3-2.6ml Radiesse	Extraconal space in the orbital region	To the authors' knowledge, this is the first case series that quantitatively demonstrates the efficacy and longevity of injectable calcium hydroxylapatite to replace orbital volume in patients with PESS. The authors anticipate broader clinical uses of the filler and suggests broader studies with more patients with anophthalmic enophthalmos and with blind enophthalmic eyes before using the procedure in sighted patients.	Poor
Vagefi et al. 2008 PM:18520833	Prospective, small interventional case series	3 (2 male, 1 female) USA/patients with bony defects of the frontal bone from prior trauma or surgery	2-7 mo	1.3-3.9ml Radiesse/calcium hydroxylapatite	Filler injected into bony defects subdermally, in conjunction with other eyelid procedures	the authors note that their experience with injectable calcium hydroxylapatite for aesthetic purposes including soft- tissue augmentation of the nasolabial folds and oral commissure, and chin and cheek augmentation, has typically resulted in long-term retention of less than half of the injected volume, ranging up to 2 years. The technique shown in this study provides an easy, semipermanent, safe approach to small skull defects that can be performed in an office or ambulatory surgery setting.	Poor

Appendix A. Cont'd

Study	Design	Country/population type	Sample size	Follow-up	Treatment	Injection description	Conclusions	Grade
<b>PLLA Fillers</b>								
<b>Systematic Review: No. of studies, 1</b>								
El-Beyrouty et al. 2006 PM:16912248	Systematic Review	US, England and France/ systematic review of studies conducted in HIV lipotrophy populations of white males	6 clinical trials: VEGA Chelsea and Westminster Lafautie et al. APEX 001 APEX 002 Blue Pacific	Various	Poly-L-lactic acid 1. VEGA: Poly-L-lactic acid 4.0 ml n=47 2. Chelsea and Westminster: Poly-L-lactic acid 3.0 ml n=29 3. Lafautie et al.: Poly-L-lactic acid 2.5 ml n=94 4. APEX 001: Poly-L-lactic acid 1.0-8.0 ml n= 100 5. APEX 002: Poly-L-lactic acid 8.0 ml n= 99 6. Blue Pacific Group: Poly-L-lactic acid 6.0 ml n=99	Injections to the cheeks for the treatment of HIV lipotrophy	Poly-L-lactic acid offers a treatment alternative for patients with HIV-associated lipotrophy in white	Poor
<b>Randomized Controlled Trial (RCT): No. of studies, 2</b>								
Moyle et al. 2004 PM:15012646	RCT	UK/Patients with HIV/induced facial lipotrophy	30 (30)	0, 12, 24 wk	New-Fill immediate treatment n=15 New-Fill delayed treatment n=15	Injection into the deep dermis overlying the buccal fat pad	PLA injections led to improvements in patient self perception and decreased anxiety and depression scores	Good
<b>PLLA Fillers</b>								
<b>Randomized Controlled Trial (RCT): No. of studies, 2</b>								
Moyle et al. 2006 PM:16494632	RCT	US/Patients with HIV/related facial lipotrophy	30 (27)	18 mo	Sculptra (PLLA) immediate treatment 3.0 ml n=15 Sculptra (PLLA) delayed treatment 3.0 ml n=15	Three sets of bilateral injections, 2 weeks apart, to the deep dermis above the buccal fat pad	PLLA has a favorable long-term safety and efficacy profile	Good
<b>Uncontrolled Clinical Trial: No. of studies, 4</b>								
Beer 2007 PM:18086054	Single-center, open-label study	USA/Subjects with facial scars resulting from moderate to severe acne or varicella	20 (16)	At each treatment session	Sculptra	Injections were given at 1 mo intervals to primary endpoint of resolution of scars (up to 7 treatment)	Injectable PLLA as used in this investigation appears to correct the types of acne scars treated in this study without the serious side effects. Treatment 6 and 7 data suggest that reductions in size and severity may plateau after Treatment 6.	Poor

Burgess et al. 2005 PM:15692467	Clinical Trial	US/HIV-infected males on HAART with facial lipotrophy	61	6, 18 mo	New-Fill Stage I lipotrophy 4.0- 12.0 cc n=9 Stage II lipotrophy 8.0- 12.0 cc n=15 Stage III lipotrophy 12.0- 24.0 cc n=30 Stage IV lipotrophy 16.0- 24.0cc n=7 Sculptra, 4-8ml	Injection to the junction of the subcutaneous-deep dermal plane. Fanning injection technique was used to create a deep dermal lattice	Use of PLA to treat facial lipotrophy resulted in significant and prolonged improvement in treated patients up to two years	Poor
Hanke et al. 2007 PM:17373169	Uncontrolled clinical trial	USA/27 HIV positive patients and 38 HIV negative patients	65	2 yr	Sculptra, 4-8ml	cheeks	PLLA is an injectable filler that corrects soft-tissue volume loss secondary to HIV lipotrophy and lipotrophy of aging. Treatment is safe and effective in both HIV positive and HIV negative patients. Precise technique is essential for good results. Results are long lasting and associated with high rates of patient satisfaction.	Poor
<b>Uncontrolled Clinical Trial: No. of studies, 4</b>								
Salles et al. 2008 PM:18551341	Uncontrolled clinical trial	Brazil/General population	10	6, 36 mo	Sculptra	NLFs, One injection per mo for 3 mo.	Patients need to be counseled about the delayed process of aesthetic transformation. The results showed that at 3 y, the PLA filler was stable. The augmentation results with PLA filler could last up to 3 yr.	Poor
<b>Cohort Study Number of studies: 7</b>								
Kavouni et al. 2008 PM:18449827	Retrospective analysis of PLLA treatment	UK/HIV-positive patients with facial lipotrophy	441	3-32 mo	New-Fill	Minimum 10 ml injected into facial areas including the temples, infraorbital grooves, buccal areas, nasolabial folds, above and below the zygoma and prepatotid	The characteristics of the treatment protocol that allowed for an increase in the perceived resolution of facial changes to 90% included using two vials per session (one vial per each side of the face), a significant expansion of the facial areas treated, and an increase in the number of sessions based on lipotrophy severity.	Poor

Appendix A. Cont'd

Study	Design	Country/population type	Sample size	Follow-up	Treatment	Injection description	Conclusions	Grade
Levy et al. 2008 PM:19022099	Prospective cohort study	USA/HIV positive and HIV negative patients	65 (53)	3 yr	Sculptra, 5.0 mL	Half of the volume injected into dermis, half into the underlying subcutaneous tissue; 4 to 8 areas on each cheek	PLLA is a safe and effective treatment to correct HIV lipoatrophy and lipoatrophy of again. Results appear to be long lasting, persisting for up to 3 years with additional treatment in a subset of patients and at least 1 year after the last treatment. Patient satisfaction with PLLA is high.	Poor
Lowe et al. 2009 PM:19207324	Single-center, retrospective survey	UK/Patients receiving 1-5 PLLA treatments	221	6 to 24 mo	Sculptra	Cheeks; perioral, chin, deltoids, thighs, gluteal, forehead	Injectable PLLA provides an option for correcting areas of volume loss. Several treatment sessions are required to obtain maximum benefits, which may be a practical problem for patients. The efficacy and safety is enhanced by using an optimized injection technique and appropriate postinjection care, including massage.	Poor
Mazzucco et al. 2009 PM:19438668	Prospective, noncomparative study	Brazil/Patients with one or more of the following signs of aging: cutaneous flaccidity, atrophy, and wrinkles in the neck and chest	36	60 d, 18 mo	Average 3.9 ml dose injected per session n=36	Neck and chest (presternal area); average 1.8 sessions per patient	The use of PLLA in the neck and chest was safe and efficacious and represents a prophylactic and therapeutic alternative for the treatment of flaccidity and lipoatrophy of these difficult areas, with lower risk and morbidity than conventional surgical	Poor



<p>Cohort Study Mest et al. 2009 PM:19207325</p>	<p>Number of studies, 7 Single-site, open-label, retreatment study initiated after the</p>	<p>USA/HIV-positive patients</p>	<p>65</p>	<p>24 mo</p>	<p>PLLA, 1-10 ml</p>	<p>Patients treated at 5-week intervals until full correction was obtained.</p>	<p>Injectable PLLA is a safe and effective long-term treatment option for HIV-associated lipoatrophy.</p>	<p>Poor</p>
<p>Negredo et al. 2006 PM:17192148</p>	<p>Comparative, prospective cohort study</p>	<p>Spain/ HIV-infected patients presenting with antiretroviral-associated facial lipoatrophy for more than 6mos</p>	<p>138 (n=8 received fat, n=25 received poly-L-lactic acid, and n=105 received polyacrylamid gel)</p>	<p>96 wk</p>	<p>Analogous fat obtained by liposuction, 50ml Poly(lactic Acid, 3-14ml Polyacrylamid gel, 4-18ml</p>	<p>Nasolabial folds</p>	<p>The authors' conclude that polyacrylamide gel provides the longest lasting results of the three products compared. However, biodegradable products, such as fat and poly(lactic acid should also be considered as viable options for the treatment of facial lipoatrophy. The choice of the best product for reconstructive purposes should be made in concordance with a physician's clinical evaluation and the patient's preferences.</p>	<p>Fair</p>
<p>Sadick et al. 2008 PM:19016062</p>	<p>Retrospective cohort</p>	<p>USA/General population</p>	<p>26</p>	<p>6-12 mo</p>	<p>PLLA, 1.5-2.0 ml</p>	<p>Hand, mean 2.38 treatments per patient</p>	<p>The overall results from the three clinics presented show that patients were very satisfied with the results of PLLA treatment for the hands, and experienced only minor and short-term injection-related and related events.</p>	<p>Poor</p>

Appendix A. Cont'd

Study	Design	Country/population type	Sample size	Follow-up	Treatment	Injection description	Conclusions	Grade
<b>Case Series/Report: No. of studies, 19</b>								
Apikian et al. 2007 PM:17524125	Retrospective case series	Australia/4 white women aged 48-57	4	7 d - 2 yr	New-Fill	Report 1: infraorbital areas, temporal areas, cheek area  Report 2: each infraorbital region and nasolabial line Report 3: infraorbital area, nasojugal lines, marionette lines in first treatment, infraorbital area, cheek bone area, and marionette lines 6 weeks alter. Report 4: infraorbital areas, cheeks, and marionette lines.	The use of NewFill in the infraorbital region should be avoided until more studies are completed.	Poor
Beer 2009 PM:19207333	Prospective Case Report	US/64 yr old woman cosmetic treatment of periorbital areas, 59-yr-old woman evaluated for facial rejuvenation  US/59-year-old woman treatment of mid-face descent	2 (2)	12-18 mo	PLLA, 2.0 ml each tear trough, two sessions, 4 wks apart  PLLA, 1.0 ml, each tear trough	Depot injections into each tear trough made at the level of the periosteum  Injections into the cheeks, tear troughs, and zygomatic arch areas	The authors conclude that delayed formation of papules in the periorbital area were presented by the patient. The authors also suggest that clinical trials in this area may provide more insight into the etiology and treatment to improve the outcomes associated with PLLA.	Poor
Beijaards et al. 2005 PM:16029705	Retrospective case report	The Netherlands/3 women aged 35-53	3	12-22 mo	1-3 ml reconstituted NewFill (polylactic acid)	Nasolabial folds, cheeks, lips, neck.	Physicians should be apprehensive about using NewFill. Because there are no tests available to indicate who may be susceptible to the observed side effects, the authors suggest that the use of foreign body materials for tissue augmentation is risky.	Poor

Burgess 2008 PM:18231700	Case report	USA/ 69 yr old African-American woman	1	18mos	Sculptra, 5ml each treatment, two treatments total	dermal subcutaneous plane of the upper and lower cheeks as well as the preauricular and malar regions	The authors conclude that the use of PLLA represents a well-tolerated and effective minimally invasive treatment for facial contour defects caused by lipoatrophy.	Poor	
<b>Case Series/Report: No. of studies, 19</b>									
Hamilton et al. 2008 PM:18053031	Case report	France/58 yr old immunocompetent female presented with subcutaneous nodules	1	4 yr	Sculptra, 9ml	Nasolabial folds (6ml) Cutaneous border of the vermilion (1ml) Jugomalar depression adjacent to the infraorbital periosteum (2ml)	The authors believe that inadvertent placement of PLA in the upper dermis or the clumping of implant beads in the deeper tissue planes is a common cause of early-onset nodules. It is the experience of the authors that higher dilutions of PLA appear to yield lower incidence of late-onset, inflammatory nodules.	Poor	
Jham et al. PM:19138600	Case reports and comprehensive literature review	Various/General population	56		Various	Upper/lower lip, NLF, cheek		Poor	
Kates et al. 2008 PM:19083552	Case report	USA/ 2 white males in their 40s with facial lipoatrophy who had been HIV-positive for more than 10yrs	2	12 mo	PLLA	deep dermis or subcutaneous layer of the face, 2 vials in each of 5 treatments spaced 4 wks apart	As demonstrated with these cases, PLLA is an excellent choice for volume restoration in the HIV-associated facial lipoatrophy patient with long-lasting results.	Poor	
Lombardi et al. 2004 PM:14720198	Retrospective case series	France/Patients with Artecoll, Dermalive, New-Fill, or Liquid-Silicone induced granulomas	11	Not reported	Artecoll Dermalive New-Fill Liquid-Silicone	Not reported	New dermal fillers may result in new types of granulomas that will need to be identified for medico-legal reasons	Poor	

Appendix A. Cont'd

Study	Design	Country/population type	Sample size	Follow-up	Treatment	Injection description	Conclusions	Grade
Mest et al. 2006 PM:17083585	Prospective case series	USA/patients over the age of 18 with HIV seropositivity and facial lipoatrophy	97(75)	12 mo	PLLA, 1-6ml per session, with patients receiving between 1 and 6 sessions	cheeks and temples	The results of this study clearly show the long-term (12mo) effectiveness of injectable PLLA in the treatment of HIV-associated facial lipoatrophy. The findings of this study also reinforce previous European studies that PLLA is a safe and effective treatment for HIV-associated facial lipoatrophy.	Poor
Poveda et al. 2006 PM:16388285	Retrospective case series	Spain/55-yr-old woman, 72 year old woman, 70 year old woman, 54 year old woman, 43 year old woman	5	1 mo	Botulinum toxin type A (Botox) n=1 Collagen n=1 Dimethylpolysiloxane (silicone) n=3	Injections into the lower and upper lip, nasogenian area, facial area, cheeks, chin, and buccal mucosa.	The authors feel that these fillers should not be considered innocuous. The reaction to silicone is the most virulent, but adverse reactions have been observed with practically all the products used. They say that more studies are necessary to study other possible bodily responses to silicone.	Poor
<b>Case Series/Report: No. of studies, 19</b> Ralston et al. 2006 PM:17373151	Retrospective case report	US/40 yr old white woman	1	10 mo	Sculptra	Upper arm	Melanoma patient had significant improvement from one treatment with Sculptra. This experience suggests that this product may be able to be used for treatment after excisional surgery.	Poor

Redaelli 2006 PM:17177745	Case series	Italy/female patients aged between 59-72	27	6-15 mo	PLLA, 2ml per hand in the first session, 1-2ml for subsequent sessions	dorsum of the hand	Poly-lactic acid can treat the problem of hand aesthetics with a good chance of success. The experience is still small and must be validated over the years. Above all, the real absences of major side effects must be confirmed with longer follow-up, aiming in particular to avoid nodules. In the author's opinion the principal side effects, nodules, are ascribable to an unsatisfactory technique. One cannot forget that at least 1.5 hrs with anesthesia and massage is the required time for this procedure. In order to obtain good results, it is mandatory to have this time available to complete all the steps with due care.	Poor
Rendon et al. 2008 PM:18441843	Prospective case report	USA/64 yr old woman who underwent extensive surgical procedures for damage to the craniofacial area following a car accident	1	5 mo	Poly-L-lactic Acid, 5ml	Deep dermis of the cheeks (2ml); nasolabial folds (1ml), zygomatic arches (1ml), temples (0.5ml), and chin (0.5ml) Above treatment repeated 2 more times about a month apart	The authors state that this case report demonstrates that PLLA can be used for correction of facial lipatrophy and asymmetry secondary to traumatic injury. PLLA should be considered in the treatment of trauma induced facial lipatrophy and asymmetry and may have a future role in the treatment of congenital abnormalities as well. While foreign body granulomas are a reported side effect from PLA injection, with appropriate deposition technique and adequate dilution, this adverse event can be rare.	Poor
Reszko et al. 2009 PM:19207329	Retrospective Case Report	US/62 yr old immunocompetent patient	1 (1)	12-18 mo since treatment	Sculptra (Poly-L-lactic acid)	Bilateral cheeks, chin, and infraorbital areas	While foreign body granulomas are a reported side effect from PLA injection, with appropriate deposition technique and adequate dilution, this adverse event can be rare.	Poor

Appendix A. Cont'd

Study	Design	Country/population type	Sample size	Follow-up	Treatment	Injection description	Conclusions	Grade
<b>Case Series/Report: No. of studies, 19</b>								
Rosner et al. 2009 PM:19250160	Case series	Germany/ Patients from Berlin Registry presenting an adverse reaction to PLA	22	8 yr	New-Fill	Not reported	PLA is an injectable filler substance that in most cases of adverse events produced subcutaneous nodules. As the frequency of the reported reactions was followed over a period of 8 yr, the data suggest a positive influence of higher dilution of PLA towards a decreased risk of nodule formation. Therefore, a higher dilution should be recommended to physicians using PLA.	Poor
Schulman et al. 2008 PM:18186871	Case report	USA/63 yr old thin female who complained of a superior "step-off" deformity and visible intercostal spaces after implant reconstruction	1	9 mo	Sculptra - 4 treatments at 1 month intervals, each treatment was two 367.5mg vials	Subcutaneous tissue and deep derma layers of the superior and medial right chest wall	The authors state that they have presented a successful case of the use of Sculptra in the correction of a persistent chest wall defect after impact reconstruction in an extremely thin woman.	Poor
Stewart et al. 2007 PM:17667102	Case report	USA/39 yr old female presented with multiple visible, palpable papules in bilateral infraorbital region	1	4 mo	Sculptra	bilateral infraorbital region	In the case of PLLA, proper reconstitution of the product appears to play a significant role in rates of nodule formation. Should a symptomatic granuloma form in the periorbital area, currently the most effective treatment would be a minimally invasive surgical	Poor
Woerle et al. 2004 PM:15303782	Prospective case series and retrospective case report	Europe/300 patients (70% m) for prospective, 48 yr old man and 51 yr old woman for retro	302	12-24 mo	Poly-L-lactic acid	26 gauge needle into the nasolabial folds, Marionette lines, labiomental creases, upper lip, cheeks, chin, and temples.	The authors deem poly-L-lactic acid effective for wrinkles, folds, and depressions of the lower face.	Poor

From 1999–2002 the acid mixture stood for 2–12 hours before injection. Afterwards the mixture stood for 36–48 hours.

Given the increasing use of fillers, it might be worth considering removing them from the list of medical items and including them in a category with more stringent investigation.

Newfill, Restylane, DermaLive Zygomatc arch, eyelids, forehead, nasolabial folds, cheeks

3 mo - 2 yr

Austria/258 yr old women, 153 yr old woman

Retrospective case series

Wolfgram et al. 2006  
PM:17135735

Artecoll n=128  
Zyderm II or Zyplast n=123

Tunneling technique: labella, nasolabial folds, radial upper lip lines, marionette lines

1, 3, 6, 12 mo

US/patients at least 18 years of age presenting for glabellar, nasolabial folds, radial upper lip lines, marionette lines correction

RCT (double-blind)

Cohen et al. 2004  
PM:15468406

ArteFill (amount not specified) n=128  
Collagen (amount not specified) n=123

Injection at the glabella, nasolabial folds, radial upper lip lines, or corners of the mouth

1, 3, 6, 12 mo 4-5 years

US/patients with wrinkles of the glabella, nasolabial folds, radial upper lip lines, and corners of the mouth; treated with PMMA filler in pivotal RCT (Cohen 2004)

RCT (double-blind)

Cohen et al. 2006  
PM:16936546

Study demonstrated the overall safety and effectiveness of Artecoll relative to that of collagen

Study demonstrated the overall safety and effectiveness of ArteFill relative to a collagen control. Effectiveness was demonstrated for all areas treated.

Good

Good

Good

Good

**PMMA Fillers**  
**Randomized Controlled Trial (RCT): No. of studies, 2**

Appendix A. Cont'd

Study	Design	Country/population type	Sample size	Follow-up	Treatment	Injection description	Conclusions	Grade
Cohort Study Cohen et al. 2007 PM:18086062	Number of studies: 1 5 yr follow-up of original RCT, subjects randomized to polymethyl- methacrylate (PMMA) filler treatment or who elected to cross over to PMMA filler therapy at the conclusion of 6 mo collagen control treatment	USA/Patients treated with PMMA filler in pivotal RCT (Cohen 2004)	251 (145)	5 yr	ArteFill, 0.82 ml/fold n=128	NLF	Follow-up study showed PMMA filler continued to maintain significant cosmetic correction for 5 yr postinjection. This is the only FDA approved filler with a documented durability over a 5 yr period. The product was well tolerated, and its safety was consistent with other soft tissue filler agents. May also offer additional safety benefits because few repeat treatments are needed.	Poor
Case Series/Report Bedocs et al. 2008 PM:18441850	Number of studies: 10 Case report	USA/ 1970 woman presented with a 3mo history of an erythematous pruritic plaque located in the area of an unconventional invisible tattoo placed on the upper arm	1	9 mo since procedure	PMMA with fluorescent dye	Upper arm	PMMA is an elegant compound with various forms and functions. In contrast to its other medical uses, PMMA use in dermatology has been met with resistance due to increased reported incidence of adverse events. The authors believe this is the first reported case of a granuloma formation caused by recreational use of a PMMA implant in the form of an invisible tattoo.	Poor



<p>Carvalho, I et al. 2009 PM:19438669</p>	<p>Prospective case report</p>	<p>Brazil/men and women without previous facial augmentation treatments, 30% (n=79) with facial atrophy due to AIDS, 60% (n=159) with photoaging signs, 9% (n=5) with depressed but distensible scars, and 1% (n=3) with residue depressions from cutaneous lupus profundus</p>	<p>154 females 112 males</p>	<p>1 mo and 6 mo post-treatment, and then each yr for 9yrs</p>	<p>Metacrilil (PMMA), 1ml- 8ml depending on patient</p>	<p>24-, 23-, or 26-gauge needles used, product inserted at the subcutaneous tissue or subdermal layer  sessions varied from 1-4, within intervals of approximately 40-60 days between applications.</p>	<p>Authors note that their study indicates PMMA to be safe, and that they observed a high rate of patient satisfaction, corroborating product efficacy and good results even after several years of the procedure. As a result of this study, the authors conclude that PMMA used for the treatment of atrophy, depressions, and facia wrinkles has been shown to be effective, long-lasting, safe, and gratifying to patients and physicians.</p>	<p>Poor</p>	
<p>da Costa Miguel et al. 2009 PM:19243914</p>	<p>Retrospective case report</p>	<p>Brazil/56 yr old female presented with swelling in the lower lip</p>	<p>1</p>	<p>case presented 1yr following treatment</p>	<p>PMMA</p>	<p>Lip</p>	<p>This case report alerts professional to the possibility of unusual clinical presentations of foreign body granulomas associated with the injection of permanent cosmetic fillers.</p>	<p>Poor</p>	
<p><b>Case Series/Report: No. of studies, 10</b></p>									
<p>Gelfer et al. 2007 PM:17451587</p>	<p>Case Series</p>	<p>United States/General population</p>	<p>10</p>	<p>Up to 3 y</p>	<p>10 cases presented.</p>	<p>Various sites</p>	<p>The soft-tissue augmenting agent Artecoll has proven to be a safe, effective, and long-lasting solution for dermal contouring deficiencies. In experienced hands, it is associated with a very low incidence of adverse effects. The main concern about its use is reports of granuloma formation as a late complication. Although the rate of granuloma formation has decreased significantly due to product evolution from Arteplast to Artecoll to Artefill, it remains a concern that needs to be addressed.</p>	<p>Poor</p>	

Appendix A. Cont'd

Study	Design	Country/population type	Sample size	Follow-up	Treatment	Injection description	Conclusions	Grade
Jham et al. PM:19138600	Case reports and comprehensive literature review	Various/General population	56		Various	Upper/lower lip, NLF, cheek		Poor
Nelson et al.2008 PM:18023267	Retrospective case series	UK/ Patients with HIV- associated lipodystrophy	46 (46)	Ranged from 1-14 mo	Coleman autologous fat injection n=26 Newfill n=10 Bio-Alcamid n=8 Treatment (e.g., liposuction) for fat accumulation	Newfill injections were performed by a trained nurse specialist. One vial of Newfill per cheek was injected to the deep dermis of affected areas (i.e., cheek, temple) during each treatment session. Bio-alcamid injections were performed in a theatre environment. The product was injected until total correction of the deficit was obtained.	Based on their experience, the researchers concluded that they favored the use of autologous fat injections for facial lipodystrophy but have found fillers to be useful in patients with inadequate fat reserves.	Poor
Parada et al.2005 PM:16276149	Histologic preparations from 11 biopsies collected over a two year period.	Brazil	11	Not reported	n=13 (Results not provided for this review)	Biopsies fixed in 10% formalin.  Restylane (hyaluronic acid), Metacril (polymethylmethacrylate), Aquamid (polyacrylamide), New-Fill (polylactic acid), Artecoll (polymethylmethacrylate suspended in a collagen solution).	The authors postulate that increasing numbers of "bizarre foreign body-type granulomatous reactions in the oral facial regions of middle-aged women" are due to injections with one or more of these fillers.	Poor

**Case Series/Report: No. of studies, 10**

<p>Salles et al. 2008 PM:18454007</p>	<p>Retrospective case series</p>	<p>32</p>	<p>5 yr since treatment</p>	<p>Polymethyl-methacrylate</p>	<p>Nose, penis, nasolabial fold, gluteus, malar and submalar regions, abdomen, periocular, frontal depressed scar, frontal region and chin, glabella, lip</p>	<p>Poor</p>
<p>Brazil/ 7 males and 25 females with an average age of 43.6</p>					<p>The authors state that compared to the number of successful cases of polymethylmethacrylate injections, complications are rare, however, despite being rare, these complications were severe, permanent, and difficult or even impossible to treat. For this reason, the authors state that some safety guidelines should be observed, such as avoiding high volumes and avoiding intradermal and intramuscular injections. The authors do not advise injection in the lips or in the body (gluteus or penis).</p>	<p>167</p>
<p>Zielke et al. 2008 treated areas in 48 PM:18177399</p>	<p>Case series The author's data support prior treatments of dermafillers who developed a reaction in one or more of the treated areas</p>	<p>Germany/patients with the need for females, n=1 males); 8 patients were excluded so that n=48 remained for further analysis</p>	<p>56 (n=55 Poor hyaluronic acid, and non biodegradable filler, PMMA, polyacrylamide gel, and polyethylene</p>	<p>Not reported patients Nasolabial fold (n = 67), followed by the lips (n = 27), corners of the mouth (n = 27), and glabella (n=16)</p>	<p>Biodegradable filler, good postmarketing surveillance that will lead us to a better understanding of the nature and risks of injectable filler substances and their side effects. Especially nonbiodegradable products have to be carefully monitored, since the adverse events associated with these products are especially difficult to</p>	<p>167</p>

Appendix A. Cont'd

Study	Design	Country/population type	Sample size	Follow-up	Treatment	Injection description	Conclusions	Grade
<b>Silicone Oil Fillers</b> Chasan 2007 PM:18090770	<b>Systematic Review: No. of studies, 1</b> Systematic review	USA	N/A	N/A	Silicone oil	N/A	In its current use, silicone oil for permanent soft tissue augmentation could be a very powerful tool. There is some literature that supports the use of a small amount of purified, high viscosity silicone oil; however, there has not been a single longitudinal study to date with appropriate follow-up data. The unanswered question remains: Are the risks worth the potential benefits of silicone oil as a permanent filler? However, there is still a lack of long-term follow-up data.	Poor
<b>Uncontrolled Clinical Trial: No. of studies, 1</b> Jones et al. 2004 PM:15458523	Open pilot trial	United States and Canada/Patients with stable, well-controlled HIV	77	N/A	Silikon 1000 or Vitresil 1000 n=77	Cheeks for treatment of facial lipoatrophy 376 total injection among 77 patients	Pilot trial has demonstrated that highly purified 1000-cSt silicone oil is a safe and effective treatment option for human immunodeficiency virus facial lipoatrophy. Longer-term safety and efficacy in human immunodeficiency virus patients remains to be proven.	Poor
<b>Case Series/Report: No. of studies, 4</b> Jacinto 2005 PM:16416637	Retrospective case series	Philippines/patients undergoing	206 cases (191 cases)	NA	Silicone Oil 0.5 - 4.6 ml	Intradermal injections for acne and postvaricella scars	Silicone oil injected with the correct indications and techniques and with microdroplet injections is a safe, economical, and permanent dermal and subcutaneous filler.	Poor

Deep dermal injections for nasolabial grooves, glabellar frown lines, inframalar creases and depressions, marionette lines, and sleep lines

**Silicone Oil Fillers**

**Case Series/Report: No. of studies, 4**

Author/PMID	Study Design	Location	No. of Patients	Duration	Intervention	Findings	Conclusion	
Parada et al. 2005 PM:16276149	Histologic preparations from 11 biopsies collected over a two year period.	Brazil	11	Not reported	Restalyne (hyaluronic acid), Metacril (polymethyl-methacrylate), Aquamid (polyacrylamide), New-Fill (polylactic acid), Artecoll (polymethyl-methacrylate suspended in a collagen solution). Botulinum toxin type A (Botox) n=1 Collagen n=1 Dimethylpolysiloxane (silicone) n=3	Biopsies fixed in 10% formalin.	The authors postulate that increasing numbers of "bizarre foreign body-type granulomatous reactions in the oral facial regions of middle-aged women" are due to injections with one or more of these fillers.	Poor
Poveda et al. 2006 PM:16388285	Retrospective case series	Spain/55-yr-old woman, 72 year old woman, 70 year old woman, 54 year old woman, 43 year old woman	5	1 mo	Injections into the lower and upper lip, nasogenian area, facial area, cheeks, chin, and buccal mucosa.	The authors feel that these fillers should not be considered innocuous. The reaction to silicone is the most virulent, but adverse reactions have been observed with practically all the products used. They say that more studies are necessary to study other possible bodily responses to silicone.	Poor	

Appendix A. Cont'd

Study	Design	Country/population type	Sample size	Follow-up	Treatment	Injection description	Conclusions	Grade
Requena et al.2001 PM:11391099	Retrospective case series	Spain/52 yr old man, 42 yr old woman, 2 38 yr old women	4	6-14 mo	Artecoll n=1 Dermalive n=1 Silicone n=2	Artecoll: nasolabial and forehead folds Dermalive: forehead and periocular ridges Silicone: nasolabial folds, cheeks	Artecoll and Dermalive are able to stimulate a clinically evident granulomatous reaction in rare cases, even though they are composed of mostly inert materials. Silicone, contrary to popular opinion, is beneficial and safe when it is used properly in small amounts for cutaneous soft tissue	Poor
<b>Other Fillers</b>								
<b>Systematic Review: No. of studies, 1</b>								
Kosowski et al. 2009 PM:19483584	Systematic review	US/Patients who received elective facial cosmetic procedures (e.g., injectable fillers, implants, botulinum toxin treatment) to improve facial	9 questionnaires to assess facial appearance	N/A	Injectable fillers Implants Botulinum toxin	Not reported	Valid, reliable, and responsive instruments designed to measure patient-reported outcomes following surgical and nonsurgical facial rejuvenation are lacking. A patient- reported outcome measure that represents perceptions of facial cosmetic surgery patients and satisfies accepted health measurement criteria is	Poor
<b>Randomized Controlled Trial (RCT): No. of studies, 1</b>								
Sciafani et al.2002 PM:12437432	RCT	US/patients with age- related changes in the size and contour of the lip	44 (44)	3, 6, 9, 12 mo	Cymetra n= 19 Zyplast n=25	Injection to the upper lip between the orbicularis oris muscle and the overlying mucocutaneous junction of the upper lip	Cymetra increases the upper lip bulk, vermilion, and lower lip projection	Good

**Uncontrolled Clinical Trial: No. of studies, 7**

Bjarnsholt et al. 2009 PM:19709133	Uncontrolled clinical trial	Denmark/patients with adverse reactions after injection of polyacrylamide gel	8	14q - 2yr since injection	n=7 Aquamid n=1 Interfall	n=3 lip n=1 penis n=1 breast n=1 tear trough n=1 nasolabial fold n=1 cheek	Results presented in this report support the idea that routine bacterial culture swabs detect only a fraction of the bacteria in reactive tissues injected with polyacrylamide gel. The fact that one biopsy did not show any bacteria did not exclude possibility of an infection.	Poor
de Cassia et al. 2003 PM:14612994	Clinical trial	Sweden/patients undergoing facial augmentation	59	2-16 mo (9 mo avg)	Aquamid	Injection subcutaneously by retrograde linear tracing injection technique for lip augmentation, cheekbone enlargement, deep nasolabial folds, glabella, chin	Aquamid gives a properly increased volume with natural elasticity and viscosity	Poor

**Other Fillers**

**Uncontrolled Clinical Trial: No. of studies, 7**

Han et al. 2006 PM:16508353	Clinical Trial	Korea/ patients undergoing augmentation rhinoplasty	11 (6)	12 mo	Cultured human fibroblasts suspended in Restylane 0.6-1.0 ml	Injection into the subcutaneous layer of the nasal dorsum	Restylane with suspended cultured human fibroblasts has the potential to be used as a long-lasting injectable soft-tissue	Poor
Treacy et al. 2006 PM:16792645	Clinical Trial	US/HIV patients with facial lipodystrophy	11 (11)	3 and 18 mo	BioAcamid polyallylimide gel 15.0-30.0 cm3	Polyallylimide gel injected into the buccal, malar, and temporal areas of the face, superficial to the superficial musculo-poneurotic	Polyallylimide gel injections can lead to significant clinical and behavioral improvements in HLS patients	Poor

Appendix A. Cont'd

Study	Design	Country/population type	Sample size	Follow-up	Treatment	Injection description	Conclusions	Grade
von et al.2005 PM:16163108	Clinical Trial	Denmark, Germany, Italy, Netherlands, Spain, Sweden/ Patients undergoing facial augmentation and enhancement of facial contours due to aging, acne, trauma, or surgery	251 (228).	7, 28 d 3, 6, 12 mo	Aquamid 0.2-12.0 ml	Gel administered through the subcutaneous tissue using a thin needle. Injection starts as the needle is withdrawn from the nasolabial and glabella folds, depressed corners of the mouth, perioral wrinkles, lip, chin, cheeks, nose, and vermilion border	Aquamid is an easy to use soft tissue filler with long-lasting tissue enhancement for at least 12 mo	Poor
von et al.2006 PM:16936548	Uncontrolled clinical trial	Germany/patients with mean age of 48yrs, 8% male	251 (101)	24 mo	Aquamid	Nasolabial and glabella folds, depressed corners of the mouth, and perioral wrinkles Facial contouring, lip augmentation	The efficacy of polyacrylamid hydrogel for facial soft-tissue augmentation was as good at the 2yr following as that seen at the 12mo visit. Thus, the authors state that a long-lasting effect after injection of Aquamid can be	Poor



Wolters et al. 2009 PM:19207323	Prospective, multicenter trial	Germany/General population	251 (81)	36 to 48 mo	Cross-linked polyacrylamide hydrogel	Various facial contouring locations, not explicitly reported	Whereas biological fillers are completely or partially reabsorbed through enzymatic degradation, requiring repeated injections for permanent filling effects, synthetic fillers are not degraded and produce permanent results after one or few injections, but doctors have been hesitant to use nondegradable fillers, because a number of adverse reactions have been reported. The polyacrylamide hydrogel filler was still well tolerated after 36 to 48 months with no long-term unexpected adverse events and no loss of filler	Poor
------------------------------------	--------------------------------	----------------------------	----------	-------------	--------------------------------------	--	--	------

**Cohort Study: No. of studies, 4**

Honig 2008 PM:18650737	Cohort study	Germany/ Nonrelated HIV seropositive patients with facial LA	9	median 2 yr	Bio-Alcamid, 7 to 25 ml in cheek 1 to 3 ml in NLF 1 to 2 ml in lip line	NLF, cheek, lip line	The present study strongly suggests that Bio-Alcamid is suitable for the correction of remarkable defects of facial atrophy, otherwise treatable only by surgery with myofascial free flaps. The authors recommend that complications from treatment with PAAG be studied further before widespread use of this soft tissue filler.	Poor
Kalantar-Hormozi et al. 2008 PM:19083518	Retrospective	Iran/Patients with a history of PAAG injections	600	2-5 yr	Polyacrylamide gel (PAAG)	542 in various facial locations	The authors recommend that complications from treatment with PAAG be studied further before widespread use of this soft tissue filler.	Poor

Appendix A. Cont'd

Study	Design	Country/population type	Sample size	Follow-up	Treatment	Injection description	Conclusions	Grade
Negredo et al. 2006 PM:17192148	Comparative, prospective cohort study	Spain/ HIV-infected patients presenting with antiretroviral-associated facial lipoatrophy for more than 6mos	138 (n=8 received fat, n=25 received poly-L-lactic acid, and n=105 received polyacrylamide gel)	96 wk	Analogous fat obtained by liposuction, 50ml Polylactic Acid, 3-14ml Polyacrylamide gel, 4-18ml	Nasolabial folds	The authors' conclude that polyacrylamide gel provides the longest lasting results of the three products compared. However, biodegradable products, such as fat and poly-lactic acid should also be considered as viable options for the treatment of facial lipoatrophy. The choice of the best product for reconstructive purposes should be made in concordance with a physician's clinical evaluation and the patient's preferences.	Fair
Reda-Lari 2008 PM:19083517	Retrospective assessment	Kuwait/Patients treated with PAHG for soft tissue augmentation of the malar area	2136	3 mo to 6 yr	Polyacrylamide hydrogel, 1.5 to 5 ml	Periorbital (tear trough, upper lid), temple, lateral face (gonial angle area), buccal, malar, nasal, nasolabial, lip and chin, or any combination of the above.	In the experience, PAHG is safe for facial soft tissue augmentation, as only a small number of side effects occurred during the follow-up period. PAHG provided sustainable and long-lasting results and high patient satisfaction rate. Longer follow up is necessary.	Poor

**Cross-sectional Study: No. of studies, 1**

Zappi et al. 2003  
PM:18086057  
Follow-up evaluation study  
US/Patients treated with LIS for depressed scars on the face  
35 samples (25 patients)  
1 to 23 yr  
Liquid injectable silicone (LIS), 0.05-0.2 ml  
Not reported.  
As a result of its high permanence and inertness, which is reflected by the lack of adverse reactions, silicone should be regarded as a valuable filler, at least for the correction of small depressed facial scars.  
Poor

**Case Series/Report: No. of studies, 16**

Amin et al. 2004  
PM:15606826  
Retrospective case report  
France/64 yr old female US citizen  
1  
5 mo  
Dermal injections of polyacrylamide gel in cheeks  
Polyacrylamide gel  
Poor

Apte et al. 2003  
PM:12972773  
Retrospective case report  
US/48 yr old woman  
1  
2 mo  
Cymetra (human cadaver collagen)  
Forehead  
Poor

Cheng et al. 2006  
PM:16547628  
Retrospective case series  
China/Women aged 24-45 yr  
15  
1-7 yr  
Face, breasts, legs  
Polyacrylamide gel  
Poor

The micronization of collagen in this product is sufficient to allow particulate collagen access to the coroidal vasculature.  
It is too early to assess the long-term efficacy of PAAg as a clinically safe, soft tissue filling material because of its unstable localization property in implant regions and its tendency to move easily in response to gravity and

Appendix A. Cont'd

Study	Design	Country/population type	Sample size	Follow-up	Treatment	Injection description	Conclusions	Grade
Descamps et al. 2008 PM:18446029	Case reports	France/patients with chronic hepatitis C treated with alpha- interferon	2	Case 1 - 5 yr post treatment Case 2 - 2 years post-treatment	Case 1 - unknown permanent dermafiller Case 2 - hyaluronic acid	Case 1 - mesolabial and nasolabial folds Case 2 - peribucaal and lion's wrinkles	The authors state that patients with sarcoidosis and patients infected with HCV should be aware of the risk of foreign body granulomas and be excluded from any filler injections. The authors also feel that a blood test for HCV should be undertaken before injection a derma filler.	Poor
Goldman 2009 PM:19207334	Case Report	USA, Italy/46 yr old woman	1 (1)	2 d following final treatment through 10mo following final treatment	Aquamid (Polyacrylamide gel) 3.0ml in 2002 0.7ml in August 2004 1ml in August 2005 1ml in February 2005 0.8ml in October 2007 1ml in November 2007	-Upper and lower lips during 2 separate sessions, 2wks apart in 2002  -nasolabial fold in August 2004 -nasolabial fold and upper lip in August 2005  -upper and lower lip and nasolabial fold in February 2005  -lips in October 2007 -lips in November 2007	Authors believe that patient presents the first case report of pressure-induced migration of a permanent soft-tissue filler, and the authors suspect that the pressure generated by injection of biodegradable fillers to augment lip size forced a dissection along tissue planes of the permanent encapsulated filler.	Poor

**Case Series/Report: No. of studies, 16**

Author(s) and PMID	Study Design	Location/Population	Number of Patients	Follow-up	Intervention	Results	Conclusion	
Grimaldi et al. 2008 PM:18650738	Case Report	Italy/50 yr old female with Romberg syndrome of the left face, which she has had for 20yrs	1	Not reported	Polyglactic acid and fat from the abdominal area	Of fat: - 15 ml in the right zygomatic region -25 ml in left cheek -10 ml in buccal rime -5 ml in the left upper eyelid -15 ml in the left temporal area	Results obtained in this report prove the efficacy of combining skin thickening using polyglactic acid with the Coleman technique for reconstructing three- dimensional project of face contour to restore the superficial density of facial tissues. The authors state that the satisfaction of the patient confirms the quality of the results.	Poor
Jham et al. PM:19138600	Case reports and comprehensive literature review	Various/General population	56		Various	Upper/lower lip, NLF, cheek		Poo
Kanchwala et al. 2005 PM:15985788.	Retrospective Case Series	US/patients undergoing facial augmentation	976	3, 6, 9, 12	Autologous fat n=697 Hylaform n=52 Restylane n=86 Radiesse n=141	Nasolabial folds, lips, glabella	Successful fat transplantation appears to be the preferred method for the treatment of volume loss to the face.	Poor
Karagozoglu et al. 2008 PM:18313268	Case report	Netherlands/39 yr old woman referred by her dentist because of a small mobile submucosal swelling in the left cheek	1	presented 3 yr since treatment; follow up of 6mos post presentation	Aquamid (polyacrylamide gel)	Nasolabial fold	In this case both surgeon and pathologist were misled by the initially negative history of the patient and by the histopathologic aspects of the biopsy specimen, even mimicking mucoepidermoid carcinoma. Apparently, cosmetic interventions have become so common in our society that neither doctors nor patients may ask about or mention them. Some patients may be reluctant to disclose such procedures to their doctor.	Poor

Appendix A. Cont'd

Study	Design	Country/population type	Sample size	Follow-up	Treatment	Injection description	Conclusions	Grade
Kawamura et al. 2006 PM:16545711	Retrospective case report	Brazil/61 yr old white woman	1	8-14 mo	Single dose Aquamid (2.5% polyacrylamide)	Single dose of Aquamid injected in the nasolabial fold.	First case in author's knowledge of an intraoral foreign body reaction resulting from Aquamid application in the nasolabial fold.	Poor
<b>Case Series/Report: No. of studies, 16</b>								
Lahiri et al.2007 PM:17485056	Retrospective case report	UK/18 male 16 female, aged 21-59	12		1.5-110 ml Bio-Alcamid (synthetic polymeric polyakylimide, enclosed with collagen)	Injections for facial and chest wall deformities	Alcamid is very encouraging for facial lipoatrophy, chest wall deformities, as an adjunct to breast reconstruction, and correction of other types of congenital and acquired contour deformities. The complication rates were very low.	Poor
none;2008 PM:18451755	Case reports	USA/healthy females	3	case 1 - 10 d case 2 - 13dys case 3 - 14dys	Case 1 - unknown for first treatment; dermal silicone for second treatment Case 2 - silicone derma filler, 500ml each buttock in first treatment and then 400ml in second treatment Case 3 - unknown soft tissue filler	Case 1 - buttocks Case 2 - buttocks Case 3 - buttocks	Practitioner who performed all original treatments was found to not have a medical license and was subsequently arrested after investigation.	Poor

Parada et al. 2005 PM:16276149	Histologic preparations from 11 biopsies collected over a two year period.	Brazil	11	Not reported	Restylane (hyaluronic acid), Metacril (polymethylmethacrylate), Aquamid (polyacrylamide), New-Fill (polylactic acid), Artecoll (polymethylmethacrylate suspended in a collagen solution), Permacol (xenograft)	Biopsies fixed in 10% formalin.	The authors postulate that increasing numbers of "bizarre foreign body-type granulomatous reactions in the oral facial regions of middle-aged women" are due to injections with one or more of these fillers.	Poor
Pitkin et al. 2008 PM:19206141	Case series	UK/patients undergoing rhinoplasty augmentation	45	1 wk, 1 mo, and every 3-6mos posttreatment; at time of report, median follow-up time for patients was 13 mos	Permacol (xenograft)	nasal region	Authors present the first reported series of Permacol use in augmentation rhinoplasty. Authors state that because longer term follow-up of patients is required before definite conclusions can be drawn on its long-term success, they conclude that the use of Permacol as an alternative to autogenous cartilage graft in augmentation rhinoplasty deserves further evaluation.	Poor
<b>Case Series/Report: No. of studies, 16</b>								
Rosner et al. 2009 PM:19207327	Retrospective case series using Berlin registry data on adverse reactions to injectable fillers	Germany/Patients treated with a methacrylate based filler who developed a reaction in the same area	34	N/A	Dermalive (hydroxyethylmethacrylate and ethylmethacrylate in a fixed combination with hyaluronic acid)	Fillers injected in 95 areas among the 34 patients. Common areas: NLFs (46.3%) Corners of the mouth (17.9%) Glabella (17.9%) Upper lip (12.6%)	Dermalive is a long-lasting injectable filler with a biodegradable part (HA) and a nonbiodegradable part (methacrylate). Although these ingredients are widely accepted as compatible substances, the study was able to show a large number of patients developing adverse	Poor

Appendix A. Cont'd

Study	Design	Country/population type	Sample size	Follow-up	Treatment	Injection description	Conclusions	Grade
Zielke et al. 2008 PM:18177399	Case series	Germany/patients with prior treatments of dermafillers who had developed a reaction in one or more of the treated areas	56 (n=55 females, n=1 males); 8 patients were excluded so that n=48 remained for further analysis	Not reported	Biodegradable filler, hyaluronic acid, and non biodegradable filler, PMMA, polyacrylamide gel, and polyethylene	167 treated areas in 48 patients Nasolabial fold (n = 67), followed by the lips (n = 27), corners of the mouth (n = 27), and glabella (n=16)	The author's data support the need for good postmarketing surveillance that will lead us to a better understanding of the nature and risks of injectable filler substances and their side effects. Especially nonbiodegradable products have to be carefully monitored, since the adverse events associated with these products are especially difficult to treat.	Poor



Appendix B. ASPs/AAD evidence tables with outcome measures and conclusions, listing studies by dermal filler type and study type

Study	Country/population type	Sample size	Follow-up	Treatment	Injection description	Outcome measures	Adverse events
<b>Hyaluronic Acid Fillers</b>							
<b>Systematic Review: No. of Studies, 1</b>							
Price et al, 2007 PMID:17466613	UK	N/A	N/A	HA	N/A	N/A	Associated with minor but real problems.  Allergy is the most important complication, but ubiquity of HA is expected to circumvent this. It is not uncommon to observe transient erythema and mild swelling. A recent review quoted an overall significant complication rate of one in 1600 applications.
<b>Randomized Controlled Trial: No. of Studies, 25</b>							
Baumann et al., 2007 PMID: 18086050	USA/Subjects at least 30 yr and with fully visible bilateral NLFs that were approximately symmetrical (both moderate or both severe)	439 (423)	24 wk	HA: Juvéderm 30 (J30), Juvéderm Ultra (24HV), Juvéderm Ultra Plus (30HV); median, 1.6 ml (range, 0.8–5.6 ml); Zylplast (cross-linked bovine collagen), median, 2.0 ml (range, 0.8–7.7 ml)	Subjects were randomly assigned to receive one of the three smooth-gel HA fillers; intradermally to the NLF on one side of the face. In all subjects, the NLF on the other side of the face was treated with Zylplast. The vast majority of subjects had only one treatment visit.	1. Five-point WAS 2. Efficacy 3. Patient satisfaction	Frequency and severity of treatment-site reactions were similar for all fillers. There were no treatment-related AEs events other than those localized to the area of injection.  In all treatment groups, the majority of reactions at the treatment site were mild to moderate in severity, did not require intervention, and lasted 7 days or less. There was one significant AE reported: sterile abscess at the injection site occurring 4 mo after treatment with bovine collagen. AE patterns and incidence were similar between Caucasian and non-Caucasian subjects.
Beer, 2007 PMID: 17661935	USA/Women	15 (15)	2 wk, 3, 4.5, 6 mo	Restylane (HA gel), 0.7–2.1 ml Hylaform, 1.6 ml Hylaform, 1.6 ml (average) (n = 150)	A physician or nurse administered a randomly assigned treatment to one side of each patient's NLF and the other treatment to the NLF on the opposite side.	1. WSRS score 2. GAIS score	AEs associated with both HA gel and Hylan B Plus injections included bruising, redness, swelling, pain, itching, and nodules. All were of mild to moderate severity and lasted several days.

Appendix B. Cont'd

Study	Country/population type	Sample size	Follow-up	Treatment	Injection description	Outcome measures	Adverse events
Carruthers et al., 2005 PMID:16416643	Canada/Patients seeking cosmetic correction of moderate to severe nasolabial folds	150(140)	3, 4, 5, 6 mo	Restylane Perlane, 1.3 ml (average) (n = 150) Hyalofarm, 1.6 ml (average) (n = 150)	Contralateral injection of each filler into the mid or deep dermis nasolabial folds	1. WSRS score 2. GAIS score	Swelling, pain, and redness were the most common and occurred more frequently in Restylane Perlane than in Hyalofarm (41.3% vs. 21.3%).
Carruthers et al., 2003 PMID:12859378	Canada/Adult female subjects with moderate to severe glabellar rhytides	38	32 wk	NASHA (Restylane) (n = 19) Botulinum toxin type A + NASHA (1 wk later) (n = 19)	1 cm above the supraorbital notch (on both sides) 2. Global improvement at 16 wk	1. Median time for return to preinjection furrow	Mild adverse events reported by a majority of the subjects, related to mild to moderate tenderness and swelling in both groups. No significant difference between the two groups.
Dessy et al., 2008 PMID:18833043	Italy/Patients with clear signs of premature facial aging	100	1, 3, 6, 12 mo	Wipeline (HA concentration, 1.6%) Wipeline (HA concentration, 2.0%)	Site: fold and wrinkles in the face Three sessions with 4-wk intervals between them	VAS score to evaluate turgidity, elasticity, and luminosity.	Products were well tolerated and no adverse reactions were observed.
Glogau et al., 2008 PMID:18547173	USA/General population	283	12 wk	Restylane (NASHA, small) (n = 142) Perlane (NASHA, large) (n = 141)	Midface volume correction of the NLFs and oral commissures (marionette lines)	AEs only	Total of 336 local-related AEs 12 wk of follow-up treatment. Most common were bruising, tenderness, edema, and pain.
					1021 total injection sites Touch-up injections after. In patients injected with Perlane, were discouraged to parallel clinical practice, where correction is usually completed in a single session.		Incidence of local AEs was higher at 72 hr after injection compared with 2 wk after. In patients injected with Perlane, all AEs were resolved by week 2.

Goldman et al., 2007 PMID: 17451575	USA/Patients with prominent nasolabial folds	36 (33)	56 days	Restylane, alone and in combination with laser/RF/IPL	Nasolabial folds (treated with HA gel implantation on one side of the face and HA gel followed by one of the nonablative laser/RF/IPL therapies on the contralateral side of the face)	Clinical efficacy using Severity Rating Scale (1–5) between HA alone and those treated with concomitant HA/laser/RF/IPL. Patient self-assessment using GAIS (0–4) between HA alone and those treated with concomitant HA/laser/RF/IPL.	There were six AEs reported during this study. Two of these, a serious AE of myocardial infarction (of moderate intensity) and a nonserious event of anemia (of mild intensity), were considered unrelated to the study. Three adverse experiences (herpes simplex virus reactivation on the upper lip, mild erythema after IPL, and bruising) were probably related to the study and were of mild intensity. Another adverse experience (palpable cheek lump) possibly related to study treatment was also of mild intensity. The subject with bruising did not receive treatment on day 14 but completed the rest of the study.
Grimes et al., 2009 PMID: 19735512	USA/Patients with Fitzpatrick skin types IV, V, or VI	Study 1: 160 Study 2: 119	24 wk	Study 1: Juvéderm Ultra, Ultra Plus, and 30 and Zyplast collagen	Nasolabial folds  Study 2: Hyaliform, Hyaliform Plus, and Captique	1. Nasolabial fold severity	Study 1: There were no occurrences of hypersensitivity or hypertrophic scarring, and no increased incidence of hyperpigmentation or hypopigmentation in non-Caucasian vs. Caucasian subjects. Study 2: There was no occurrence of keloid formation, hypertrophic scarring, hypopigmentation, or hypersensitivity, and three instances of mild hyperpigmentation.
Hamilton et al., 2007 PMID: 18086056	USA/Patients undergoing dermal augmentation of NLFs	433	0, 6, 24 wk	Restylane  Perlane	Both NLFs	1. ID-ST, IgE anti-NA SHA immunoassay  2. Serologic results 3. 24-wk ID-ST biopsies	42 systemic adverse experiences were reported by 37 participants. All but one were judged by investigators to be unrelated to NASHA administration.
Kono et al., 2008 PMID: 18547178	Japan	10 (10)	3, 6, 9, 12 mo	Restylane, SCHA (n = 10) Puragen, DCHA (n=10)	One side of each patient's glabellar lines was treated with SCHA and the other side was treated with DCHA.	1. Clinical efficacy 2. Comparison	Not reported
Levy et al., 2009 PMID: 19207322	France/Subjects with moderate to severe bilateral NLFs	60	None	Juvéderm Ultra 3, with/ without preincorporated lidocaine; 0.62 ml	For each subject, the NLF on one side was randomly assigned to treatment with HA + lidocaine, and the opposite to treatment with HA gel alone.	1. Physician assessment pain 2. Subject assessment of pain 3. Ease of injection	Severity and frequency of injection-site reactions were similar for both treatments and localized. Most were mild to moderate in severity, did not require intervention, and lasted <5 days.

Appendix B. Cont'd

Study	Country/population type	Sample size	Follow-up	Treatment	Injection description	Outcome measures	Adverse events
Lindqvist et al, 2005 PMID: 15622265	Norway and Sweden/ Patients with prominent NLFs	68 (43)	2, 4, 6, 9, 12 mo	Perlane (n = 68) (one nasolabial fold) Zyplast (n = 68) (contralateral nasolabial fold)	Intradermal injection to the NLFs	1. WRSRS assessment 2. GAIS score	Only minor adverse events at 6 mo and none at 12 mo.
Lupo et al, 2008 PMID: 18176233	USA/Subjects presenting with severe NLF rated as 3 or above	87 (82)	4, 8, 12, 16, 20, 24, 48 wk	Juvéderm Ultra Plus (HA), 1.7 ml for initial treatment, 0.6 ml for repeated treatment Zyplast (bovine collagen)	Subjects randomized to treatment with Juvéderm Ultra Plus in one NLF and Zyplast in the opposite NLF 70 (81%) of subjects returned for complimentary/repeated treatment with Juvéderm Ultra Plus, performed between 24 and 36 wk	1. Efficacy, initial treatment period 2. Patient satisfaction, initial treatment period 3. Efficacy, repeated treatment period	Occurrence of treatment-site reactions was similar for uvéderm Ultra Plus and Zyplast. Majority of individual reactions lasted no more than 7 days, were mild or moderate in severity, and required no further intervention. Examples: Erythema, induration, pain, edema, nodule, bruising, pruritus, and discoloration.
Man et al, 2008 PMID: 18430173	Canada/Female patients who demonstrated dermal thinning of the dorsal hands	10 (10)	1 wk, 1, 3, 6 mo	Restylane (HA), 1.4 ml (n = 10) CosmoPlast (Collagen), 2.0 ml (n = 10)	Patients were randomized to received two vials to either their right or left hand. Two vials of collagen were administered into the contralateral hand.	1. Tolerability (0-3) 2. Patient satisfaction (1-5) 3. Clearance Score (1-5), assessed by four blinded independent board-certified investigators	Adverse side effects reported with injections included pain, tingling, and bruising. One patient experienced a nodule formation at the collagen injection site that resolved by 6 mo.

Moers-Carpi et al., 2007 PMID: 18086052	Europe/Enrolled patients had moderate or severe NLFs	205 (192)	4, 8, 12 mo	<p>Radiesse (CaHA), 2.21 ml total volume (n = 70)</p> <p>Juvéderm 24 (HA-1A), 4.78 ml total volume (n = 33)</p> <p>Juvéderm 24HV (HA-1B), 2.94 ml total volume (n = 33)</p> <p>Perlane (HA-2), 2.89 ml total volume (n = 65)</p>	<p>Patients treated with either CaHA gel or HA for the correction of both NLFs. Nearly all patients (n = 189) received a touch-up treatment at 4 mo.</p>	<p>1. Patient satisfaction</p> <p>2. Investigator GAIS analysis</p> <p>3. WRSR analysis</p>	<p>No serious adverse events requiring intervention were reported at any time points for any of the injected materials.</p>
Moers-Carpi et al., 2008 PMID: 18093199	Germany and Spain/ Moderate to severe NLFs (3 or on WRSR)	60 (58)	6, 9, 12 mo	<p>Radiesse</p> <p>Restylane</p> <p>Volume required for correction in CaHA-treated fold was 30% less than the volume of NASHA.</p>	<p>Patients received two injections 3 mo apart. At the initial visit, patient was treated with CaHA to correct one NLF and NASHA to correct the other NLF. At the 3-mo visit, patients received a touch-up treatment in both folds.</p>	<p>1. GAIS ratings</p> <p>2. Blinded evaluators rating</p>	<p>Both products were safe and well tolerated. No serious events were reported with either treatment.</p> <p>Four AEs were reported: two hematomas, one nodule, and one extrusion (of 118 folds injected two times each during the course of the study). The two hematomas resolved in 4–5 days with no further complications. The nodule was treated with 0.2 ml of triamcinolone acetonide and was cleared in 14 days. The extrusion appeared in an NASHA-treated fold. It was treated with antibiotics and resolved without complications.</p>
Narins et al., 2003 PMID: 12786700	USA/Correction of nasolabial folds	138 (138)	2, 4, 6 mo	<p>Restylane (n = 138)</p> <p>Zyplast (n = 138)</p>	<p>Injection of each material to contralateral nasolabial folds</p>	<p>1. WRSR</p> <p>2. GAIS</p>	<p>Treatment-related AEs were reported in 38.4% of patients because of local injection-site reactions (26.8% in Restylane and 39.1% in Zyplast).</p>
Narins et al., 2007 PMID: 18086061	USA/Subjects with asymmetrical NLFs classified as grade 2 or greater on MFWS	164 (149)	6 mo	<p>Dermicol-P35 (n = 149)</p> <p>Restylane (NASHA) (n = 149)</p>	<p>NLFs</p> <p>Dermicol-P35: mean, 1.48 ml; 72 received touch-up injections (0.59 ml)</p> <p>Restylane: mean, 1.16 ml; 73 received touch-up injections (0.45 ml)</p>	<p>1. MFWS assessment</p> <p>2. Improvement of at least 0.5 in the MFWS</p> <p>3. Blinded investigator GIA evaluation</p> <p>4. Subject GIA evaluation</p>	<p>Local skin reactions: Erythema, pain, swelling, bruising, pruritus, induration were expected and observed in most subjects at one or more time points.</p> <p>Erythema was the most frequently reported treatment reaction.</p> <p>Overwhelming majority of injection-site reactions were of 4 days' duration or less, with almost all of them resolving within 1 wk.</p>

Appendix B. Cont'd

Study	Country/population type	Sample size	Follow-up	Treatment	Injection description	Outcome measures	Adverse events
Narins et al., 2008 PMID: 18547177	USA/Patients with moderate to severe NLFs	75 (63)	18-mo interim of a 30-mo study	Restylane Patients were then randomized to retreatment at 4.5 mo and retreatment of the other NLF at 9 mo.	All patients received an injection in both NLFs at the first visit, with touch-up injections as needed at the 2 wk follow-up visit.	1. Evaluator's rating on the WSRS	No allergic reactions were reported by patients in either treatment group. AEs were reported by 33% of participants. The most common were swelling (23%) and/or bruising (20%) at the injection site. AEs resolved over time, and no treatment-related AE was rated as serious.
Narins et al., 2008 PMID: 18547179	USA/Clinical evidence of 149 bilateral aging defects in the nasolabial area with wrinkles rated as 2 or greater	149	6, 9, 12 mo	Dermicol-P35 (n = 149) Restylane (HA) (n = 149)	Each NLF received one filler; one touch-up injection could be given after 2 wk to obtain an optimal cosmetic result.	1. Persistence of nasolabial fold correction (improvement from baseline in the MFWS was at least 0.5 point) with Dermicol- P35 2. Blinded investigator global improvement ratings	Before 6 mo: 5 (3.4%) of Dermicol-P35; 1 (0.7%) of HA At 6 mo: 2 (1.4%) of Dermicol-P35; 1 (0.7%) of HA On investigator examination of subjects at the 9- and 12-mo follow-up were mild erythema and mild nodule formation. At the 12 mo follow-up, 123 subjects elected to have a re correction filler injection; 58 chose to receive Dermicol-P35, and 65 chose to receive HA. Local adverse events occurring after these re correction injections were 11 (19.0%) in Dermicol-P35 and three (4.6%) in HA. None was considered severe or serious and all were anticipated local adverse events
Onesti et al., 2009 PMID: 19454518	Italy/25 to 80 yr with marked nasolabial folds	84 (68)	14 days, 2, 4, 6 mo	Puragen (n = 84) Captique (n = 84)	Depth of injection and the volume to be injected were at the operator's discretion. Each patient received Puragen in one NLF and Captique in the contralateral fold, in a totally random fashion.	1. WSRS 2. GAIS	After initial treatment, adverse reactions at injection point were 92% for Puragen and 90.3% for Captique, mainly of a mild to moderate intensity and short-lived. During the 6-mo follow-up, adverse reactions were observed exclusively at the injection site in 14.7% of Puragen patients and 11.8% of Captique patients.  Complications arising 14 days after the last treatment had a similar incidence between the two products. All delayed-onset complications subsided spontaneously within a period of 2 mo of treatment.

Pinsky et al, 2008 PMID: 19083502	USA/Subjects with fully visible NLFs	292 (280)	6, 9 mo	Juvéderm Ultra/ Juvéderm Ultra Plus (n = 292)  Zyplast bovine collagen (n = 292)	1.5 ml for initial treatment, 0.7 ml for repeated treatment	1. Investigator assessment of NLF severity 2. Clinically significant improvement at 9 mo	No serious treatment-related AEs were reported with any of the fillers. For both treatment groups, most treatment-site reactions (e.g., erythema, induration, pain, edema, nodule formation, bruising, pruritus, and discoloration) were mild or moderate in severity and did not require intervention.
Rao et al, 2005 PMID: 16416642	USA/Patients undergoing correction of NLFs	8	12 wk	Restylane 0.7 ml (n = 8)  Hylaform 1.0 ml (n = 8)	Contralateral injection of each filler into the mid or deep dermis NLFs	1. Subject satisfaction score 2. Blinded independent reviewer assessment of improvement	Not reported
Vartanian et al, 2005 PMID: 16027343	USA/General population	12 (8)	120 days	1. Hyaluronidase and saline (n = 12) 2. Three different doses of hyaluronidase	Hyaluronidase injected in cutaneous areas previously injected with HA (Restylane)	1. Size of augmentation created by injected Restylane 2. Cutaneous augmentation	25% of patients demonstrated localized, self-limiting hypersensitivity reactions to injected hyaluronidase.
Weinkle et al, 2009 PMID: 19735519	USA/Patients receiving injections to the NLFs	72 (72)	2 wk	Juvéderm, 1.6 ml (maximum) (n = 72) Juvéderm lidocaine, 1.6 ml (maximum) (n = 72)	Injection of Juvéderm and Juvéderm Pain at injection site in the Juvéderm arm lidocaine to contralateral NLF	1. Procedural pain on an 11-point scale 2. NLF severity at 2 wk using the WAS	Pain at injection site in the Juvéderm arm

**Uncontrolled Clinical Trial: No. of Studies, 13**

Arlotte et al, 2008 PMID: 18547183  
Canada/Subjects undergoing Mohs' micrographic surgery for basal cell carcinoma of the NLF area  
16

Not reported  
Juvéderm  
NLF  
1. Anatomical location of injected HA gel  
Not reported

Appendix B. Cont'd

Study	Country/population type	Sample size	Follow-up	Treatment	Injection description	Outcome measures	Adverse events
Bugge et al., 2007 PMID: 17944679	Norway/HIV-infected patients older than 18 yr with severe nasogenian atrophy	20 (19)	52 wk	Restylane SubQ, 1.5–2.0 ml in each cheek; 13 patients also received a touch-up treatment of Restylane SubQ, 1.0 ml at wk 4	Patients received an injection in each cheek in the nasogenian area. All injections were performed by the same plastic surgeon at an outpatient clinic.	1. Total cutaneous thickness (epidermal, dermal, and subcutaneous thickness) in the nasogenian area using standardized ultrasonography 2. GAIS score 3. VAS score 4. Rosenberg Self-Esteem	Most patients experienced some local swelling and tenderness on the first 1–3 days after treatment and some had local redness.  Eight patients had palpable lumps after treatment, of which some were visible. In three patients, the lumps were still present at wk 53. One patient reported fever, redness, swelling, and vesicles on his right cheek 2–3 days after treatment. He recognized the vesicles as recurrent herpes zoster and self-treated with acyclovir. Following the touch-up treatment, he had a similar reaction (without vesicles) on his left cheek, which was resolved after 2–3 days without medical treatment.
Carruthers et al., 2005 PMID: 15841626	Canada/Nonpregnant, non-breast-feeding women aged 25–60 yr with prominent downturned mouth corners	15 (14)	1 wk, 3, 4, 5, 6 mo	Restylane, 0.44 ml (average upper lip) and 1.49 ml (average lower lip)	Serial puncture using a ad" technique across the lateral part of the upper and lower lip plus intradermal extension from each lateral commissure	1. Self-assessment 2. Evaluation by an independent aesthetic judge using standardized criteria	Pain, redness, swelling, lump, superficial aggregate of material, and canker sore were all reported after injection but disappeared shortly thereafter.  Three subjects reported postinjection herpes labialis.
Delorenzi et al., 2006 PMID: 16442040	Canada/Patients seeking chin and/or cheek augmentation with no aesthetic facial surgery in the past 12 mo	57	1, 3, 6, 9, 12 mo	Restylane 10.0 ml (maximum) Average injection of 2.2 ml (cheek) and 2.1 ml (chin)	Subcutaneous and/or supraperiosteal injections	1. Efficacy measured using the five-grade GAIS by the investigator and patient	Implantation complications occurred in eight patients. Three patients had their implants removed within 3 mo because of skin induration.



DeLorenzi et al., 2009 PMID: 19207320	Canada/General population	57	1, 3, 6, 9, 12 mo	Restylane SubQ Mean volumes injected were 2.1 ml into each cheek and 2.2 ml into each chin	98 cheeks and 16 chins 13 patients received touch-up injections at 20 sites.	1. GAIS assessment performed by patient 2. GAIS assessment performed by investigator	Treatment-related AEs of predominantly mild intensity were reported in 58% of patients. The most commonly reported events were local injection-site reactions such as swelling, tenderness, redness, bruising, pain, and pruritus; 26% reported skin induration, and 19% reported implantation complications. 70% of events appeared in the day of treatment or following day. Skin in duration was frequently delayed onset, mild intensity but long lasting, persisting for approximately 4 mo on average.
Denton et al., 2007 PMID: 17418252	Canada/HIV-positive men with facial lipoatrophy; mean age, 47.2 yr	18 (14)	12 mo	Perlane, 2.1 ml per side of the face	Nasolabial folds, submalar region	Facial assessment using photography and seven-point Likert scale	There were a total of 17 AEs in 14 patients, including erythema beyond 1 wk, discomfort, palpability of product, telangiectasia, ecchymosis, oozing following injection, severe injection pain, and hypersensitivity.
Duranti et al., 1998 PMID: 9865196	Italy/Patients undergoing augmentation therapy for wrinkles	158 (158)	1, 2, 4, 8 mo	Restylane, 1.4 ml (average)	Injection to the mid dermis of the glabella, NLFs, oral commissure, and/or lips	1. Subjective assessment by physician, patient, and photographic method 2. Foreign body reaction	Swelling (n = 13) Erythema (n = 7) Edema (n = 5) Discomfort (n = 5) Tenderness (n = 3) Bruising (n = 3) Itching (n = 1) Pain (n = 1)
Han et al., 2006 PMID: 16508353	Korea/Patients undergoing augmentation rhinoplasty	11 (6)	12 mo	Cultured human fibroblasts suspended in Restylane, 0.6–1.0 ml	Injection into the subcutaneous layer of the nasal dorsum	1. Appearance of reconstructed noses, degree and time of resorption, and occurrence of complications 2. Patient satisfaction using a VAS form	Mild degree of dorsal deviation in one patient

Appendix B. Cont'd

Study	Country/population type	Sample size	Follow-up	Treatment	Injection description	Outcome measures	Adverse events
Judodilhardjo et al., 2008 PMID: 18547174	UK/General population	25 (22)	24 hr; 4, 12 wk	Teosyal (HA), ~0.83 ml per NLF	Single injection into each nasolabial fold	1. WSRS 2. GAIS 3. Clinical inflammation scales for erythema and edema assessed by a dermatologist 4. Erythema meter, assessed by spectrophotometer (Mexameter) 5. Skin temperature, assessed by infrared ter 6. Subject discomfort, assessed by a 100-mm VAS	Mild inflammation
Kerscher et al., 2008 PMID: 18384619	Germany/Skin types I–IV sagging/slackening facial skin, actinic elastosis, loss of skin elasticity, >30 yr	20 (19)	4, 8, 12, 24 wk	Restylane, 1.0 ml	Eligible patients received bilateral injections of HA in the lower part of the cheeks in three sessions (start, 4, 8 wk) Serial puncture technique, approximately 50 0.02-ml injections per session	1. Patient satisfaction 2. Elasticity 3. Skin surface morphology 4. Skin thickness and density	No serious AEs occurred during the course of the study, and no patients withdrew because of an AE. Four patients developed transient, mild hematomas after injection. Two patients experienced temporary, mild erythema after injection (lasted 2 wk). One patient developed a nodule approximately 3 mm in diameter after the second injection.
Lowe et al., 2006m PMID: 16875468	USA and UK/Patients requesting augmentation of the upper cheek or chin contour	72 (72)	64 wk	Restylane SubQ, 3.9 ml	Percutaneous injection; slowly injected with palpation; five to eight injection tunnels created with deposition	1. Patient and physician satisfaction	Transient hematoma developed in two patients. One patient had a small-volume local extrusion of material at the medial aspect of one cheek. One patient had some mobility in the Implant.

Olenius, 1998 PMID: 9502839	Sweden/Patients undergoing soft-tissue augmentation for facial wrinkles	113 (100)	1, 2, 12, 26 wk; 12 mo	Restylane (glabellar lines, mouth)	NLFs, material angle wrinkles, generic facial lines	1. Safety of the injection 2. Efficacy of treatment evaluated by a VAS from 0–100	Moderate redness, spots, swelling Discoloration Pain
Reuther et al., 2009 PMID: 19730872	Germany/Healthy women aged ≥30 yr with loss of skin elasticity	19	16 wk	Restylane Vital (NASHA), 1.0 ml at each of three treatment sessions	Bilateral injections in lower part of the facial cheeks	12 parameters describing the viscoelastic properties of the skin using the suction chamber principle	Four patients developed transient, mild hematoma after injection. Two patients developed temporary, mild erythema. One patient developed a nodule approximately 2 mm in diameter that persisted for approximately 2 wk before disappearing without treatment.

**Cohort Study: No. of Studies, 4**

Distante et al., 2009 PMID: 19207331	Italy/Healthy women with mild to moderate brachial ptosis	16	90 days	Restylane Vital, 1 ml per session per arm	Arm Three sessions at intervals of 30 days (T0, T30, T60) Follow-up occurred at T90.	1. Hydration 2. Skin thickness 3. Elasticity	No unexpected AEs were reported. All expected treatment-related AEs, such as discomfort at the injection site, bruising, and hematoma, were of mild intensity. No serious AEs were reported.
McCracken et al., 2006 PMID: 16714927	USA/Patients at nine American Society of Ophthalmic Plastic and Reconstructive Surgery practices	286 (286)	N/A	Restylane Nasolabial folds, 0.8 ml (n = 234) Melolabial folds, 0.5 ml (n = 54) Vermillion border, 0.5 ml (n = 198) Lip volume enhancement, 0.6 ml (n = 144) Glabellar folds 0.3 ml, (n = 18)	Various facial locations: NLFs melolabial folds, vermilion border, lip volume enhancement, glabellar folds	Physician perception of patient satisfaction on a scale from 1–10 (low–high)	Local complications of bruising, swelling, bumpiness, asymmetry, and redness

Appendix B. Cont'd

Study	Country/population type	Sample size	Follow-up	Treatment	Injection description	Outcome measures	Adverse events
Raspaldo, 2008 PMID: 18788032	France/Patients presenting with hollow subpalpebral grooves, malar descent, flat cheekbones, hollow temporal areas, scar depression, or chin retrusion	102	6–18 mo	Juvéderm Voluma, volume injected based on baseline volume loss score	Midface region: Submalar/subpalpebral area (central midface) and malar area (lateral midface)	1. GAIS investigator assessment of volume restoration 2. Investigator assessment of the overall volumizing effect 3. Patient assessment of aesthetic effect	Nine temporary AEs were recorded in eight patients, which lasted between 3 and 42 days. Reported cases were swelling, hematoma, overcorrection, and hypersensitivity. Only one patient required antiinflammatory medication for treatment.
Wahl, 2008 PMID: 19146607	16 European countries/Patients injected with a resorbable dermal filler in the previous 18 mo	3566	Not reported	HA filler incorporating lidocaine (HAL); mean, 1.1 ml	NLF region	1. Injector-assessed ease 2. Patient-reported pain levels (British Pain Scale) 3. Injector-rated aesthetic effect	Occurred in 6% of subjects, all of which were temporary in nature.
<b>Cross-Sectional Study: No. of Studies, 1</b>							
Andre, 2004 PMID: 15196154	France/Patients receiving NASHA injections	4320	N/A	Restylane Perlane	Various	Not reported	34 cases of hypersensitivity reactions were reported with 16 immediate sensitivity and 18 delayed sensitivity. No bacterial infection Up to 4% incidence of herpetic recurrences Discoloration of the skin if the product is placed too superficially
<b>Case Series/Report: No. of Studies, 39</b>							
Alijotas-Reig et al., 2008 PMID: 18211407	Various/Patients with severe, delayed side effects related to HA-AH	25	up to 60 mo	HA alone (n = 16) HA-AH compounds (n = 9)			Reports on 25 cases; patients with intermediate or delayed-onset side effects related to cosmetic/aesthetic implant fillers Average latency time, 13.7 mo (range, 1–60 mo)

Author(s), Year, PMID	Country	Age	Sex	Time since treatment	Product	Region	Reported	Findings
Al-Shraim et al., 2007 PMID: 17761744	USA	62-yr-old	woman	10 mo since treatment; 6 mo following removal of nodule	Restylane	Mandible region	Not reported	1-cm subcutaneous nodule overlying the lower third of the mandible
Anwar et al., 2007 PMID: 17549561	UK	41-yr-old	white woman	36 mo	DermaLive (60% hyaluronic acid)	Injections for nasolabial wrinkles		Delayed swelling at injection site that gradually increased in size
Arron et al., 2007 PMID: 17760694	Hungary	59-yr-old	Caucasian woman	1 yr	Matridur and Matrigel (NASHA)	Melolabial folds, glabella, lips, and perioral rhytides	Not reported	2 days after treatment, patient noted significant swelling and pain at the injection sites; swelling progressed and 5 days after treatment, patient was admitted to the hospital for significant facial edema. Patient presented to the author's clinic 2 mo after treatment with notable edema with erythema of the glabella and melolabial folds and was treated with hyaluronidase. Reaction resolved completely by 1 yr after injection of hyaluronidase.
Bardazzi et al., 2007 PMID: 17760694	Italy	54-yr-old	woman	2 yr 2 mo	Restylane	Melolabial folds		After 2 yr of continuous, trouble-free use, one treatment resulted in a granulomatous reaction in the melolabial folds.
Bosniak et al., 2004 PMID: 15545531	Brazil	Patients undergoing lip augmentation and facial rhytide ablation		24 hr; 1 and 2 wk; 3, 6, 9 mo	Restylane, 1.4 cm <sup>3</sup> (maximum)	Injected superficial to the middle dermal layer with the needle inserted bevel up. For linear depressions, serial punctures were combined with a linear threading technique. For broader depressions, fanning or cross-hatching techniques were used, supplemented with serial punctures.	1. Satisfaction scale (0-3)	Transient erythema at injection site

Appendix B. Cont'd

Study	Country/population type	Sample size	Follow-up	Treatment	Injection description	Outcome measures	Adverse events
de Lacerda et al., 2007 PMID: 18086060	Brazil/Two women, aged 45 and 52 yr	2	Case 1: 1 yr Case 2: 4 mo	Glabellar area (n = 185) Nasolabial folds (n = 1020) Oral commissure (n = 352) Lips (n = 685)  Case 1: Evolence (porcine collagen), 2 ml Case 2: Voluma (HA), 2 ml	Injections to the glabellar area, NLFs, oral commissure, and lips  Case 1: Nose, NLFs, and lips Case 2: Nose, NLFs, lips	2. Physician evaluation of glabellar, NLFs, and oral commissure using the 4 degrees of rhytide reduction (0–3) 3. Physician evaluation of lips using pretreatment/posttreatment photographic comparison of volume and contour characteristics (0–3)  Not reported	Case 1: None reported  Case 2: Minimal edema that disappeared by day 5 after treatment
Descamps et al., 2008 PMID: 18446029	France/Patients with chronic hepatitis C treated with interferon alfa s	2	Case 1: 5 yr after treatment Case 2: 2 yr after treatment	Case 1: Unknown permanent dermal filler Case 2: HA	Case 1: Mesolabial and nasolabial folds Case 2: Peribuccal and lion's wrinkles	Not reported	Case 1: Sarcoidal granulomas present in nodules found in the legs, edema in the face with infiltrated masses in the mesolabial and nasolabial folds present with granulomas with vacuolated macrophages, pulmonary function tests reveal decrease in the diffusion capacity of carbon monoxide (58% of normal value), and tuberculin energy was observed.

Case 2: Edema and infiltrated nodules with purpura in the lips and the injected areas; biopsy confirmed foreign body granuloma, interferon and ribavirin were discontinued but later cirrhosis was diagnosed and interferon and ribavirin were given again; patient developed sicca symptoms and edema and purpuric infiltrated lesions flared up again, biopsy was typical of sarcoidosis; chest CT scan demonstrated pulmonary sarcoidosis with lymphadenopathy and micronodules were confirmed by gallium.

Case 1: 1 wk after treatment, patient noted an undesirable blue/gray discoloration toward the medial portion of the melolabial folds.  
Case 2: Bluish discoloration along marionette lines that did not subside 1 yr after treatment  
Case 3: Patient complained of bluish bumps on the vermilion border 2 wk after injections.

Discrete nodules on upper lip  
12 showed bruising and three had small filler lumps that were treated with massage (no serious complications).  
In 1999, 222 AEs in 144,000 patients treated; majority were hypersensitivity reactions and injection-site inflammation; other rare reports of localized granulomatous reactions, bacterial infections, and acneiform and cystic lesions.  
In 2000, 144 AEs in 262,000 patients; majority were hypersensitivity reactions and injection-site inflammation; two cases of injection-site necrosis; other rare reports of localized granulomatous reactions, bacterial infections, and acneiform and cystic lesions.

Douse-Dean et al., 2008 PMID: 18380210	USA/Women between 43 and 3 50 yr old	2 wk-1 yr	Case 1: HA Case 2: HA Case 3: HA	Case 1: Melolabial fold rhytides Case 2: Marionette lines Case 3: Vermillion border	Not reported	Case 1: 1 wk after treatment, patient noted an undesirable blue/gray discoloration toward the medial portion of the melolabial folds. Case 2: Bluish discoloration along marionette lines that did not subside 1 yr after treatment Case 3: Patient complained of bluish bumps on the vermilion border 2 wk after injections.
Fernandez-Acenero et al., 2003 PMID: 14725668	Spain/48-yr-old woman	2 mo	Restylane	Injection of Restylane in upper lip	Not reported	Discrete nodules on upper lip
Fezza, 2008 PMID: 18317150	USA/Caucasian, fair-skinned patients with lower eyelid cicatricial ectropion	1 yr	Restylane, 1 cc	Eyelid	Rate of success	12 showed bruising and three had small filler lumps that were treated with massage (no serious complications).
Friedman et al., 2002 PMID: 12081677	Europe, Canada, Australia, South America, Asia/AEs to NASHA	NA	Restylane, Perlane, Restylane Fine Lines	Not reported	Not reported	In 1999, 222 AEs in 144,000 patients treated; majority were hypersensitivity reactions and injection-site inflammation; other rare reports of localized granulomatous reactions, bacterial infections, and acneiform and cystic lesions. In 2000, 144 AEs in 262,000 patients; majority were hypersensitivity reactions and injection-site inflammation; two cases of injection-site necrosis; other rare reports of localized granulomatous reactions, bacterial infections, and acneiform and cystic lesions.

Appendix B. Cont'd

Study	Country/population type	Sample size	Follow-up	Treatment	Injection description	Outcome measures	Adverse events
Furmanczyk et al., 2009 PMID: 19207330	USA and Thailand/58-yr-old (1) man	4- and 8-wk intervals	Dermalive	Not reported	Not reported		Violaceous nodules across forehead, glabella, temples, nasolabial folds, and marionette lines Many nodules had comedones, pinpoint pustules, and scabs. Foreign body granulomas
Ghislanzoni et al., 2006 PMID: 16536824	Italy/41-yr-old woman	1	5 wk-3 mo	Restylane (HA)	27-gauge needle longitudinal injection to the melolabial, glabellar, and periorbital wrinkles		Erythematous nodules developed simultaneously at all sites of injection 5 wk after treatment, showing dense multinodular infiltration of the dermis and subcutaneous fat.
Godin et al., 2006 PMID: 16549735	USA/Patients undergoing facial saugmentation	101 (61)	10 mo	Radiesse and Restylane (n = 29)	Injection to the nasolabial folds, upper and lower lip vermilion borders, "lipstick lines," and perioral lines	Immediate and long-term patient satisfaction survey (10-point scale)	Not reported
Goldberg et al., 2006 PMID: 16985414	USA/155 patients, (41 men and 114 women with average age of 53 yr)	155 (121)	6-12 mo	Restylane; mean injections were: 0.96 ml at first injection 0.87 ml at second injection 0.78 ml at third injection	Orbital rim, zygomatic and septal confluence hollows in the tissue plane deep to the orbicularis oculi muscle	Patient satisfaction	Bruising occurred in 22% of injections, with 9% of injections resulting in patients who objected to the color change. Lumps or contour irregularities are almost uniformly present; however, most patients found the effect acceptably smooth. Five developed doughy edema in the malar area.
Hirsch et al., 2007 PMID: 17373195	USA/43-yr-old woman	1	2 wk	Juvéderm	Multiple deep dermal injections along the NLFs using a linear threading technique		48 hr after injections, the patient reported pain in the treated area and her face "looked like a pizza."



Inoue et al., 2008 PMID: 18317097	Japan/50-yr-old woman with no prior cosmetic surgery	1	43 days	Restylane and Sheba (collagen)	Nasal lip (Restylane) and upper lip and NLF and upper vermilion (collagen)	Not reported	Immediately after the injection of collagen, the patient had striking pain on the left side of her face. A few hours later, she noticed reddish discoloration from the left side of the nose and upper lip to the glabellar region, which corresponded to the area nourished by the angular branch of the facial artery. By the third day of onset, blisters had appeared at the left nasal ala. When the patient consulted a hospital on the sixth day, a gangrenous skin necrosis measuring 1 × 1.5 cm was present on the left nasal ala. The necrosis extended to the surrounding skin and subcutaneous tissue, and was removed surgically on day 12. A full-thickness skin graft taken from the postauricular area was grafted to the residual skin defect on day 43 and was successfully accepted.
Jacano, 2008 PMID: 18209119	USA/Consecutive patients presenting to a facial plastic and reconstructive surgery practice for injectable lip augmentation	66 patients receiving 137 treatments	9 mo	Restylane	Vermilion, subvermilion, peristomal, philtral column, and oral commissure	Mean satisfaction score Mean persistence until lips returned to preoperative appearance based on patient subjective evaluation	None reported
Jham et al., 2009 PMID: 19138600	Various/General population	56		Various	Upper/lower lip, NLF, cheek	Not reported	Clinical presentation: Single nodule, diffuse swelling, multiple nodules, mass, other Treatments: Excisional biopsy, steroids (systemic and intralesional), antibiotics, nonsteroidal antiinflammatory drugs, uricosuric agent, immunoregulator
Jordan, 2005 PMID: 16234715							

Appendix B. Cont'd

Study	Country/population type	Sample size	Follow-up	Treatment	Injection description	Outcome measures	Adverse events
Kanchwala et al., 2005 PMID: 15985788	USA/Patients undergoing facial augmentation	976	3, 6, 9, 12 o	Autologous fat (n = 697) Hylaform (n = 52) Restylane (n = 86) Radiesse (n = 141)	NLFs, lips, glabella	1. Type of product used 2. Anatomical region injected 3. Infection rate 4. Touch-up/revision rate and overall longevity	Not reported
Kane, 2005 PMID: 16151656	USA/24 women aged 35–56 yr	24	10 days	0.1–0.45 ml Restylane (n = 23)	30-/32-gauge injection of Restylane in the lower eyelid	Patient satisfaction	The woman to receive Hylaform had heavy swelling and discoloration of the treatment area for 2 wk.
Lennox et al., 2007 PMID: 17966181	USA/46-yr-old woman presented for evaluation of cosmetic issues following mastectomy and silicone implant reconstruction	1	4 wk	Juvéderm Ultra, 0.4 ml into each nipple in each of two treatment sessions	Nipples	Not reported	None reported
Lowe et al., 2007 PMID: 17852625	USA/32-yr-old woman with mildly atrophic upper lip and melomental folds	1 (1)	1 hr after treatment	Restylane, 1.5 cc	Filler was injected in the upper lip and melomental area after 1% lidocaine nerve block was given for anaesthesia	Change in lip volume using three-dimensional photography imagery (Surface Imaging Ltd and Canfield Scientific Vectra 3D Volumetric Analysis)	Localized swelling as assessed by the three-dimensional imagery
Malhotra, 2007 PMID: 18071111	USA/Patients from 18–36 yr old	5	6–9 mo	Restylane Sub-Q (HA), 2 ml each at two treatments	Intraoral and extraoral posterior orbit	Not reported	One patient required hyaluronidase for migrating gel, which caused lower eyelid swelling; one patient required orbital magnetic resonance imaging 9 mo after injection, and volumetric analysis based on coronal and axial cuts.

Nyte, 2007 PMID: 17580805	USA/50-yr-old man presented with long history of nasal obstruction	1	2 days	Restylane, 0.15 ml	Caudal-medial surface of the upper lateral cartilage of the nasal valve Upper lateral cartilage of the nasal valve	Not reported	Minor middle vault discomfort and swelling or days after treatment
Oduunze et al., 2007 PMID: 18090767	USA/Patients with average age of 56 yr	60 (n = 45 Fitzpatrick I-III, n = 20 Fitzpatrick IV-VI)	6-9 mo	Restylane	Injections to the dermal-epidermal junction of the NLFs; forehead, glabella, arionette lines, and scars using serial threading; serial puncture used at tear trough, cheek, and oral commissure	Comparisons between Fitzpatrick I-III and Fitzpatrick IV-VI cohorts	Of Fitzpatrick I-III, no permanent adverse outcomes; however, two patients had transient sequelae and one patient had idiopathic angioedema of the lips for 36 hr; one patient also had inclusion cyst that required drainage.
Parada et al., 2005 PMID: 16276149	Brazil	11	Not reported	Restylane (HA), MetaCrill (polymethylmethacrylate), Aquamid (polyacrylamide), New-Fill (polylactic acid), Artecoll (polymethylmethacrylate suspended in a collagen solution)	Biopsy specimens fixed in 10% formalin		Restylane: An inflammatory process occurred on the deep reticular dermis, hypodermis, and at the level of the dermal musculature. Periadnexal and perivascular lymphomononuclear infiltrates were observed in the superficial and deep dermis, in addition to numerous eosinophils. Aquamid: Inflammatory infiltrates were observed on the deep reticular dermis, hypodermis, and dermal musculature. MetaCrill: A focal or diffuse inflammatory infiltrate at the reticular dermis and hypodermis was observed. New-Fill: A connective tissue presented diffuse inflammatory infiltrate. Artecoll: A connective fibrous and striated muscular tissue presented with dense and diffuse inflammatory infiltrate. Liquid Silicone: Fibrillar connective tissue presented with diffuse inflammatory infiltrate.

Appendix B. Cont'd

Study	Country/population type	Sample size	Follow-up	Treatment	Injection description	Outcome measures	Adverse events
Patel et al., 2006 PMID: 16651928	USA/65-yr-old woman	1	1 yr	Restylane, 0.7-ml syringe	30-gauge injections in the NLFs, lips, and perioral rhytides		Extensive erythema, edema, and induration of the injection regions of the NLFs and perioral areas occurred 12 wk after fourth treatment.
Peter et al., 2006 PMID: 16764658	Germany/48-yr-old man	1	18 mo	Restylane	Glabella area and the cheeks		One minute after last injection, patient reported partial visual loss in his right eye. A retinal branch artery occlusion of the superior temple artery was identified.
Requena et al., 2001 PMID: 11391099	Spain/52 yr old man, 42 yr old woman, 2 38 yr old women	4	6-14 mo	Artecoll (n = 1) Dermalive (n = 1) Silicone (n = 2)	Artecoll: Nasolabial and forehead folds Dermalive: Forehead and periorcular ridges Silicone: Nasolabial folds, cheeks		Artecoll: Erythematous, ribbed, palpable indurations of both nasolabial and forehead folds Dermalive: Erythematous palpable indurations on forehead Silicone: Erythematous palpable indurations of both nasolabial folds, palpable indurations on both cheeks with mild erythema
Rosnerr et al., 2009 PMID: 19207327	Germany/Patients treated with a methacrylate-based filler who developed a reaction in the same area	34	N/A	Dermalive (hydroxyethyl-methacrylate and ethylmethacrylate in a fixed combination with HA)	Fillers injected in 95 areas among the 34 patients Common areas: NLFs (46.3%) Corners of the mouth (17.9%) Glabella (17.9%) Upper lip (12.6%)	Not reported.	In the 34 patients, the methacrylate filler was injected into 95 areas. Of these 95 areas, 87 (91.6%) showed a reaction. The most frequently observed adverse events were the development of nodules (n = 85), discoloration (n = 39), erythema or inflammation (n = 32), and swelling (n = 24). Most nodular reactions were rated as severe. Mean time of onset was 23.1 (SD 22.8) mo.
Schweiger et al., 2008 PM: 18318726	USA/21-yr-old woman with cleft lip, prior to treatment had received 12 reconstructive procedures by craniofacial surgeons; complained of lip asymmetry	1	~4 mo	Restylane, 0.7 ml	Upper lip	Not reported	None reported

Sidwell et al., 2004 PMID: 15550141	UK/40-yr-old white woman	1	8, 12 mo	Dermalive (synthetic hyaluronic acid and acrylic hydrogel)	Injections of Dermalive to the nasolabial folds	Firm red linear lines developed 4 mo after procedure along the sites of the injections.
Soparkar et al., 2005 PMID: 15778672	USA/62-yr-old woman	1	7 and 17 days, 5 mo	Two 0.7-ml syringes of Restylane	NLFs	Progressive swelling, pain, warmth, and erythema along one of the two injection sites after 7 days. Prescribed methylprednisolone over 6 days. Immediately after stopping medicine, patient reported rapid exacerbation of her symptoms.
Taban et al., 2009 PMID: 19617780	USA/Infants with congenital eyelid malpositions	5 (5)	Mean follow-up, 11.8 mo	Restylane, 0.5 ml per eyelid	HA gel was injected in small amounts across the length of the upper or lower eyelid	Complications were minor and included transient ecchymosis, edema, contour irregularities, and tenderness at the sites of injection. Overall, there was a non-statistically significant decrease in margin reflex distance 1 and/or margin reflex distance 2, without obstruction of the visual axis. One patient had increased astigmatism on one side (2.00 diopters with the rule) after treatment.
Vargas-Machuca et al. 2006 PMID: 16625084	Spain/50-yr-old woman	1	1 yr 2 mo	Dermalive	Perioral skin	4 mo after injections, patient noted erythematous papules that progressively augmented in size and indurated.
Wolfram et al., 2006 PMID: 17135735	Austria/Two 58-yr-old women, one 53-yr-old woman	3	3 mo-2 yr	Newfill, Restylane, Dermalive	Zygomatic arch, eyelids, forehead, NLFs, cheeks	Erythematous indurations at injection sites

ASPS, American Society of Plastic Surgeons; AAD, American Academy of Dermatology; N/A, not applicable; PMID, PubMed identification number; HA, hyaluronic acid; USA, United States; NLF, nasolabial fold; AEs, adverse events; WRSR, Wrinkle Severity Rating Scale; GAIS, Global Aesthetic Improvement Scale; WAS, Wrinkle Assessment Scale; VAS, visual analogue scale; NASHA, non-animal-stabilized hyaluronic acid; ID-ST, intradermal skin test; IgE, immunoglobulin E; RF, radiofrequency; IPL, intense pulsed light; SCHA, single cross-linked hyaluronic acid; DCHA, double cross-linked hyaluronic acid; CaHA, calcium hydroxylapatite; MFWS, Modified Fitzpatrick Wrinkle Scale; GIA, Global Improvement Assessment; CT, computed tomographic; HIV, human immunodeficiency virus; AH, acrylic hydrogel.

Appendix B. Cont'd

Study	Country/population type	Sample size	Follow-up	Treatment	Injection description	Outcome measures	Adverse events
<b>Collagen Fillers</b>							
<b>Randomized Controlled Trial: No. of Studies, 13</b>							
Baummann et al., 2007 PMID: 18086050	USA/Subjects at least 30 yr old and with fully visible bilateral NLFs that were approximately symmetrical (both moderate or both severe)	439 (423)	24 wk	HA: Juvéderm 30 (J30), Juvéderm Ultra (24HV), Juvéderm Ultra Plus (30HV); median, 1.6 ml (range, 0.8–5.6 ml)  Zyplast; median, 2.0 ml (range, 0.8–7.7 ml)	Subjects were assigned randomly to receive one of the three smooth-gel HA fillers, intradermally to the NLF on one side the NLF on one side subjects, the NLF on the other side of the face was treated with intervention, and lasted 7 days or less. Zyplast.  The vast majority of subjects had only one treatment visit.	1. Five-point WAS 2. Efficacy 3. Patient satisfaction	Frequency and severity of treatment-site reactions were similar for all fillers. There were no treatment-related AEs other than those localized to the area of injection.  In all treatment groups, the majority of reactions at the treatment site were mild to moderate in severity, did not require intervention, and lasted 7 days or less. There was one significant AE reported: sterile abscess at the injection site occurring 4 mo after treatment with bovine collagen.  AE patterns and incidence were similar between Caucasian and non-Caucasian subjects.
Cohen et al., 2004 PMID: 15468406	USA/Patients at least 18 yr of age presenting for glabellar, NLF, radial upper lip line, marionette line correction	251 (251) (111 at 12mo)	1, 3, 6, 12 mo	Artecoll (n = 128) Zyderm II or Zyplast (n = 123)	Tunneling technique: Giabella, NLFs; radial upper lip lines, marionette lines	1. Cosmetic correction at 6 and 12 mo using the FFAS by three masked observers and physicians	27 AEs in Artecoll group; 38 AEs in collagen control group

Cohen et al., 2006 PMID: 16936546	USA/Patients with wrinkles of the glabella, nasolabial folds, radial upper lip lines, and corners of the mouth; treated with PMMA filler in pivotal RCT (Cohen 2004)	251 (233) (69 4-5 yr)	1, 3, 6, 12 mo 4-5 yr	ArteFill (amount not specified) (n = 128) Collagen (amount not specified) (n = 123)	Injection at the glabella, nasolabial folds, radial upper lip lines, or corners of the mouth	<ol style="list-style-type: none"> <li>1. Cosmetic correction</li> <li>2. Physician's assessment of success</li> <li>3. Facial Fold Assessment Scale rating</li> <li>4. Long-term cosmetic correction</li> <li>5. Physician's assessment of long-term success</li> <li>6. Safety and AE</li> </ol>	<ol style="list-style-type: none"> <li>1. Redness, swelling and lumpiness at the injection site for collagen</li> <li>2. 27 AEs for ArteFill vs. 38 AEs for collagen</li> <li>3. Six late AEs for ArteFill: Two severe and four moderate</li> </ol>
Grimes et al., 2009 PMID: 19735512	USA/Patients with Fitzpatrick skin types IV, V, or VI	Study 1: 24 wk 160 Study 2: 119		<p>Study 1: Juvéderm Ultra, Ultra Plus, and 30 and Zyplast and collagen</p> <p>Study 2: Hylaform, Hylaform Plus, and Captique</p>	Nasolabial folds	1. Nasolabial fold severity	<p>Study 1: No occurrences of hypersensitivity or hypertrophic scarring, and no increased incidence of hyperpigmentation or hypopigmentation in non-Caucasian vs. Caucasian subjects</p> <p>Study 2: No occurrence of keloid formation, hypertrophic scarring, hypopigmentation, or hypersensitivity, and three instances of mild hyperpigmentation</p>
Lindqvist et al., 2005 PMID: 15622265	Norway and Sweden/Patients with prominent NLFs	68 (43)	2, 4, 6, 9, 12 mo	Perlane (n = 68) (one NLF) Zyplast (n = 68) (contralateral NLF)	Intradermal injection to the nasolabial folds	<ol style="list-style-type: none"> <li>1. WSRS</li> <li>2. GAIS</li> </ol>	Only minor AEs at 6 mo and none at 12 mo
Lupo et al., 2008 PMID: 18176233	USA/Subjects presenting with severe NLF rated as 3 or above	87 (82)	4, 8, 12, 16, 20, 24, 48 wk	Juvéderm Ultra Plus (HA) 1.7 ml for initial treatment, 0.6 ml for repeated treatment	Subjects randomized to treatment with Juvéderm Ultra Plus in one NLF and Zyplast in the opposite NLF.	1. Efficacy, initial treatment period	Occurrence of treatment-site reactions was similar for Juvéderm Ultra Plus and Zyplast.

Appendix B. Cont'd

Study	Country/population type	Sample size	Follow-up	Treatment	Injection description	Outcome measures	Adverse events
Man et al., 2008 PMID: 18430173	Canada/Female patients who demonstrated dermal thinning of the dorsal hands	10 (10)	1 wk, 1, 3, 6 mo	Zyplast (bovine collagen)  Restylane (HA), 1.4 ml (n = 10) Cosmoplast (collagen), 2.0 ml (n = 10)	70 (81%) of subjects returned for complimentary repeated treatment with Juvéderm Ultra Plus, performed between 24 and 36 wk	2. Patient satisfaction, initial treatment period 3. Efficacy, repeated treatment period	Majority of individual reactions lasted no more than 7 days, were mild or moderate in severity, and required no further intervention.  Examples: Erythema, induration, pain, edema, nodule, bruising, pruritus, and discoloration
Monstrey et al., 2007 PMID: 17572579	Belgium and Israel/Patients with clinical evidence of bilateral aging defects in the nasolabial grade scale: class 0 = none, area grade scale: class 0 = none,	12	18 mo	Evolence, 1.72 ml Zyplast, 1.72 ml	Patients were randomized to received two vials to either their right or left hand. Two vials of collagen were administered into the contralateral hand.  NLFs	1. Tolerability (0–3) 2. Patient satisfaction (1–5) 3. Clearance Score (1–5), assessed by four blinded independent board-certified investigators  The wrinkle severity in the nasolabial area was scored by the two study physicians and by the patients on a four-class 1 = fine, class 2 = fine to moderate, and class 3 = moderate to deep.	Adverse side effects reported with injections including pain, tingling, and bruising  One patient experienced a nodule formation at the collagen injection site that resolved by 6 mo.  A total of 13 AEs were reported. None was related to study devices. Eight of the AEs were mild and the other five were of moderate severity.  AEs included hypersensitivity not related to the investigational product, gastroenteritis, herpes simplex, urinary tract infection, first-degree burn, limb injury, tendonitis, cheek papulae, nasal operation, varicose vein operation, and hypertension.



Narins et al., 2003 PMID: 12786700	USA/Correction of NLFs	138 (138)	2, 4, 6 mo	Restylane (n = 138) Zyplast (n = 138)	Injection of each material to contralateral NLFs	1. WSRS 2. GAIS	Treatment-related AEs were reported in 38.4% of patients because of local injection-site reactions (26.8% in Restylane and 39.1% in Zyplast).
Narins et al., 2008 PMID: 18547179	USA/Clinical evidence of bilateral aging defects in the nasolabial area with wrinkles rated as 2 or greater	149	6, 9, 12 mo	Dermicol-P35 (n = 149) Restylane (HA) (n = 149)	Each NLF received one filler, one touch-up injection could be given after 2 wk to obtain an optimal cosmetic result	1. Persistence of nasolabial fold correction (improvement from baseline in the MFWS was at least 0.5 point) with Dermicol-P35 2. Blinded investigator global improvement ratings	Prior to 6 mo: 5 (3.4%) of Dermicol-P35; 1 (0.7%) of HA At 6 mo: 2 (1.4%) of Dermicol-P35; 1 (0.7%) of HA On investigator examination of subjects at the 9- and 12 mo follow-up were mild erythema and mild nodule formation. At the 12-mo follow-up, 123 subjects elected to have a re correction filler injection; 58 chose to receive Dermicol- P35, and 65 chose to receive HA. Local AEs occurring after these re correction injections were 11 (19.0%) in Dermicol-P35, and three (4.6%) in HA. None was considered severe or serious and all were anticipated local AEs.
Sclafani et al., 2001 PMID: 11368660	USA/Patients not allergic to bovine collagen	10 (10)	1, 3, 6, 9, 12 mo	AlloDerm, 5.0 mm (n = 10) Zyplast, 0.5 ml (n = 10)	AlloDerm placed surgically in a subdermal plane in one postauricular crease Zyplast injected in a subdermal plane in the opposite postauricular crease	1. Volume 2. Histologic analysis	Not reported

Appendix B. Cont'd

Study	Country/population type	Sample size	Follow-up	Treatment	Injection description	Outcome measures	Adverse events
Sciafani et al., 2002 PMID: 12437432	USA/Patients with age-related changes in the size and contour of the lip	44 (44)	3, 6, 9, 12 mo	Cymetra (n = 19) Zyplast (n = 25)	Injection to the upper lip between the orbicularis oris muscle and the overlying mucocutaneous junction of the upper lip	<ol style="list-style-type: none"> <li>Changes in the nasolabial angle</li> <li>Percentage of the total lip accounted for by the exposed red lip in the midline and on the lateral view</li> <li>Visible red upper and lower lip surface areas</li> <li>Anterior projection of the upper and lower lips</li> </ol>	No significant local or systemic complications
Smith et al., 2007 PMID: 18086048	USA/Potential subjects were required to have symmetric, moderate to deep NLFs	117 (113)	1, 3, 6 mo	Radiesse (Collagen) Cosmoplast (CaHA)	Each side was treated until, in the judgment of the investigator, an optimal result was achieved. At 2 wk after treatment, subjects could receive touch-up injections at the discretion of the physician. Occurred at 2-wk intervals, maximum of two additional treatment sessions. Qualifying subjects received CaHA product on one side, and the HC product on the other.	<ol style="list-style-type: none"> <li>Number of injection sessions required: Baseline only</li> <li>Mean change in LRS from baseline, at 6 mo</li> <li>Subject-by-subject direct comparison, at 6 mo</li> <li>GAIS score of Improved, Much Improved, or Very Much Improved</li> <li>Investigator and subject preference</li> </ol>	<p>Safety analysis included all 117 subjects.</p> <p>Consistent with other injectable filler clinical studies, erythema, edema, and ecchymoses were some of the most common product-related AEs. Both edema and bruising were significantly more common on CaHA-treated sides than the HC side (<math>p &lt; 0.001</math>). These reactions lasted approximately 1 wk after any injection. Mean duration for erythema was 2–3 wk, with no significant difference between the two treatments.</p> <p>CaHA: One nodule; HC: three nodules. No granulomas, allergies, ulcerations or other serious adverse events were noted.</p>

**Controlled Clinical Trial: No. of Studies, 2**

Sciafani et al., 2000 PMID: 10925424	USA/Patients undergoing facial aesthetic surgery with skin excision	5 (3)	2, 4, 12 wk	Autologen, 0.5 ml (n = 5) Zyplast, 0.5 ml (n = 5)	Two injections of each material contralaterally to the postauricular area	1. Clinical persistence 2. Host tissue invasion	Not reported.
Sciafani et al., 2002 PMID: 12187346	USA/Healthy adults	20 (17)	4, 12 wk	Dermalogen, 0.1 ml (n = 20) Zyplast, 0.1 ml (n = 20)	Injection behind the contralateral ear	1. Persistence 2. Histologic identification	Inflammatory cells were identified at 4 wk in 12 Dermalogen and 19 Zyplast patients.

**Uncontrolled Clinical Trial: No. of Studies, 1**

Shoshani et al., 2007 PMID: 18086053	USA/General population	530	Evolvece, 30 min, 72 hr, 30 days	Enrolled subjects received an intradermal injection in the left forearm and a second injection in the right forearm after 2 wk.	1. Follow-up skin study assessments 2. Serum anticollagen antibody determinations 3. Hypersensitivity	95 adverse events were recorded in 62 subjects; 17 (17.9%) were considered related to implants. All were localized to implant sites, mild in nature, and transient.
---	------------------------	-----	----------------------------------	---	---	---

**Cohort Study: No. of Studies, 1**

Bouille et al., 2009 PMID: 19288692	Belgium, Sweden/Patients who had undergone Dermicol-P35 30G lip injections	57 Efficacy: 51	4–10 mo	Dermicol-P35 30G	Data collected from patients to enhance or restore the contour of the upper and/or lower lip in either the vermillion border, the body of the lip, or both.	1. Investigator assessment 2. Investigator satisfaction	At long-term follow-up, 95% of patients experienced no swelling, 100% experienced no bruising, 88% experienced no lumpiness, and 100% experienced no pain associated with treatment. When present, lumpiness was assessed as very slight or well-defined, not moderate or severe.
--	--	--------------------	---------	------------------	---	--	---

Appendix B. Cont'd

Study	Country/population type	Sample size	Follow-up	Treatment	Injection description	Outcome measures	Adverse events
<b>Case Series/Report: No. of Studies, 17</b>							
Braun et al., 2008 PMID: 18561590	USA/Female patients presenting to clinic for lip enhancement or augmentation	20	1 yr	Evolence, 1.0 ml	Body of lip, massage technique used immediately after injection	Not reported	There were no AEs immediately after treatment. Within 3 wk, patients contacted clinic expressing concern over "bumps" in their lips; examination indicated subcutaneous nodules varying in size from 2 to 5 mm in 16 patients; nodules were firm and slightly yellow in color. One patient developed four cystic pustules in her lips that enclosed a yellow, purulent material. Over 1 yr later, six patients still had nodules in their lips.
de Lacerda et al., 2007 PMID: 18086060	Brazil/Two women, aged 45 and 52 yr		Case 1: 1 yr Case 2: 4 mo	Case 1: Evolence (porcine collagen), 2 ml Case 2: Voluma (HA), 2 ml	Case 1: Nose, NLFs, and lips Case 2: Nose, NLFs, and lips	Not reported	Case 1: None reported Case 2: Minimal edema that disappeared by day 5 after treatment
Fischer et al., 2007 PMID: 17438184	Germany/48-yr-old woman	1	10 yr	Artecoll	Injections in the upper and lower lips, nasolabial grooves, and glabella		Treatment for chronic hepatitis C infection with peginterferon alfa-2a and oral ribavirin in same injection site as Artecoll injections 10 yr prior resulted in progressively disfiguring facial edema.
Hopkins et al., 2009 PMID: 19260892	UK/41 women and 17 men; mean age, 36 yr	58	Minimum follow-up was 6 mo, with 40 undergoing further review at 12 mo and 31 at 24 mo	Permacol (acellular cross-linked porcine dermal collagen)	Nasal region during rhinoplasty	Not reported	One case of postoperative infection; it is not clear whether this was directly related to the use of Permacol, which has not needed removal. One case of sterile cyst forming over graft 1 yr after treatment Two patients required minor revision from a cosmetic perspective.

Inoue et al., 2008 PMID: 18317097	Japan/50-yr-old woman with no prior cosmetic surgery	43 days	Restylane and Sheba (collagen)	Nasal tip (Restylane) and upper lip and NLF and upper vermilion (collagen)	Not reported	Immediately after the injection of collagen, the patient had striking pain on the left side of her face. A few hours later, she noticed reddish discoloration from the left side of the nose and upper lip to the glabellar region, which corresponded to the area nourished by the angular branch of the facial artery. By the third day of onset, blisters had appeared at the left nasal ala. When the patient consulted a hospital on the sixth day, a gangrenous skin necrosis measuring 1 × 1.5 cm was present on the left nasal ala.
Jham et al., 2009 PMID: 19138600	Various/General population	56	Various	Upper/lower lip, NLF, cheek	Not reported	The necrosis extended to the surrounding skin and subcutaneous tissue, and was removed surgically on the twelfth day. A full-thickness skin graft taken from the postauricular area was grafted to the residual skin defect on day 43 and was successfully accepted.
Kim et al., 2004 PMID: 15056148	Korea/Woman with Artecoll treatment for neck wrinkles	4 yr	Artecoll	Not reported	Not reported	Clinical presentation: Single nodule, diffuse swelling, multiple nodules, mass, other Treatments: Excisional biopsy, steroids (systemic and intralesional), antibiotics, nonsteroidal antiinflammatory drugs, uricosuric agent, immunoregulator
Landau, 2008 PMID: 18380205	Israel/Female patients with an average age of 52.3 yr	6 mo	Evolvec Breeze (porcine collagen-derived dermal filler), 1.4 ml	Lip and nasolabial folds	Patient reported satisfaction with results.	Artecoll-induced foreign granuloma (skin-colored plaques) in the neck Minimal swelling was noted after injection; transient lumpiness observed initially, it disappeared spontaneously by wk 4.

Appendix B. Cont'd

Study	Country/population type	Sample size	Follow-up	Treatment	Injection description	Outcome measures	Adverse events
Lombardi et al., 2004 PMID: 14720198	France/Patients with Artecoll, Dermalive, New-Fill, or Liquid-Silicone-induced granulomas	11	Not reported	Artecoll Dermalive New-Fill Liquid-Silicone	Not reported	Not reported	12 biopsy specimens taken: lips ( <i>n</i> = 6), cheeks ( <i>n</i> = 2) nasolabial folds ( <i>n</i> = 1), glabella ( <i>n</i> = 2), and lower eyelid ( <i>n</i> = 1).  All were either CFBGs or CMGs. All lesions were asymptomatic. Different types of CFBGs were related to various fillers: Type 1: Artecoll or Arteplast Type 2: Dermalive Type 3: New-Fill Type 4: Bioplastique.  CMGs were associated with Liquid-Silicone injections.
Luu et al., 2007 PMID: 17321875	USA/Patients who underwent laryngoplasty between 1997 and 2006	895	Not reported	Zyplast	Paraglottic compartment of the vocal folds	Safety of bovine cross-linked collagen in patients who are taking warfarin and also in patients without prior skin hypersensitivity testing	None reported
Moody et al., 2000 PMID: 11050497	USA/54-yr-old white woman	1	2 mo	1 cc Dermalogen (human collagen)	30-gauge needle test injection in volar forearm		Test injection in forearm resulted in an erythematous 8-mm indurated papule 1 mo after injection. One month later, the symptoms had subsided.
Moody et al., 2001 PMID: 11553165	USA/45-yr-old woman	1	7 wk	Zyderm II (bovine collagen)	Mentolabial crease, chin, lips	Not reported	21 days after treatment, patient reported redness, swelling, and pruritus at treatment sites.
Poveda et al., 2006 PMID: 16388285	Spain/55-yr-old woman, 72-yr-old woman, 70-yr-old woman, 54-yr-old woman, 43-yr-old woman	5	1 mo	Botulinum toxin type A (Botox) ( <i>n</i> = 1) Collagen ( <i>n</i> = 1) Dimethylpolysiloxane (silicone) ( <i>n</i> = 3)	Injections into the lower and upper lip, nasogenian area, facial area, cheeks, chin, and buccal mucosa		Discrete trabeculation of the mandibular and submandibular subcutaneous fat related to inflammation changes; intense inflammatory processes affecting almost the entire subcutaneous cellular tissue covering the maxillae and the floor of the mouth and a large part of the buccal mucosa; generalized, bilateral, facial Turnefaction; swelling of the lips and cheeks

Requena et al., 2001 PMID: 11391099	Spain/52-yr-old man, 42-yr-old woman, two 38-yr-old women	4	6-14 mo	Artecoll (n = 1) Dermalive (n = 1) Silicone (n = 2)	Artecoll: Nasolabial and forehead folds Dermalive: Forehead and periorcular ridges Silicone: NLFs, cheeks	Artecoll: Erythematous, ribbed, palpable indurations of both nasolabial and forehead folds Dermalive: Erythematous palpable indurations on forehead Silicone: Erythematous palpable indurations of both nasolabial folds, palpable indurations on both cheeks with mild erythema
Reytan et al., 2007 PMID: 17903163	Germany/26-yr-old man with mandibular prognathia	1	9 wk	Evolvece, 2.9 ml over two sessions	Philtrum area, vermilion border, and lip red	Not reported
Reytan et al., 2008 PMID: 19112805	Germany/61-yr-old Caucasian HIV-positive man presented with facial lipoatrophy; patient also has history of hepatitis C	1	14 mo	Evolvece, 5 ml in periorcular region and 6 ml in cheek augmentation; total over four treatments	Cheek, periorcular region	Not reported
Ricci et al., 2007 PMID: 18320835	Italy/Men between 43 and 78 yr old with severe dysphagia caused by partial laryngectomy	7	1 yr	Zyplast (bovine collagen)	Laryngoplasty	For two patients (28.5%, cases 5 and 6), only a partial positive result was achieved, as 1 mo after an initial improvement, dysphagia for liquids was again observed; these two patients had very difficult anatomical situations, with a wide neoglottic insufficiency. In one patient (14.4%, case 7), positive results were not achieved despite collagen injection through fiber endoscopy, and followed by PDMS injection through microlaryngoscopy.

ASPS, American Society of Plastic Surgeons; AAD, American Academy of Dermatology; PMID, PubMed identification number; USA, United States; NLF, nasolabial fold; HA, hyaluronic acid; WAS, Wrinkle Assessment Scale; AEs, adverse events; PMMA, polymethylmethacrylate; RCT, randomized controlled trial; FFAS, Facial Fold Assessment Scale; WSRS, Wrinkle Severity Rating Scale; GAIS, Global Aesthetic Improvement Scale; MFWS, Modified Fitzpatrick Wrinkle Scale; CaHA, calcium hydroxylapatite; HC, human-based collagen; LRS, Lemperte Rating Scale; CFBS, classic foreign body type granuloma; CMB, cystic and macrophagic-type granulomas; HIV, human immunodeficiency virus; PDMS, polydimethylsiloxane.

Appendix B. Cont'd

Study	Country/population type	Sample size	Follow-up	Treatment	Injection description	Outcome measures	Adverse events
<b>CaHA Fillers</b>							
<b>Randomized Controlled Trial: No. of Studies, 3</b>							
Moers-Carpi et al., 2007 PMID: 18086052	Europe/Enrolled patients had moderate or severe NLFs	205 (192)	4, 8, 12 mo	Radiesse (CaHA), 2.21 ml total volume ( <i>n</i> = 70) Juvéderm 24 (HA-1A), 4.78 ml total volume ( <i>n</i> = 33) Juvéderm 24HV (HA-1B), 2.94 ml total volume Perlane (HA-2), 2.89 ml total volume ( <i>n</i> = 65)	Patients treated with either CaHA gel or HA for the correction of both NLFs. Nearly all patients ( <i>n</i> = 189) received a touch-up treatment at 4 mo.	1. Patient satisfaction 2. Investigator GAIS analysis 3. WRSR analysis	No serious AEs requiring intervention were reported at any time points for any of the injected materials.
Moers-Carpi et al., 2008 PMID: 18093199	Germany and Spain/ Moderate to severe NLFs (3 or 4 on WRS)	60 (58)	6, 9, 12 mo	Radiesse Restylane Volume required for correction in CaHA-treated fold was 30% less than the volume of NASHA.	Patients received two injections 3 mo apart. At the initial visit, patient was treated with CaHA to correct one NLF and NASHA to correct the other NLF. At the 3-mo visit, patients received a touch-up treatment in both folds.	1. GAIS ratings 2. Blinded evaluators rating	Both products were safe and well tolerated. No serious AEs were reported with either treatment. Four AEs were reported: two hematomas, one nodule, and one extrusion (of 118 folds injected two times each during the course of the study). The two hematomas resolved in 4–5 days with no further complications. The nodule was treated with 0.2 ml of triamcinolone acetonide and was cleared in 14 days. The extrusion appeared in a NASHA-treated fold. It was treated with antibiotics and resolved without complications. Safety analysis included all 117 subjects.
Smith et al., 2007 PMID: 18086048	USA/Potential subjects were required to have symmetric, moderate to deep NLFs	117 (113)	1, 3, 6 mo	Radiesse (Collagen) Cosmoplast (CaHA)	Each side was treated until, in the judgment of the investigator, an optimal result was achieved. At 2 wk after treatment, subjects could receive touch-up injections at the discretion of the physician (occurred at 2-wk intervals; maximum of two additional treatment sessions). Qualifying subjects received CaHA product on one side, and the HC product on the other.	1. Number of injection sessions required: baseline only 2. Mean change in LRS from baseline, at 6 mo 3. Subject-by-subject direct comparison, at 6 mo 4. GAIS score of Improved, Much Improved, or Very Much Improved 5. Investigator and subject preference	Consistent with other injectable filler clinical studies, erythema, edema, and ecchymoses were some of the most common product-related AEs. Both edema and bruising were significantly more common on CaHA- treated sides than the HC side ( <i>p</i> < 0.001). These reactions lasted approximately 1 wk after any injection. Mean duration for erythema was 2–3 wk, with no significant difference between the two treatments. CaHA: one nodule; HC: three nodules. No granulomas, allergies, ulcerations or other serious AEs were noted.



**Uncontrolled Clinical Trial: No. of studies, 15**

Becker, 2008 PMID: 18520907	USA/General population	24 (18)	2–48 mo	Radiesse, 0.25–1.3 ml at initial injection	Various locations, numbers of injections	1. Patient satisfaction (0–10)	Not reported
Beer et al., 2008 PMID: 18459517	USA/Women with signs of midface volume loss	19 (16)	1, 3, 6 mo	Radiesse, volume at discretion of physician	Cheek Touch-up treatments were administered at 1 mo at discretion of physician.	1. Physician-evaluated aesthetic ratings 2. Patient satisfaction 3. Physician GAIIS ratings	Reported in two patients (13%). One reported mild edema and hematoma, resolving in less than 2 wk. The reported mild ecchymosis and edema after initial treatment, and mild edema after touch-up treatment. These resolved within 5 days.
Beerlin et al., 2008 PMID: 18547184	USA/Subjects with prominent nasolabial rhytides	5	6 mo	Radiesse, 0.1–0.2 ml	Right postauricular area	1. Postauricular biopsies using traditional hematoxylin and eosin staining 2. PSR staining 3. IHC analysis	All five subjects completed the study without any serious or long-term complications.
Carruthers et al., 2008 PMID: 18547186	USA/Patients with lipoatrophy or pronounced NLFs	58	None	Radiesse	Not reported	1. X-ray scan 2. CT scan 3. Other	Not reported
Jacovella et al., 2006 PMID: 16936540	Argentina/Facial injections for cosmetic purposes	40 (40)	18 mo	Radiesse, 0.5–2.0 ml (average, 0.75 ml)	Injections to the glabellar wrinkles, nasolabial folds, lips, nose, and/or infraorbital area	1. Patient satisfaction	No systemic effects or immunologic responses Ecchymosis and hematoma in two patients
Jansen et al., 2006 PMID: 16936541	USA/Facial injections for cosmetic purposes	609 (155, 6 mo) (112, 12–24 mo)	6, 12–24 mo	Radiesse Nasolabial folds 0.62 ml each (n = 395 areas) Upper lip, 0.6 ml; lower lip, 0.25 ml (n = 338 areas, combined lips) Radial lip line, 0.25 ml per line (n = 163 areas) Corner of mouth, 0.28 ml (n = 125 areas) Marionette lines, 0.49 ml each side (n = 75 areas) Glabellar lines, 0.22 ml (n = 106 areas) Chin/cheek lines, 0.20 ml (n = 50 areas) Acne scars, 0.12 ml (n = 33 areas) Scar deformities, 0.2–0.4 ml (n = 21 areas) Facial depression (HIV lipoatrophy), 5.25 ml (n = 14 areas) Cheek augmentation, 0.85 ml each side (n = 14 areas) Nasal depressions, 0.2 ml (n = 6 areas) Tear troughs, 0.35 ml (n = 8 areas) Touch-ups, average 0.3 ml	Injections to the glabellar wrinkles, nasolabial folds, lips, nose, and/or infraorbital area Injections to the nasolabial folds, marionette lines, oral commissure, cheeks, chin, lips, and/or radial lip lines	1. Treatment satisfaction survey (scale of 1–5) and continued use 2. AEs	Development of easily treated nodules in 48 patients (42 for lip mucosa augmentation and six for radial lip lines)

Appendix B. Cont'd

Study	Country/ population type	Sample size	Follow- up	Treatment	Injection description	Outcome measures	Adverse events
Marmur et al, 2009 PMID: 19708875	USA/Female patients aged 60–80 yr with soft-tissue deficiency of the dorsa of the hands	5	24 wk	Radiesse, 1.3 ml per hand for four patients and 2.6 ml per hand for one patient	Dorsal side of hand	Patient satisfaction levels	All patients had mild to moderate erythema and edema that did not require treatment and subsided within 3–6 days.  One patient had edema reoccur 10 days after treatment and continue for 3 wk.  One patient observed ecchymosis lasting 7 days from treatment and gradually resolving without intervention.  Another patient reported a feeling of warmth and pruritus lasting for 24 hr that cleared within 2 days.
Marmur et al, 2009 PMID: 19708876	USA/Patients aged 18 yr and older with Fitzpatrick skin types IV–VI	100	6 mo	Radiesse, 0.6–2.8 ml	Facial wrinkles and folds, including NLFs	Incidence of hypertrophic scarring, keloid formation, and hyperpigmentation or hypopigmentation	None reported
O'Hara et al, 2006 PMID: 16651970	USA/Patients undergoing zygomatic augmentation	8 (8)	1, 7 days; 3, 6, 12 mo	Hydroxyapatite injections in 0.5- to 1.0-cc increments from 2.0–4.0 cc per side (average, 2.5 cc)	Transconjunctival injections into the subperiosteal malar pockets	1. Patient satisfaction 2. Preoperative, postoperative, and follow-up right angle distance from the point of malar prominence to the nasale-subnasale line was significantly less in all postoperative and follow-up measurements compared with the same patient's preoperative measurements.	None reported

<p>Roy et al., 2006 PMID: 16970693</p>	<p>USA/Patients requesting facial soft-tissue augmentation, three men and 79 women</p>	<p>82</p>	<p>3–6 mo</p>	<p>Radliesse</p>	<p>The mean amount of material injected at the initial visit was 0.29 ml in the melolabial fold (per side), 0.34 ml in the upper lip, 0.37 ml in the lower lip, and 0.12 ml in the infracommissure fold The mean amount of material injected during touch-up injections was 0.15 ml in the melolabial folds (per side), 0.13 ml in the upper lip, and 0.12 ml in the lower lip</p>	<p>Patients and surgeonsevaluated the look and feel of the implant based on the following scale: 1 = unsatisfactory 2 = poor 3 = satisfactory 4 = very good 5 = excellent.</p>	<p>Mild erythema and minimal edema lasting for several hours was the most common side effect. Six (7%) developed submucosal nodules in the lips.</p>
<p>Sadick et al., 2007 PMID: 18086049</p>	<p>USA/Subjects with facial soft-tissue deficiency amenable to treatment</p>	<p>113</p>	<p>6 mo</p>	<p>Radliesse, 1.0 ml (n = 102), 2.0 ml (n = 12)</p>	<p>Most commonly treated site was the NLF (n = 86). Other sites included perioral lines, acne scars, tear trough depressions, and prejowl sulcus. 75 (67%) had a single injection session; 38 (34%) had multiple sessions.</p>	<p>1. Efficacy rating by treating physician (1–5), 6 mo 2. Efficacy rating by patient</p>	<p>No allergic reactions were reported. Mild erythema and minimal edema (few hours to a few days) were the most common side effects. Seven patients reported minor AEs. All were considered short- term and resolved within 1 mo. Transient ecchymosis (n = 3), submucosal nodules of the lip (n = 2), inflammation and edema (n = 2) resolved with oral prednisolone.</p>
<p>Silvers et al., 2006 PMID: 16936543</p>	<p>USA/Patients with facial lipoatrophy secondary to HIV</p>	<p>100 (100)</p>	<p>3, 6, 12, 18 mo</p>	<p>Radliesse, 4.8 ml (average)</p>	<p>Injections to the cheek area (submalar) performed by the investigators Initial injections followed up with subsequent injections at 1, 6, and 18 mo</p>	<p>1. GAIS improvement at 3 mo and confirmation using photography 2. GAIS improvement at 6 mo and skin fold thickness at 3 and 6 mo 3. GAIS improvement at 12 mo 4. GAIS improvement at 18 mo</p>	<p>AEs at 12 mo were mild, not unexpected, and short in duration.</p>

Appendix B. Cont'd

Study	Country/ population type	Sample size	Follow- up	Treatment	Injection description	Outcome measures	Adverse events
Sklar et al, 2004 PMID: 15099322	USA/Patients with subcutaneous or deep tissue atrophy	64 (64)	6 mo	Radiance FN Nasolabial folds, 0.91 ml (average); range, 0.4–2.0 ml (n = 52) Tear trough, 0.35 ml (average); range, 0.3–0.7 ml (n = 15) Lips 0.67 ml (average); range, 0.2–1.4 ml (n = 15) Intraoral, 0.29 ml (average); range, 0.1–0.5 ml (n = 11) Cheeks, 0.60 ml (average); range, 0.3–1.2 ml (n = 4) Mental crease, 0.15 ml (average); range, 0.1–0.2 ml (n = 2) Above upper lip, 0.20 ml (average); range, 0.2 ml (n = 1) Buccal region, 2.0 ml (average); range, 2.9 ml (n = 1)	Injections in a retrograde technique to NLFs, tear trough, lips, intraoral, cheeks, mental crease, above upper lip, buccal region	Patient and physician satisfaction	Three patients had palpable bumps. One patient had overcorrection of the tear trough area resulting in puffy eyes.
Stupak et al, 2007 PMID: 17372068	USA/Patients with postrhinoplasty contour irregularities or asymmetry	13	2.5 mo	Radiesse; mean dose, 0.19 ml	Dorsum and bilateral walls of the nasal region	Patient satisfaction Photographic improvement	No serious complications occurred in any patients. One patient described a period of several days of mild erythema, but resolved without treatment.
Tzikas, 2004 PMID: 15262717	USA/Patients seeking soft-tissue augmentation	90	6 mo	Radiance FN, 0.2 ml (average)	Injection subdermally between dermis and subcutaneous fat to the NLFs, glabellar rhytides, marionette lines, prejowl depressions, acne scars, and surgical soft-tissue defects Injection to the lips in the plane superficial to the orbicularis muscle	Appearance, softness, overall patient satisfaction	Seven patients had persistent visible mucosal lip nodules.
<b>Cohort Study: No. of Studies, 2</b>							
Rokhsar et al., 2008 PMID: 18384613	USA/Subjects with or without a history of surgical rhinoplasty	14	6 mo	Radiesse, mean 0.27 ml at initial visit	Nonsurgical nasal recontouring, 30% of patients requested additional touch-ups at 2-wk follow-up visit	1. Patient satisfaction	57% showed ecchymoses for 2–7 days. 64% had edema for 2–5 days. No infection or surface irregularity AEs were recorded at either visit.
Tzikas, 2008 PMID: 18547188	USA/Patients > 18 yr with a facial soft-tissue deficiency amenable to treatment	1000	1 yr	Radiesse; mean volume, 1.9 ml	Variety facial contouring applications, majority NLFs and marionette lines	1. Duration of effect	Minor; most resolved without treatment.

**Cross-Sectional Study: No. of Studies, 1**

Alam et al., 2007 PMID: 17224371	USA/Patients presented for correction of depressions of the NLFs	22 (18)	1-1.5 yr	Radiesse, 1-2 ml in each NLF	NLFs	1. Longevity of results 2. Patient satisfaction with CaHA	Of the 18 patients, all reported at least mild postinjection redness and swelling, which abated within 1-5 days. Bruising was reported by fewer than half and resolved within 4-10 days. Palpable but not visible nodules were reported by two of 18 patients; these resolved within 3 mo of injection.
-------------------------------------	--	---------	----------	------------------------------	------	--	---

**Case Series/Report: No. of Studies, 11**

Beer, 2007 PMID: 17763619	USA/59-yr-old woman	1	6 wk	Radiesse, 3.9 ml	Nasolabial creases and marionette lines	Not reported	2 wk after treatment, examination revealed an opaque, white nodule, 1.5 cm, located on the labia mucosa of the lower lip; nodule was solid and nonmalleable.  Patient was treated with Kenalog (three treatments of 20 mg/ml, 2 wk apart), which reduced the size of the nodule to 1 cm.
Feeney et al., 2009 PMID: 19664480	USA/Patients with hyperattenuating hypermetabolic subcutaneous lesions and a history of facial injections	5 (5)	NA	Radiesse	1. Injections to the left infrazygomatic region 2. Injections to the infraorbital and infrazygomatic regions 3. Injections to the infraorbital and infrazygomatic regions 4. Injections to the infraorbital, nasolabial, parotid and perioral regions 5. Injections to the infraorbital, infrazygomatic, and perioral regions	Not reported	All cases had subcutaneous high-attenuation material on CT scan (range, 280-700 HU), which was FDG avid on PET, with a SUV range of 2.9-13.4. MRI demonstrated a heterogeneous intermediate signal intensity subcutaneous lesion with enhancement post-gadolinium in one case.
Godin et al., 2006 PMID: 16549735	USA/Patients undergoing facial augmentation	101 (61)	10 mo	Radiesse (n = 72) Radiesse and Restylane (n = 29)	Injection to the NLFs, upper and lower lip vermilion borders, "lipstick lines" and perioral lines	Immediate and long-term patient satisfaction survey (10-point scale)	Not reported

Appendix B. Cont'd

Study	Country/population type	Sample size	Follow-up	Treatment	Injection description	Outcome measures	Adverse events
Kanchwala et al., 2005 PMID: 15985788	USA/Patients undergoing facial augmentation	976	3, 6, 9, 12 mo	Autologous fat (n = 697) Hyaliform (n = 52) Restylane (n = 86) Radiesse (n = 141)	Nasolabial folds, lips, glabella	1. Type of product used 2. Anatomical region injected 3. Infection rate 4. Touch-up/revision rate and overall longevity	Not reported
Kotlus et al., 2007 PMID: 17667106	USA/66-yr-old man presented with anophthalmic enophthalmos caused by an accident	1	6 mo	Radiesse, two 1.3-ml treatments 3 wk apart	Left orbital region	Not reported	None reported
Lee et al., 2008 PMID: 18806674	Korea/37-yr-old woman with 2-mo history of fullness and ptosis of the left upper eyelid	1	4 mo	Radiesse	Eyelid and orbital region	Not reported	Patient complained of fullness and ptosis of the left upper eyelid for 8 wk that developed abruptly and worsened over 2–3 wk.  Marked ptosis of the left upper eyelid and elevation of the left lower eyelid were observed. Surgical excision was performed and gray-white masses and a gel-like material were found between the orbital septum and the orbicularis oculi muscle.  Microscopic examination of the specimen showed CaHA microspherules surrounded by collagen and histiocytes.
Sankar et al., 2007 PMID: 17670876	USA/51-yr-old woman presented with chief complaint of a lump on the mucosal aspect of her lower lip on the left side	1	Unknown	Radiesse	Lip	Not reported	Lesion of yellow nodule measuring 6 x 3 mm with well-defined, irregularly shaped borders that was firm on palpation; after removal, excised mass was pale, yellow and rubbery in consistency.  Final histologic diagnosis was the presence of a foreign material along with a florid foreign body giant cell reaction of the soft-tissue, chronic inflammation, and fibrosis.

Author(s) and PMID	Number of Patients	Demographics	Presented 8 yr after first treatment	Radiesse ml treatments	Nasolabial fold	Not reported	Foreign body granuloma
Shumaker et al, 2009 PMID: 19207328	1	USA/57-yr-old woman presented with a several-month history of enlarging plaque of the left superior NLF; after examination, patient had a pearly plaque that demonstrated basal cell carcinoma	6 mo	Radiesse, four 0.3-ml treatments	Nasolabial fold	Not reported	Foreign body granuloma
Sires et al, 2008 PMID: 18520838	1	USA/57-yr-old immunocompetent woman who developed herpetic-appearing skin lesions after injection of Radiesse in the glabella	6 mo	Radiesse, four 0.3-ml treatments	Glabella, marionette lines, and NLFs	Not reported	Patient presented with tenderness, tingling, and redness with bumps along the glabellar region; examination revealed erythema with vesicles or pustules, swelling, and tenderness in the right glabella region.
Vagefi et al, 2007 PMID: 18025356	4	USA/Three women and one man; mean age, 36 yr; all with PEESS	45-71 wk	Radiesse, 1.3-2.6 ml	Extracanal space in the orbital region	Enophthalmos measured by Hertel exophthalmometry	One patient experienced peribulbar hemorrhage related to retrobulbar anesthesia administration during injection.
Vagefi et al, 2008 PMID: 18520833	3 (two men, one woman)	USA/Patients with bony defects of the frontal bone from prior trauma or surgery	2-7 mo	Radiesse/calcium hydroxylapatite, 1.3-3.9 ml	Filler injected into bony defects subdermally, in conjunction with other eyelid procedures	Not reported	None reported

ASPS, American Society of Plastic Surgeons; AAD, American Academy of Dermatology; CaHA, calcium hydroxylapatite; PMID, PubMed identification number; NLF, nasolabial fold; GAIS, Global Aesthetic Improvement Scale; WSRS, Wrinkle Severity Rating Scale; AEs, adverse events; HA, hyaluronic acid; NASHA, non-animal-stabilized hyaluronic acid; USA, United States; HC, human-based collagen; LRS, Lemperle Rating Scale; PSR, picosirius red; IHC, immunohistochemistry; CT, computed tomographic; HIV, human immunodeficiency virus; FDG, fluorodeoxyglucose; PET, positron emission tomography; SUV, standardized uptake value; MRI, magnetic resonance imaging; NA, not applicable; PEESS, postenucleation or evisceration socket syndrome.

Appendix B. Cont'd

Study	Country/population type	Sample size	Follow-up	Treatment	Injection description	Outcome measures	Adverse events
<b>PLLA Fillers</b>							
<b>Systematic Review: No. of Studies, 1</b>							
El-Beyrouly et al., 2006 PMID: 16912248	USA, England, and France/Systematic review of studies conducted in HIV lipoatrophy populations of white men	6 clinical trials: VEGA, Chelsea and Westminster, Lafautie et al., APEX 001, APEX 002, and Blue Pacific	Various	PLLA 1. VEGA: PLLA, 4.0 ml (n = 47) 2. Chelsea and Westminster: PLLA, 3.0 ml (n = 29) 3. Lafautie et al.: PLLA, 2.5 ml (n = 94) 4. APEX 001: PLLA, 1.0–8.0 ml (n = 100) 5. APEX 002: PLLA, 8.0 ml (n = 99) 6. Blue Pacific Group: PLLA acid, 6.0 ml (n = 99)	Injections to the cheeks for the treatment of HIV	1. Total cutaneous thickness 2. Skin thickness 3. Patient's perception of improvement using a VAS 4. Patient satisfaction rated on a scale from 1–10 5. Patient satisfaction rated on a scale from 1–5 6. Facial skin thickness	Nodules developed in 26 of 50 patients (VEGA). Hematoma developed in 14 of 50 patients (VEGA). Nine of 30 patients reported an injection-site papule or nodule (Chelsea and Westminster). 39 of 70 patients developed nodules (APEX 001). Six of 99 patients developed subcutaneous papules (APEX 002). 13 patients developed injection-site papule (Blue Pacific Group). Two serious AEs: anaphylactic reaction and peripheral facial palsy (Lafautie et al.).
<b>Randomized Controlled Trial: No. of Studies, 2</b>							
Moyle et al., 2004 PMID: 15012646	UK/Patients with HIV-induced facial lipoatrophy	30 (30)	0, 12, 24 wk New-Fill immediate treatment (n = 15) New-Fill delayed treatment	Injection into the deep dermis overlying the buccal fat pad	1. VAS (0–10, with low scores indicating extreme thinness) 2. HADS (0–10, with low scores indicating less depression/anxiety) 3. Blind assessment of photographs	None reported.	
Moyle et al., 2006 PMID: 16494632	USA/Patients with HIV-related facial lipoatrophy	30 (27)	18 mo Sculptra (PLLA) immediate treatment, 3.0 ml (n = 15) Sculptra (PLLA) delayed treatment, 3.0 ml (n = 15)	Three sets of bilateral injections, 2 wk apart, to the deep dermis above the buccal fat pad	1. Efficacy and patient satisfaction assessed by a VAS 2. HADS	One case of injection-site induration Nine cases of injection-site nodules	



**Uncontrolled Clinical Trial: No. of Studies, 4**

Beer, 2007 PMID: 18086054	USA/Subjects with facial scars resulting from moderate to severe acne or varicella	20 (16)	At each treatment session	Sculptra	Injections were given at 1-mo intervals to primary endpoint of resolution of scars (up to seven treatments)	1. Investigator-assessed reduction in acne scar size 2. Patient-assessed reduction in acne scar size 3. Patient satisfaction (Beer Scale)	AEs were limited to depression (n = 1) and not related to treatment.
Burgess et al., 2005 PMID: 15692467	USA/HIV-infected men on HAART with facial lipoatrophy	61	6, 18 mo	New-Fill Stage I lipoatrophy, 4.0–12.0 cc (n = 9) Stage II lipoatrophy, 8.0–12.0 cc (n = 15) Stage III lipoatrophy, 12.0–24.0 cc (n = 30) Stage IV lipoatrophy, 16.0–24.0 cc (n = 7)	Injection to the junction of the subcutaneous-deep dermal plane; fanning injection technique was used to create a deep dermal lattice	1. Treatment evaluation scale 2. Physician and nontreating physician	Not reported
Hanke et al., 2007 PMID: 17373169	USA/27 HIV-positive patients and 38 HIV- negative patients	65	2 yr	Sculptra, 4–8 ml	Cheeks	Efficacy assessment using the Facial Lipoatrophy Grading Scale (0–5); 0 = no facial lipoatrophy and 5 = severe facial lipoatrophy  Patient satisfaction (1–5): 1 = very unsatisfied; 5 = very satisfied	61 patients (94%) had no complications. Both HIV-positive and HIV- negative patients had similar complication rates. Two patients with HIV and two patients without had documented papules at the eyelid margin. One patient had two small subcutaneous papules at the oral commissure. Two patients had three papules on the cheeks. All subcutaneous papules resolved with time without treatment. Based on Fisher's exact test, HIV-negative patients do not have significantly greater number of complications than HIV-positive patients.
Salles et al., 2008 PMID: 18551341	Brazil/General population	10	6, 36 mo	Sculptra	NLFs, one injection per mo for 3 mo	1. Patient satisfaction 2. VAS	Minor complications (edema and small hematomas) lasted only 2–10 days after the injections and resolved spontaneously without specific interventions.

Appendix B. Cont'd

Study	Country/population type	Sample size	Follow-up	Treatment	Injection description	Outcome measures	Adverse events
<b>Cohort Study: No. of Studies, 7</b>							
Kavouni et al, 2008 PMID: 18449827	UK/HIV-positive patients with facial lipoatrophy	441	3–32 mo	New-Fill	Minimum 10 ml injected into facial areas including the temples, infraorbital grooves, buccal areas, NLFs, above and below the zygoma, and preaural	1. HADS 2. Appearance Satisfaction Questionnaire 3. Patient satisfaction	Reported AEs during the treatment period were minimal and included injection site erythema, tenderness, edema, and ecchymosis.  Incidence of nodule formation was 2.9%.
Levy et al, 2008 PMID: 19022099	USA/HIV-positive and HIV-negative patients	65 (53)	3 yr	Sculptra, 5.0 ml	Half of the volume injected into dermis, half into the underlying subcutaneous tissue; four to eight areas on each cheek	1. Evaluation of facial lipoatrophy, net 3-yr improvement 2. Patient satisfaction	At 2-yr follow-up, 61 patients (94%) had no complications. The most common complication was subcutaneous papules, which developed in four patients (6%).  At 3-yr follow-up, three additional patients developed small subcutaneous papules.  The total number of PLLA vials received over the course of the treatment was strongly correlated with the development of subcutaneous papules ( $p < 0.01$ ).  The vast majority of papules were not noticeable clinically and only appreciated when palpated.
Lowe et al, 2009 PMID: 19207324	UK/Patients receiving 1–5 PLLA treatments	221	6–24 mo	Sculptra	Cheeks, perioral, chin, deltoids, thighs, gluteal, forehead	1. Patient-reported duration of effect	Injection-related AEs were the most frequently reported, and most resolved spontaneously within 2–7 days with no further treatment required.  Clinically relevant papules occurred, but the majority were not visible. The main risk for papules or nodules were the periorbital and perioral regions. The authors currently do not recommend these areas. Some nodules took up to 18 mo to resolve.

Mazzucco et al., 2009 PMID: 19438668	Brazil/Patients with one or more of the following signs of aging: cutaneous flaccidity, atrophy, and wrinkles in the neck and chest	36	60 days, 18 mo	Average 3.9- ml dose injected per session (n = 36)	Neck and chest (prestermal area); average, 1.8 sessions per patient	1. Improvement based on photographic analysis performed by three independent evaluators at 60 days 2. Patient satisfaction 3. 18-mo follow-up	Appearance of hematomas and ecchymosis occurred in all 36 patients and regressed spontaneously after 7–10 days. One patient had palpable nodules, but this patient reported not having to massage the area according to instructions. No serious AEs
Mest et al., 2009 PMID: 19207325	USA/HIV-positive patients	65	24 mo	PLLA, 1–10 ml	Patients treated at 5- wk intervals until full correction was obtained	1. Patient satisfaction (1–5, with 5 being very satisfied) 2. Number of retreatments required	No serious AEs
Negredo et al., 2006 PMID: 17192148	Spain/HIV-infected patients presenting with antiretroviral- associated facial lipoatrophy for >6 mo	138 (eight received fat, 25 received PLLA, and 105 received polyacrylamide gel)	96 wk	Analogous fat obtained by liposuction, 50 ml Polylactic acid, 3–14 ml Polyacrylamide gel, 4–18 ml	NLFs	Level of facial lipoatrophy from photographic and self-assessment	All patients complained of pain at the infiltration site during the intervention, and facial edema for 2–3 days, which was always minimal and transient. Ecchymoses were observed in 14% of patients, most cases (13%) being in the polyacrylamide group. Seven of 21 women (33%) included in the polyacrylamide group manifested ecchymoses. All cases resolved spontaneously within 3–5 days. Two patients from the PLLA group (1.4% of the total number of patients included) presented palpable subcutaneous micronodules in the malar area, and two subjects from the polyacrylamide group (1.4% of the total) developed a superficial cutaneous infection, which was easily controlled with an oral antibiotic (the specific type of bacteria was not identified). Only two patients required withdrawal of the substance after polyacrylamide infiltration because of a hypercorrection or excess of substance in the malar area (one man and one woman).

Appendix B. Cont'd

Study	Country/population type	Sample size	Follow-up	Treatment	Injection description	Outcome measures	Adverse events
Sadick et al., 2008 PMID: 19016062	USA/General population	26	6–12 mo	PLLA, 1.5–2.0 ml	Hand: mean, 2.38 treatments per patient	Not reported	The most commonly reported AEs, such as bruising, swelling, and pain, were injection-related and resolved within a few days of treatment. No papules or nodules were reported in any patients; and there were no serious AEs.
<b>Case Series/Report: No. of Studies, 19</b>							
Apikian et al., 2007 PMID: 17524125	Australia/Four white women aged 48–57 yr	4	7 days–2 yr	New-Fill	Report 1: Infraorbital areas, temporal areas, cheek area Report 2: Each infraorbital region and nasolabial line Report 3: Infraorbital area, nasojugal lines, marionette lines in first treatment, infraorbital area, cheek bone area, and marionette lines 6 wk later	Report 1: Several firm 1- to 2-mm asymptomatic nodules in the infraorbital areas 6 wk after treatment Report 2: Three asymptomatic firm nodules ~3 mm within 7 days of the procedure Report 3: Palpable 3-mm asymptomatic nodule after 6 wk Report 4: Three asymptomatic nodules 7–10 days after treatment	
Beer, 2009 PMID: 19207333	USA/64-yr-old woman for cosmetic treatment of periorbital areas; 59-yr-old woman evaluated for facial rejuvenation	2 (2)	12–18 mo	PLLA, 2.0 ml each tear trough, two sessions, 4 wk apart PLLA, 1.0 ml, each tear trough	Depot injections into each tear trough made at the level of the periosteum Injections into the cheeks, tear troughs, and zygomatic arch areas	Not reported	Development of subcutaneous papules caused by a foreign body reaction Dense foreign body reaction with abundant formation of collagen
Beijaards et al., 2005 PMID: 16029705	The Netherlands/Three women aged 35–53 yr	3	12–22 mo	1–3 ml reconstituted New-Fill (polylactic acid)	NLFs, cheeks, lips, neck	Not reported	Palpable strands on the NLF, strands and nodules along treated wrinkles, palpable superficial nodules around treatment site
Burgess, 2008 PMID: 18231700	USA/69-yr-old African American woman	1	18 mo	Sculptra, 5 ml each treatment, two treatments total	Dermal subcutaneous plane of the upper and lower cheeks and the preauricular and malar regions	Not reported	None reported

Hamilton et al., 2008 PMID: 18053031	France/58-yr-old immunocompetent woman presented with subcutaneous nodules	1	4 yr	Sculptra, 9 ml	NLFs (6 ml) Cutaneous border of the vermillion (1 ml) Jugomalar depression adjacent to the infraorbital periosteum	Not reported	Presented with tender nodules at injection sites; was treated with intralesional triamcinolone injections. After several months, examination revealed several red, nontender, deep nodules, and facial skin atrophy and telangiectasias. Nodules persisted and patient eventually was treated with triamcinolone at 40 mg/ml to resolve the inflammation.
Jham et al., 2009 PMID: 19138600	Various/General population	56		Various	Upper/lower lip, NLF, cheek	Not reported	Clinical presentation: Single nodule, diffuse swelling, multiple nodules, mass, other Treatments: Excisional biopsy, steroids (systemic and intralesional), antibiotics, nonsteroidal antiinflammatory drugs, uricosuric agent, immunoregulator
Kates et al., 2008 PMID: 19083552	USA/Two white men in their 40s with facial lipoatrophy who had been HIV-positive for >10 yr	2	12 mo	PLLA	Deep dermis or subcutaneous layer of the face, two vials in each of five treatments spaced 4 wk apart	Not reported	Treatments associated with mild swelling that resolved within 5–7 days, bruising was not observed, no papules were reported in the follow-up period of 12 mo.
Lombardi et al., 2004 PMID: 14720198	France/Patients with Artecoll, Dermalive, New-Fill, or Liquid-Silicone induced granulomas	11	Not reported	Artecoll Dermalive New-Fill Liquid-Silicone	Not reported	Not reported	12 biopsy specimens taken: lips (n = 6), cheeks (n = 2), nasolabial folds (n = 1), glabella (n = 2), and lower eyelid (n = 1). All were either CFBGs or CMGs. All lesions were asymptomatic. Different types of CFBGs were related to various fillers: Type 1: Artecoll or Arteplast Type 2: Dermalive Type 3: New-Fill Type 4: Bioplastique. CMGs were associated with Liquid-Silicone injections.

Appendix B. Cont'd

Study	Country/population type	Sample size	Follow-up	Treatment	Injection description	Outcome measures	Adverse events
Mest et al., 2006 PMID: 17083585	USA/Patients older than 18 with HIV seropositivity and facial lipoatrophy	97 (75)	12 mo	PLLA, 1–6 ml per session, with patients receiving between one and six sessions	Cheeks and temples	Increase in total cutaneous thickness by skin calipers Patient satisfaction on a 1–5 scale	None reported
Poveda et al., 2006 PMID: 16388285	Spain/55-yr-old woman, 72-yr-old woman, 70-yr-old woman, 54-yr-old woman, 43-yr-old woman	5	1 mo	Botulinum toxin type A (Botox) (n = 1) Collagen (n = 1) Dimethylpolysiloxane (silicone) (n = 3)	Injections into the lower and upper lip, nasogenian area, facial area, cheeks, chin, and buccal mucosa	Discrete trabeculation of the mandibular and submandibular subcutaneous fat related to inflammation changes; intense inflammatory processes affecting almost the entire subcutaneous cellular tissue covering the maxillae and the floor of the mouth and a large part of the buccal mucosa; generalized, bilateral, facial tumefaction; swelling of the lips and cheeks	Very minor tenderness and erythema
Ralston et al., 2006 PMID: 17373151	USA/40-yr-old white woman	1	10 mo	Sculptra	Upper arm	Patient satisfaction score and physician satisfaction score using a definitive graduated score	One patient experienced nodule formation that disappeared without treatment.
Redaelli, 2006 PMID: 17177745	Italy/Female patients aged between 59 and 72 yr	27	6–15 mo	PLLA, 2 ml per hand in the first session, 1–2 ml for subsequent sessions	Dorsum of the hand	Patient's quality of life	None reported
Rendon et al., 2008 PMID: 18441843	USA/64-yr-old woman who underwent extensive surgical procedures for damage to the craniofacial area following a car accident	1	5 mo	PLLA, 5 ml	Deep dermis of the cheeks (2 ml); NLFs (1 ml), zygomatic arches (1 ml), temples (0.5 ml), and chin (0.5 ml) Above treatment repeated two more times ~1 mo apart	Patient's quality of life	None reported

Reszko et al., 2009 PMID: 19207329	USA /62-yr-old immunocompetent patient	1 (1)	12-18 mo since treatment	Sculptra (PLLA)	Bilateral cheeks, chin, and infraorbital areas	Not reported	>60 firm 2- to 18-mm papules and nodules on bilateral cheeks, chin, and infraorbital areas  Nodules contained foreign body granulomas of irregularly shaped polarizable crystals.  Most severe AE was nodule formation, rated as severe in 13 (59.1%) cases.  Usually, the nodules took several months to develop and persisted more than 1 yr in most patients.  The frequency of patients with AEs decreased in the period from 2000 to 2007.
Roschner et al., 2009 PMID: 19250160	Germany/Patients from Berlin Registry presenting an adverse reaction to PLLA	22	8 yr	New-Fill	Not reported	Not reported	
Schulman et al., 2008 PMID: 18186871	USA /63-yr-old thin woman who complained of a superior "step-off" deformity and visible intercostal spaces after implant reconstruction	1	9 mo	Sculptra: Four treatments at 1-mo intervals, each treatment was two 367.5-mg vials	Subcutaneous tissue and deep dermal layers of the superior and medial right chest wall	Not reported	None reported
Stewart et al., 2007 PMID: 17667102	USA /39-yr-old woman presented with multiple visible, palpable papules in bilateral infraorbital region	1	4 mo	Sculptra	Bilateral infraorbital region	Not reported	3-4 days after treatment, bumps developed along the orbital rim and nasal sidewall; treatment over the next 3 mo with intralesional triamcinolone acetonide (3 mg/ml) did not improve the bumps.  Biopsy revealed foreign body granulomatous reaction pattern.  Restylane was injected in the tear trough to camouflage papules, but this made them more apparent.  Surgical excision was used to remove the papules.

Appendix B. Cont'd

Study	Country/population type	Sample size	Follow-up	Treatment	Injection description	Outcome measures	Adverse events
Woerle et al., 2004 PMID: 15303782	Europe/300 patients (70% men) for prospective, 48-yr-old man and 51-yr-old woman for retrospective case report	302	12–24 mo	PLLA	26-gauge needle into the nasolabial folds, marionette lines, labiomental creases, upper lip, cheeks, chin, and temples  From 1999–2002, the acid mixture stood for 2–12 hr before injection; afterward, the mixture stood for 36–48 hr.	Patient satisfaction	In the first part of the study, 10% developed subcutaneous papules that resolved in 12–24 mo without treatment and 3 mo with treatment.
Wolfram et al., 2006 PMID: 17135735	Austria/Two 58-yr-old women, one 53-yr-old woman	3	3 mo–2 yr	New-Fill, Restylane, Dermalive	Zygomatich arch, eyelids, forehead, nasolabial folds, cheeks		Erythematous indurations at injection sites

ASPS, American Society of Plastic Surgeons; AAD, American Academy of Dermatology; PLLA, poly-L-lactic acid; PMID, PubMed identification number; USA, United States; HIV, human immunodeficiency virus; AEs, adverse events; VAS, visual analogue scale; HADS, Hospital Anxiety and Depression Scale; HAART, highly active antiretroviral therapy; NLF, nasolabial fold; CFBGs, classic foreign body type granulomas; CMGs, cystic and macrophagic-type granulomas.

**PMMA Fillers  
Randomized Controlled Trial: No. of Studies, 2**

Study	Country/population type	Sample size	Follow-up	Treatment	Injection description	Outcome measures	Adverse events
Cohen et al., 2004 PMID: 15468406	USA/Patients at least 18 yr old presenting for glabellar, NLFs, radial upper lip lines, marionette lines correction	251 (251) (111 at 12 mo)	1, 3, 6, 12 mo	Artecoll (n = 128) Zyderm II or Zyplast (n = 123)	Tunneling technique: glabella, NLFs, radial upper lip lines, marionette lines	1. Cosmetic correction at 6 and 12 mo using the Facial Fold Assessment Scale by three masked observers and physicians 2. Physician and patient assessment	27 AEs in Artecoll group; 38 AEs in collagen control group
Cohen et al., 2006 PMID: 16936546	USA/Patients with wrinkles of the glabella, nasolabial folds, radial upper lip lines, and corners of the mouth; treated with PMMA filler in pivotal RCT (Cohen 2004)	251 (233) 69 4–5 yr	1, 3, 6, 12 mo; 4–5 yr	ArteFill (amount not specified) (n = 128) Collagen (amount not specified) (n = 123)	Injection at the glabella, NLFs, radial upper lip lines, or corners of the mouth	1. Cosmetic correction 2. Physician's assessment of success 3. Facial Fold Assessment Scale rating 4. Long-term cosmetic correction 5. Physician's assessment of long-term success 6. Safety and AE	1. Redness, swelling, and lumpiness at the injection site for collagen 2. 27 adverse events for ArteFill vs. 38 adverse events for collagen 3. Six late adverse events for ArteFill; two severe and four moderate



**Cohort Study: No. of Studies, 1**

Cohen et al., 2007 PMID: 18086062	USA/Patients treated with PMMA filler in pivotal RCT (Cohen, 2004)	251 (145)	5 yr	ArteFill, 0.82 ml/fold (n = 128)	NLF	1. Blinded observer FFA ratings at 5 yr compared to baseline 2. Investigator FFA scores 3. Investigator success rate 4. Patient satisfaction 5. Efficacy at 5 yr	145 subjects were evaluated for safety; 28 total adverse were experienced by 21 subjects; 20 treatment- related AEs were distributed among 15 subjects. Most common was lumpiness; 80% were deemed mild. Treatment-related events: Mild: 8.3% Moderate: 1.4% Severe: 0.7% Severe event: Lumpy, inflamed nodule in each of the NLFs at 5 yr. Affected area partially responded to intralesional steroid therapy
---	--	-----------	------	-------------------------------------	-----	--	---

**Case Series/Report: No. of Studies, 10**

Bedocs et al., 2008 PMID: 18441850	USA/Woman presented with a 3-mo history of an erythematous pruritic plaque located in the area of an unconventional invisible tattoo placed on the upper arm	1	9 mo since procedure	PMMA with fluorescent dye	Upper arm	Not reported	Physical examination revealed a 6.5-cm erythematous plaque of coalescing firm papules in the shape of a stylized sun located on left lateral arm Histologic examination disclosed that the epidermis appeared unchanged, the dermis contained multiple epithelioid granulomas surrounded by a sparse lymphocytic infiltrate; small, clear spherical, particles with some variation in size and shape were present within these granulomas. Paraffin-embedded section fluoresced under Wood lamp examination
--	---	---	-------------------------	------------------------------	-----------	--------------	--

Appendix B. Cont'd

Study	Country/population type	Sample size	Follow-up	Treatment	Injection description	Outcome measures	Adverse events
Carvalho et al., 2009 PMID: 19438669	Brazil/Men and women without previous facial augmentation treatments, 30% (n = 79) with facial atrophy caused by AIDS, 60% (n = 159) with photoaging signs, 9% (n = 5) with depressed but distensible scars, and 1% (n = 3) with residual depressions from cutaneous lupus profundus	154 women, 112 men	1 mo and 6 mo after treatment, and then each year for 9 yr	MetaCrill (PMMA), 1–8 ml depending on patient between applications	24-, 23-, or 26-gauge needles used, product inserted at the subcutaneous tissue or subdermal layer Sessions varied from one to four, within intervals of approximately 40–60 days	Satisfaction with treatment and improvement in self-esteem	Temporary swelling, erythema, and bruising
Castro et al., 2007 PMID: 18278234	Brazil/77-yr-old oman	1	Unreported number of days	PMMA	Nasogenian groove	Not reported	Presented with facial pain, edema, and cyanosis in right hemiface 24 hr after treatment; further developed into facial necrosis in the areas nourished by the right inferior and superior labial coronal arteries and the right angular arteries
da Costa Miguel et al., 2009 PMID: 19243914	Brazil/56-yr-old woman presented with swelling in the lower lip	1	Case presented 1 yr after treatment	PMMA	Lip	Not reported	Firm pink nodule covered with nonulcerated mucosa, located in the right anterior inferior alveolar mucosa; biopsy results note presence of foreign body granuloma.
Gelfer et al., 2007 PMID: 17451587	USA/General population	10	Up to 3 yr	10 cases presented	Various sites	N/A	10 cases presented with inflammatory reactions, including granulomas, nodules, and induration. Other adverse events include erythema, swelling, pain, and discoloration. Adverse reaction onset varied from 3 mo to 4 yr after last injection.

Jham et al., PMID: 19138600	Various/General population	56	Various	Upper/lower lip, NLF, cheek	Not reported	Clinical presentation: Single nodule, diffuse swelling, multiple nodules, mass, other
Treatments: Excisional biopsy, steroids (systemic and intralesional), antibiotics, nonsteroidal - antiinflammatory drugs, uricosuric agent, immunoregulator						
Nelson et al., 2008 PMID: 18023267	UK/Patients with HIV- associated lipodystrophy	46 (46)	Coleman autologous fat injection (n = 26) New-Fill (n = 10) Bio-Alcamid (n = 8) Treatment (e.g., liposuction) for fat accumulation (n = 13) (results not provided for this review)	New-Fill injections were performed by a trained nurse specialist. One vial of New-Fill per cheek was injected to the deep dermis of affected areas (i.e., cheek, temple) during each treatment session. Bio-Alcamid injections were performed in a theater environment. The product was injected until total correction of the deficit was obtained	1. Patient satisfaction score using a visual analogue scale  2. Cheek volume using 3D facial image scan (only performed in patients	Autologous fat: Bruising and swelling occurred in five patients postoperatively. New-Fill: None reported. Bio-Alcamid: Complications included bruising and swelling persisting up to 1 mo. Two patients had minor asymmetry requiring corrective procedures.
Parada et al., 2005 PMID: 16276149	Brazil	11	Restylane (hyaluronic acid), MetaCrill polymethylmethacrylate), Aquamid (polyacrylamide), New-Fill (polylactic acid), Artecoll PMMA suspended in a collagen solution).	Biopsy specimens fixed in 10% formalin.	Not reported	Restylane: An inflammatory process occurred on the deep reticular dermis, hypodermis, and at the level of the dermal musculature. Periadnexal and perivascular lymphomononuclear infiltrates were observed in the superficial and deep dermis, in addition to numerous eosinophils.  Aquamid: inflammatory infiltrates were observed on the deep reticular dermis, hypodermis, and dermal musculature.  MetaCrill: A focal or diffuse inflammatory infiltrate at the reticular dermis and hypodermis was observed.

Appendix B. Cont'd

Study	Country/population type	Sample size	Follow-up	Treatment	Injection description	Outcome measures	Adverse events
Salles et al., 2008 PMID: 18454007	Brazil/Seven men and 25 women with an average age of 43.6 yr	32	5 yr since treatment	PMMA	Nose, penis, NLF, gluteus, malar and submalar regions, abdomen, periocular, frontal depressed scar, frontal region and chin, glabella, lip	Not reported	<p>New-Fill: A connective tissue presented diffuse inflammatory infiltrate.</p> <p>Artecoli: A connective fibrous and striated muscular tissue presented with dense and diffuse inflammatory infiltrate.</p> <p>Liquid Silicone: Fibrillar connective tissue presented with diffuse inflammatory infiltrate.</p> <p>Tissue necrosis (n = 5); severe granuloma (n = 10); chronic inflammatory reaction (n = 10); lip stiffness, lymphedema, and nodules (n = 6); hyperemia, edema, and pustule formation (n = 1)</p>
Zielke et al., 2008 PMID: 18177399	Germany/Patients with prior treatments of dermal fillers who developed a reaction in one or more of the treated areas	56 (55 women, one man); eight patients were excluded so that 48 remained for further analysis	Not reported	Biodegradable filler, HA, and nonbiodegradable filler, PMMA, polyacrylamide gel, and polyethylene	167 treated areas in 48 patients NLF (n = 67), followed by the lips (n = 27), corners of the mouth (n = 27), and glabella (n = 16)	Not reported	<p>In 10 patients, 24 areas were treated with HA. The areas most often injected were the nasolabial folds (n = 15). In relation to the number of areas treated with HA, the most frequent AEs were swelling (70.8%), erythema (66.7%), and nodule formation (62.5%).</p> <p>In 13 cases, 51 areas were injected with poly(lactic acid); the areas most often treated were the nasolabial folds (n = 18). AEs were nodules (66.7%), itching (25.5%), and pigmentation (17.6%)</p> <p>In six patients, 21 areas were treated with PMMA, the lip vermilion (n = 8) being the area treated most often. The most frequently observed AEs after PMMA injection were nodules (66.7%), erythema (33.3%), and swelling (19.9%)</p>

In 15 patients, 53 areas were treated with HEMA. The areas most often treated were the nasolabial folds ( $n = 22$ ). Nodules (86.8%), erythema (52.8%), and pigmentation (37.7%) occurred most often in relation to the number of treated areas).

In four patients, 18 areas were treated with polyacrylamide; the NLFs ( $n = 6$ ) were treated most often. In relation to the number of treated areas, pigmentation (38.9%), nodules (38.9%), and pain (38.9%) were reported most often after treatment with polyacrylamide.

HA, erythema, swelling, and nodule formation were the relevant adverse events with a median severity greater than 0. HA caused significantly more severe erythema (median, 1) and swelling (median, 2) than the other degradable filler poly(lactic acid) [median for erythema, 0 ( $p = 0.001$ ); median for swelling, 0 ( $p = 0.002$ )]. Poly(lactic acid) showed a median greater than 0 only for nodule formation (median, 2). In the nonbiodegradable group, HEMA caused more severe nodules (median, 3) than PMMA [median, 2 ( $p = 0.03$ )]. Nodule formation in HEMA was accompanied by erythema with a median of 1.

AAPS, American Society of Plastic Surgeons; AAD, American Academy of Dermatology; PMMA, polymethylmethacrylate; PMID, PubMed identification number; USA, United States; NLF, nasolabial fold; AEs, adverse events; RCT, randomized controlled trial; FFA, Facial Fold Assessment; AIDS, acquired immunodeficiency syndrome; N/A, not applicable; HIV, human immunodeficiency virus; HA, hyaluronic acid; 3D, three-dimensional; HEMA, 2-hydroxyethyl methacrylate.

Appendix B. Cont'd

Study	Country/population type	Sample size	Follow-up	Treatment	Injection description	Outcome measures	Adverse events
<b>Silicone Oil Fillers</b>							
<b>Systematic Review: No. of Studies, 1</b>							
Chasan, 2007 PMID: 18090770	USA	N/A	N/A	Silicone oil	N/A	N/A	Majority of complications involved the cheeks, NLFs, and glabella. Range on complication onset is 6 mo–36 yr. Majority of complications observed include granulomas, nodularity, migration, and chronic cellulites.
<b>Uncontrolled Clinical Trial: No. of Studies, 1</b>							
Jones et al, 2004 PMID: 15458523	USA and Canada with stable, well-controlled HIV	Patients 77	N/A	Silikon 1000 or VitreSil 1000 (n = 77)	Cheeks for treatment of facial lipoatrophy 376 total injection among 77 patients	1. Mean number of weeks needed to achieve complete correction, first to last injection 2. Mean number of treatments 3. Mean total volume injected (ml) Based on Carruthers lipoatrophy severity scale	No AEs were noted after any treatment. AEs are defined as posttreatment pain, erythema, or edema lasting longer than 3 days or ecchymosis lasting longer than 2 wk.  The majority of patients experienced mild to moderate discomfort related to multiple needle punctures required for the injection technique.  Most patients experienced mild posttreatment erythema, and occasionally mild tenderness, which in all cases resolved in less than 3 days.
<b>Case Series/Report: No. of Studies, 4</b>							
Jacinto, 2005 PMID: 16416637	Philippines undergoing soft-tissue augmentation	206 cases N/A (191 cases)	N/A	Silicone oil, 0.5–4.6 ml	Intradermal injections for acne and postvaricella scars Deep dermal injections for nasolabial grooves, glabellar frown lines, inframalar creases and depressions, marionette lines, and sleep lines	Clinical improvement graded as excellent, good, fair, or poor	Five had erythematous papules.

Parada et al., 2005 PMID: 16276149	Brazil	11	Not reported	Restylane (HA), MetaCrill (polymethylmethacrylate), Aquamid (polyacrylamide), New-Fill (polylactic acid), Artecoll (polymethylmethacrylate suspended in a collagen solution)	Biopsy specimens fixed in 10% formalin	<p>Restylane: An inflammatory process occurred on the deep reticular dermis, hypodermis, and at the level of the dermal musculature. Periaxial and perivascular lymphomononuclear infiltrates were observed in the superficial and deep dermis, in addition to numerous eosinophils.</p> <p>Aquamid: Inflammatory infiltrates were observed on the deep reticular dermis, hypodermis, and dermal musculature.</p> <p>MetaCrill: A focal or diffuse inflammatory infiltrate at the reticular dermis and hypodermis was observed.</p> <p>New-Fill: A connective tissue presented diffuse inflammatory infiltrate.</p> <p>Artecoll: A connective fibrous and striated muscular tissue presented with dense and diffuse inflammatory infiltrate.</p> <p>Liquid Silicone: Fibrillar connective tissue presented with diffuse inflammatory infiltrate.</p>
---------------------------------------	--------	----	--------------	--	--	--

Appendix B. Cont'd

Study	Country/ population type	Sample size	Follow-up	Treatment	Injection description	Outcome measures	Adverse events
<b>Case Series/Report: No. of Studies, 4</b>							
Poveda et al., 2006 PMID: 16388285	Spain/55-yr-old woman, 72-yr-old woman, 70-yr-old woman, 54-yr-old woman, 43-yr-old woman	5	1 mo	Botulinum toxin type A (Botox) (n = 1) Collagen (n = 1) Dimethylpolysiloxane (silicone) (n = 3)	Injections into the lower and upper lips, nasoglabial area, facial area, cheeks, chin, and buccal mucosa		Discrete trabeculation of the mandibular and submandibular subcutaneous fat related to inflammation changes; intense inflammatory processes affecting almost the entire subcutaneous cellular tissue covering the maxillae and the floor of the mouth and a large part of the buccal mucosa; generalized, bilateral, facial tumefaction; swelling of the lips and cheeks
Requena et al., 2001 PMID: 11391099	Spain/52-yr-old man, 42-yr-old woman, two 38-yr-old women	4	6–14 mo	Artecoll (n = 1) Dermalive (n = 1) Silicone (n = 2)	Artecoll: Nasolabial and forehead folds Dermalive: Forehead and periorcular ridges Silicone: NLFs, cheeks		Artecoll: Erythematous, ribbed, palpable indurations of both nasolabial and forehead folds Dermalive: Erythematous palpable indurations on forehead Silicone: Erythematous palpable indurations of both nasolabial folds, palpable indurations on both cheeks with mild erythema

A-SPS, American Society of Plastic Surgeons; AAD, American Academy of Dermatology; PMID, PubMed Identification number; USA, United States; N/A, not applicable; NLFs, nasolabial folds; AEs, adverse events; HIV, human immunodeficiency virus.



**Other Fillers  
Systematic Review: No. of Studies, 1**

Study	Country/population type	Sample Size	Follow-up	Treatment	Injection description	Outcome measures	Adverse events
Kosowski et al., 2009 PMID: 19483584	USA/Patients who received elective facial cosmetic procedures (e.g., injectable fillers, implants, botulinum toxin treatment) to improve facial appearance	Nine questionnaires to assess facial appearance	N/A	Injectable fillers  Implants  Botulinum toxin	Not reported	1. Rhinoplasty Outcomes Evaluation  2. Glasgow Benefit Inventory, Facial Appearance Sorting Test  3. Facial Lines Treatment Satisfaction Questionnaire  4. Skin Rejuvenation Outcomes Evaluation  5. Facial Lines Outcomes Questionnaire  6. Facelift Outcomes Evaluation  7. Rhinoplasty Outcomes Evaluation  8. Derriford Appearance Scale 59	N/A

Appendix B. Cont'd

Study	Country/population type	Sample size	Follow-up	Treatment	Injection description	Outcome measures	Adverse events
<b>Randomized Controlled Trial: No. of Studies, 1</b>							
Sciafani et al., 2002 PMID: 12437432	USA/Patients with age-related changes in the size and contour of the lip	44 (44)	3, 6, 9, 12 mo	Cymetra (n = 19)  Zyplast (n = 25)	Injection to the upper lip between the orbicularis oris muscle and the overlying mucocutaneous junction of the upper lip	1. Changes in the nasolabial angle  2. Percentage of the total lip accounted for by the exposed red lip in the midline and on the lateral view  3. Visible red upper and lower lip surface areas  4. Anterior projection of the upper and lower lips	No significant local or systemic complications
<b>Uncontrolled Clinical Trial: No. of Studies, 7</b>							
Bjarnsholt et al., 2009 PMID: 19709133	Denmark/Patients with adverse reactions after injection of polyacrylamide gel	8	14 days–2 yr since injection	Aquamid (n = 1) Interfall (n = 1)	Lip (n = 3) Penis (n = 1) Breast (n = 1) Tear trough (n = 1) NLF (n = 1) Cheek (n = 1)	Presence of bacteria in biopsy specimen of lesions from adverse reaction to dermal filler Patient satisfaction	Lesions from dermal filler
de Cassia et al., 2003 PMID: 14612994	Sweden/Patients undergoing facial augmentation	59	2–16 mo (9 mo average)	Aquamid	Injection subcutaneously by retrograde linear tracing injection technique for lip augmentation, cheekbone enlargement, deep NLFs, glabella, chin		Slight redness and temporary swelling immediately after injection subsided within 36 hr.

Han et al., 2006 PMID: 16508353	Korea/Patients undergoing augmentation rhinoplasty	11 (6)	12 mo	Cultured human fibroblasts suspended in Restylane, 0.6–1.0 ml	Injection into the subcutaneous layer of the nasal dorsum	1. Appearance of reconstructed noses, degree and time of resorption, and occurrence of complications	Mild degree of dorsal deviation in one patient
Treacy et al., 2006 PMID: 16792645	USA/HIV patients with facial lipodystrophy	11 (11)	3 and 18 mo	Bio-Alcamid polyacrylamide gel, 15.0–30.0 cm <sup>3</sup>	Polyacrylamide gel injected into the buccal, malar, and temporal areas of the face, superficial to the superficial musculoaponeurotic system	2. Patient satisfaction using a VAS form 1. Quality of life using a modified Beck depression scale	None
von Buelow et al., 2005 PMID: 16163108	Denmark, Germany, Italy, The Netherlands, Spain, Sweden/ Patients undergoing facial augmentation and enhancement of facial contours caused by aging, acne, trauma, or surgery	251 (228)	7, 28 days; 3, 6, 12 mo	Aquamid, 0.2–12.0 ml	Gel administered through the subcutaneous tissue using a thin needle. Injection starts as the needle is withdrawn from the nasolabial and glabella folds, depressed corners of the mouth, perioral wrinkles, lip, chin, cheeks, nose, and vermillion border.	1. Aesthetic outcome as evaluated by the physician at 12 mo 2. Aesthetic outcome as evaluated by the patient at 12 mo	Neutropenia in one patient  Most common AEs included transient swelling, hematoma, redness, pain, or itching (37 cases).
von Buelow et al., 2006 PMID: 16936548	Germany/Patients with mean age of 48 yr, 8% male	251 (101)	24 mo	Aquamid	Nasolabial and glabella folds, depressed corners of the mouth, and perioral wrinkles Facial contouring, lip augmentation Patient satisfaction classified as very satisfied, satisfied, or not satisfied.	Efficacy measured by aesthetic results to be very good, good, bad, or very bad	69 AEs reported in the first year, with 37 cases having a possible to almost certain relationship to the gel injection. 28 transient local tissue reactions Other observations include facial pimples, herpes, neutropenia, eosinophilia, monocytosis, and an.

Appendix B. Cont'd

Study	Country/population type	Sample size	Follow-up	Treatment	Injection description	Outcome measures	Adverse events
Wolters et al., 2009 PMID: 19207323	Germany/General population	251 (81)	36–48 mo	Cross-linked polyacrylamide hydrogel	Various facial contouring locations, not explicitly reported	1. Patient satisfaction  2. Investigator assessment at 36/48 mo	<p>elevation of circulating immunoglobulin</p> <p>One patient developed a hematoma at 28 days after treatment and improved over the next 2 wk. At the 2-yr follow-up, patient reported an intolerance to sunlight exposure at affected sites that revealed a fluid-filled cyst.</p> <p>Another patient reported a transient period of efflorescent eyelids lasting over 2 wk that occurred at 5 mo after treatment</p> <p>Two (2.5%) of nine (11%) AEs reported during the study period were considered to have a possible relationship to the filler injection.</p> <p>Granuloma formation was not detected at any of the follow-up visits.</p>

**Cohort Study: No. of Studies, 4**

Honig, 2008 PMID: 18650737	Germany/Nonrelated 9 HIV-seropositive patients with facial LA	Median, 2 yr	Bio-Alcamid, 7–25 ml in cheek 1–3 ml in NLF 1–2 ml in lip line PAAG	NLF, cheek, lip line	1. Level of satisfaction with surgical outcome	Not reported
Kalantar-Hormozi et al, 2008 PMID: 19083518	Iran/Patients with a history of PAAG injections	2–5 yr	PAAG	542 in various facial locations		Overall rate of complication: 7.7%. 85% occurred <1 yr after injection. In two patients, an abscess appeared in the injection site after more than 3 yr.
Negredo et al, 2006 PMID: 17192148	Spain/HIV-infected patients presenting with antiretroviral-associated facial lipoatrophy for more than 6 mo	96 wk	Analogous fat obtained by liposuction, 50 ml  PLLA, 3–14 ml  Polyacrylamide gel, 4–18 ml	NLFs	Level of facial lipoatrophy from photographic and self-assessment	Abscess formation (5.9%) Displacement of gel (5.3%) All patients complained of pain at the infiltration site during the intervention, and facial edema for 2–3 days, which was always minimal and transient. Ecchymoses were observed in 14% of patients, most cases (13%) being in the polyacrylamide group. Seven of 21 women (33%) included in the polyacrylamide group manifested ecchymoses. All cases resolved spontaneously within 3–5 days. Two patients from the PLLA group (1.4% of the total number of patients included) presented palpable subcutaneous micronodules in the malar area, and two subjects from the polyacrylamide group (1.4% of the total) developed a superficial cutaneous infection, which was easily controlled with an oral antibiotic (the specific type of bacteria was not identified). Only two patients required withdrawal of the substance after polyacrylamide infiltrations because of a hypercorrection or excess of substance in the malar area (one man and one woman).
Reda-Lari, 2008 PMID: 19083517	Kuwait/Patients treated with PAHG for soft-tissue augmentation of the malar area	3 mo–6 yr	PAHG, 1.5–5 ml	Periorbital (tear trough, upper lid), temple, lateral face (gonial angle area), buccal, malar, nasal, nasolabial, lip and chin, or any combination of the above	1. Patient satisfaction	Occurred in 111 patients (8.4%)  Lumps (n = 56) Gel displacement (n = 43) Prolonged pain (n = 5) Infection (n = 3)

Appendix B. Cont'd

Study	Country/population type	Sample size	Follow-up	Treatment	Injection description	Outcome measures	Adverse events
<b>Cross-Sectional Study: No. of Studies, 1</b>							
Zappi et al., PMID: 18086057	USA/Patients treated with LIS for depressed scars on the face	35 samples (25 patients)	1–23 yr	LIS, 0.05–0.2 ml specimen	Not reported	1. Light microscopy examination of skin biopsy	Detected silicone failed to elicit any significant adverse reaction.
<b>Case Series/Report: No. of Studies, 16</b>							
Amin et al., 2004 PMID: 15606826	France/64-yr-old female U.S. citizen	1	5 mo	PAAG	Dermal injections of polyacrylamide gel in cheeks		Erythematous nodules at injection site
Apte et al., 2003 PMID: 12972773	USA/48-yr-old woman	1	2 mo	Cymetra (human cadaver collagen)	Forehead		The patient reported nausea and diaphoresis immediately following the procedure. She then noticed one-sided periorcular pain, and blurred vision in her left eye. Two months later, patient had light perception vision with a marked afferent pupillary defect and large areas of retinal pigment epithelium atrophy and pigment dispersion.
Cheng et al., 2006 PMID: 16547628	China/Women aged 24–45 yr	15	1–7 yr	PAAG	Face, breasts, legs		Body contour disfigurement and implant displacement. The gel lumps could be moved under pressure palpation.
Descamps et al., 2008 PMID: 18446029	France/Patients with chronic hepatitis C treated with interferon alfa	2	Case 1: 5 yr after treatment Case 2: 2 yr after treatment	Case 1: Unknown permanent dermal filler Case 2: Hyaluronic acid	Case 1: Mesolabial and nasolabial folds Case 2: Peribuccal and lion's wrinkles	Not reported	Case 1: Sarcoidal granulomas present in nodules found in the legs, edema in the face with infiltrated masses in the mesolabial and nasolabial folds present with granulomas with vacuolated macrophages, pulmonary function tests reveal decrease in the diffusion capacity of carbon monoxide (58% of normal value) and tuberculin anergy was observed.

Case 2: Edema and infiltrated nodules with purpura in the lips and the injected areas; biopsy confirmed foreign body granuloma; interferon and ribavirin were discontinued but later cirrhosis was diagnosed and interferon and ribavirin were given again; patient developed sicca symptoms and edema and purpuric infiltrated lesions flared up again; biopsy was typical of sarcoidosis; chest CT scan demonstrated pulmonary sarcoidosis with lymphadenopathy and micronodules were confirmed by gallium.

Swelling of the right upper lip that appeared as a firm, partially mobile, nontender, subcutaneous, hard nodule without erythema

2 mo after final treatment, patient presented with freely mobile, nontender subcutaneous nodule 15 mm in diameter on the left midbuccal mucosa.

Not reported

Upper and lower lips during two separate sessions, 2 wk apart in 2002; NLF in August of 2004; NLF and upper lip in August of 2005; upper and lower lip and NLF in February of 2005; lips in October of 2007; lips in November of 2007

Aquamid (polyacrylamide gel) 3.0 ml in 2002, 0.7 ml in August of 2004, 1 ml in August of 2005, 1 ml in February of 2005, 0.8 ml in October of 2007, 1 ml in November of 2007

2 days after final treatment through 10 mo after final treatment

1 (1)

USA, Italy/46-yr-old woman

Goldman, 2009  
PMID: 19207334

Not reported

Of fat: 15 ml in the right zygomatic region  
25 ml in left cheek  
10 ml in buccal rime  
5 ml in the left upper eyelid  
15 ml in the left temporal area  
3 ml in supraorbital area

Polyglactic acid and fat from the abdominal area

Not reported

1

Italy/50-yr-old woman with Romberg syndrome of the left face of 20-yr duration

Grimaldi et al., 2008  
PMID: 18650738

None reported

Appendix B. Cont'd

Study	Country/population type	Sample size	Follow-up	Treatment	Injection description	Outcome measures	Adverse events
Jham et al., PMID: 19138600	Various/General population	56		Various	Upper/lower lip, NLF, cheek	Not reported	Clinical presentation: Single nodule, diffuse swelling, multiple nodules, mass, other
Kanchwala et al., 2005 PMID: 15985788	USA/Patients undergoing facial augmentation	976	3, 6, 9, 12 mo	Autologous fat (n = 697)  Hylaform (n = 52)  Restylane (n = 86)  Radiesse (n = 141)	Nasolabial folds, lips, glabella	1. Type of product used  2. Anatomical region injected  3. Infection rate  4. Touch-up/revision rate and overall longevity	Treatments: Excisional biopsy, steroids (systemic and intralesional), antibiotics, nonsteroidal antiinflammatory drugs, uricosuric agent, immunoregulator  Not reported
Karagozlu et al., 2008 PMID: 18313268	The Netherlands/39-yr-old woman referred by her dentist because of a small mobile submucosal swelling in the left cheek	1	Presented 3 yr since treatment; follow-up of 6 mo after presentation	Aquamid (polyacrylamide gel)	NLF	Not reported	After performing biopsy of the cyst, the histopathologic examination reported that the tissue most likely represented a part of a mucous cyst, but the possibility of mucoepidermoid carcinoma was also considered.
							Histopathologic analysis of both nodules revealed salivary gland tissue with a histiocytic inflammatory infiltrate containing numerous foreign body giant cells that were lining birefringent material.



Kawamura et al., 2006 PMID: 16545711	Brazil/61-yr-old white woman	1	8-14 mo	Single dose of Aquamid (2.5% polyacrylamide)	Single dose of Aquamid injected into the NLF	Fibrous nodules in buccal mucosa caused by foreign body reaction
Lahiri et al., 2007 PMID: 17485056	UK/18 men, 16 women, aged 21-59 yr	12		1.5-110 ml Bio-Alcamid (synthetic polymeric polyacrylamide, enclosed with collagen)	Injections for facial and chest wall deformities	One HIV patient developed an infection on the right temporal area that resulted in a small area of skin breakdown and spontaneous discharge of the injected material.
None; 2008 PMID: 18451755	USA/Healthy women	3	Case 1, 10 days; Case 2, 13 days; Case 3, 14 days	Case 1: Unknown for first treatment; dermal silicone for second treatment  Case 2: Silicone dermal filler, 500 ml each buttock in first treatment and then 400 ml in second treatment  Case 3: Unknown soft-tissue filler	Case 1: Buttocks  Case 2: Buttocks  Case 3: Buttocks	Case 1: Headache and vomiting, purple urine within 30 minutes of receiving injection of dermal silicone in the buttocks; found to be in acute renal failure.  Case 2: Within 1 hr of second treatment, experienced headache and nausea and burgundy urine; found to have acute renal failure; biopsy later revealed severe acute tubular necrosis with case formation.  Case 3: Developed abdominal pain 1 hr after treatment; found to have serum creatine level of 11 mg/dl; renal biopsy later found acute interstitial nephritis with substation numbers of eosinophils.

Appendix B. Cont'd

Study	Country/population type	Sample size	Follow-up	Treatment	Injection description	Outcome measures	Adverse events
Parada et al., 2005 PMID: 16276149	Brazil	11	Not reported	Restylane (hyaluronic acid), MetaCrill (polymethylmethacrylate), Aquamid (polyacrylamide), New-Fill (PLLA), Artecoll (polymethylmethacrylate suspended in a collagen solution).	Biopsy specimens fixed in 10% formalin		Restylane: An inflammatory process occurred on the deep reticular dermis, hypodermis, and at the level of the dermal musculature. Periadnexal and perivascular lymphomononuclear infiltrates were observed in the superficial and deep dermis, in addition to numerous eosinophils.  Aquamid: Inflammatory infiltrates were observed on the deep reticular dermis, hypodermis, and dermal musculature.  MetaCrill: A focal or diffuse inflammatory infiltrate at the reticular dermis and hypodermis was observed.  New-Fill: A connective tissue presented diffuse inflammatory infiltrate.  Artecoll: A connective fibrous and striated muscular tissue presented with dense and diffuse inflammatory infiltrate.  Liquid Silicone: Fibrillar connective tissue presented with diffuse inflammatory infiltrate.
Pitkin et al., 2008 PMID: 19126141	UK/Patients undergoing rhinoplasty augmentation	45	1 wk, 1 mo, and every 3–6 mo after treatment; at time of report, median follow-up time for patients was 13 mo	Permacol (xenograft)	Nasal region	Not reported	One patient (38-yr-old man, external approach rhinoplasty) suffered epistaxis at 1 wk after treatment.  Second patient (42-yr-old man, internal approach rhinoplasty) had implant removed in the first postoperative week.

Rosner et al., 2009 PMID: 19207327	Germany/Patients treated with a methacrylate-based filler who developed a reaction in the same area	34	N/A	Dermalive (hydroxyethylmethacrylate and ethylmethacrylate in fixed combination with hyaluronic acid)	Fillers injected in 95 areas among the 34 patients  Common areas: NLFs (46.3%) Corners of the mouth (17.9%) Glabella (17.9%) Upper lip (12.6%)	Not reported	In the 34 patients, the methacrylate filler was injected into 95 areas. Of these 95 areas, 87 (91.6%) showed a reaction.  The most frequently observed AEs were the development of nodules (n = 85), discoloration (n = 39), erythema or inflammation (n = 32), and swelling (n = 24). Most nodular reactions were rated as severe.
Zielke et al., 2008 PMID: 18177399	Germany/Patients with prior treatments of dermal fillers who developed a reaction in one or more of the swelling treated areas	56 (55 women, one man); eight patients were excluded so that 48 remained for further analysis	Not reported	Biodegradable filler, HA, nonbiodegradable filler, PMMA, PAAAG, and polyethylene	167 treated areas in 48 patients  Nasolabial fold (n = 67), followed by the lips (n = 27), corners of the mouth (n = 27), and glabella (n = 16)	Not reported	Mean time of onset was 23.1 (SD 22.8) mo.  In 10 patients, 24 areas were treated with HA. The areas most often injected were the NLFs (n = 15). In relation to the number of areas treated with HA, the most frequent adverse events were swelling (70.8%), erythema (66.7%), and nodule formation (62.5%).  In 13 cases, 51 areas were injected with PLLA; the areas most often treated were the NLFs (n = 18). AEs included nodules (66.7%), itching (25.5%), and pigmentation (17.6%).  In six patients, 21 areas were treated with PMMA, with the lip vermillion (n = 8) being the area treated most often. The most frequently observed AEs after PMMA injection were nodules (66.7%), erythema (33.3%), and swelling (19.9%).  In 15 patients, 53 areas were treated with HEMA. The areas most often treated were the NLFs (n = 22). Nodules (86.8%), erythema (52.8%), and pigmentation (37.7%) occurred most often in relation to the number of treated areas.

Appendix B. Cont'd

In four patients, 18 areas were treated with polyacrylamide; the NLFs ( $n = 6$ ) were treated most often. In relation to the number of treated areas, pigmentation (38.9%), nodules (38.9%), and pain (38.9%) were reported most often after treatment with polyacrylamide.

HA, erythema, swelling, and nodule formation were the relevant AEs, with a median severity greater than 0. HA caused significantly more severe erythema (median, 1) and swelling (median, 2) than the other degradable filler PLLA [median for erythema, 0 ( $p = 0.001$ ); median for swelling, 0 ( $p = 0.002$ )]. PLLA showed a median greater than 0 only for nodule formation (median 2). In the nonbiodegradable group, HEMA caused more severe nodules (median, 3) than PMMA (median, 2;  $p = 0.03$ ). Nodule formation in HEMA was accompanied by erythema with a median of 1.

---

ASPS, American Society of Plastic Surgeons; AAD, American Academy of Dermatology; PMID, PubMed identification number; USA, United States; N/A, not applicable; NLF, nasolabial fold; HIV, human immunodeficiency virus; VAS, visual analogue scale; AEs, adverse events; LA, lipotrophy; PLLA, poly-L-lactic acid; PAAG, polyacrylamide gel; PAHG, polyacrylamide hydrogel; LIS, liquid injectable silicone; CT, computed tomographic; PMMA, polymethylmethacrylate; HA, hyaluronic acid; HEMA, 2-hydroxyethyl methacrylate.